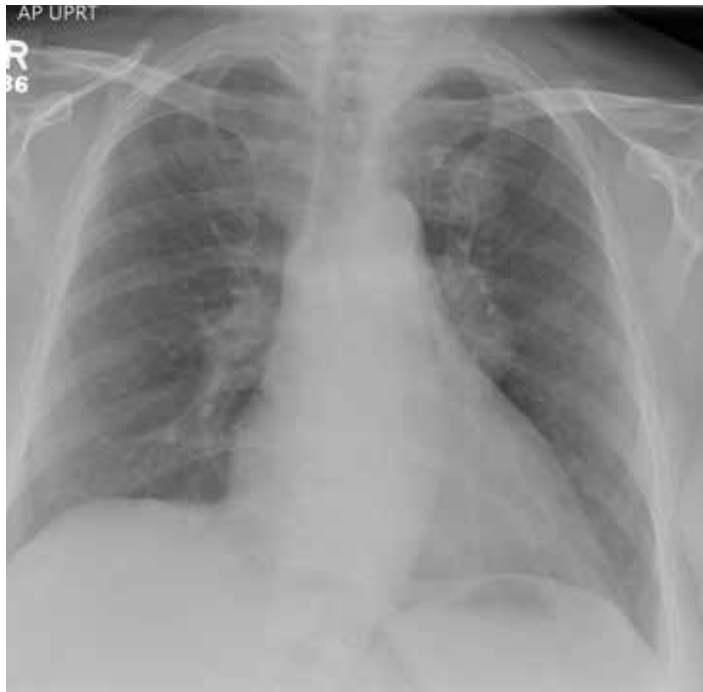


# Woman's Weakness is Worsening

**A** 65-year-old woman is transferred to your facility for evaluation of left-side weakness she has been experiencing for more than two months. She states that it is worsening with time but denies any other symptoms. Outpatient MRI of the brain, obtained by the referring provider, is reported to show a right parietal mass with surrounding edema.

Medical history is significant for hypertension, diabetes, and hypercholesterolemia, which are controlled with medication. The patient reports smoking nearly two packs of cigarettes daily for at least 30 years.

Physical examination reveals normal vital signs and no apparent distress. The patient does have left hemiparesis; her left upper extremity is approximately 4/5 throughout, and her left lower extremity is



approximately 2/5 throughout. The exam is otherwise normal.

As you review her admission lab results, you note that a chest radiograph was obtained (shown). What is your impression?

continued on page 33 >>



**Nandan R. Hichkad, PA-C, MMSc,** practices at the Georgia Neurosurgical Institute in Macon and is a clinical instructor at the Mercer University School of Medicine, Macon.

>> continued from page 13

### ANSWER

The radiograph shows a large, hyperdense mass within the left hilum. A second hyperdense mass is seen within the left upper lobe. Both are concerning for neoplastic processes and warrant further evaluation with contrast-enhanced CT.

Although thorough work-up and biopsy is needed, the presumptive diagnosis is a primary lung mass with likely metastasis to the brain. **CR**

