

# Nevus Spilus: Is the Presence of Hair Associated With an Increased Risk for Melanoma?

Robert Milton Gathings, MD; Raveena Reddy, MD; Ashish C. Bhatia, MD; Robert T. Brodell, MD

## PRACTICE POINTS

- Nevus spilus (NS) appears as a café au lait macule studded with darker brown “moles.”
- Although melanoma has been described in NS, it is rare.
- There is no evidence that hairy NS are predisposed to melanoma.

*Nevus spilus (NS), also known as speckled lentiginous nevus, is characterized by background café au lait–like lentiginous melanocytic hyperplasia speckled with small, 1- to 3-mm, darker foci. Nevus spilus occurs in 1.3% to 2.3% of the adult population worldwide. Reports of melanoma arising within hypertrichotic NS suggest that hypertrichosis may be a marker for the development of melanoma. We present a case of a hypertrichotic NS without melanoma and also provide a review of previously reported cases of hypertrichosis in NS. We believe that NS has a lower risk for malignant degeneration than congenital melanocytic nevi (CMN) of the same size, and it is unlikely that hypertrichosis is a marker for melanoma in NS.*

*Cutis.* 2016;98:171-174.

The term *nevus spilus* (NS), also known as speckled lentiginous nevus, was first used in the 19th century to describe lesions with background café au lait–like lentiginous melanocytic hyperplasia speckled with small, 1- to 3-mm, darker foci. The dark spots reflect lentiginous, junctional, compound, and intradermal nevus cell nests; and more rarely Spitz and blue nevi. Both macular and papular subtypes have been described.<sup>1</sup> This birthmark is quite common, occurring in 1.3% to 2.3% of the adult population worldwide.<sup>2</sup> Hypertrichosis has been described in NS.<sup>3-9</sup> Two subsequent cases of malignant melanoma in hairy NS suggested that lesions may be particularly prone to malignant degeneration.<sup>4,8</sup> We report an additional case of hairy NS that was not associated with melanoma and consider whether dermatologists should warn their patients about this association.

## Case Report

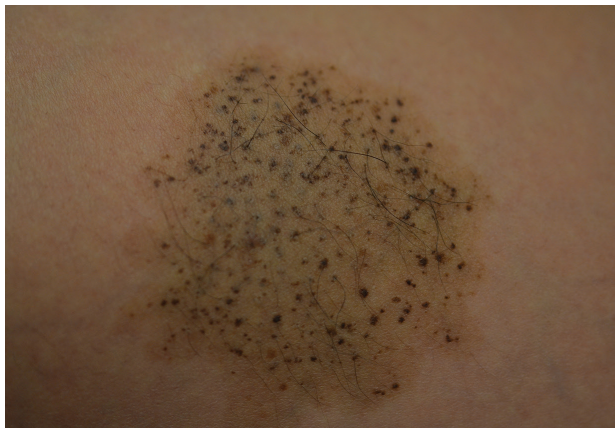A 26-year-old woman presented with a stable 7×8-cm, tan-brown, macular, pigmented birthmark studded with darker 1- to 2-mm, irregular, brown-black and blue, confettilike macules on the left proximal lateral thigh that had been present since birth (Figure 1). Dark terminal hairs were present, arising from both the darker and lighter pigmented areas but not the surrounding normal skin.

---

Drs. Gathings, Reddy, and Brodell are from the Department of Dermatology, University of Mississippi Medical Center, Jackson. Dr. Bhatia is from Northwestern University Feinberg School of Medicine, Chicago, Illinois.

The authors report no conflict of interest.

Correspondence: Robert T. Brodell, MD, Division of Dermatology, University of Mississippi Medical Center, 2500 N State St, Jackson, MS 39216 (rbrodell@umc.edu).

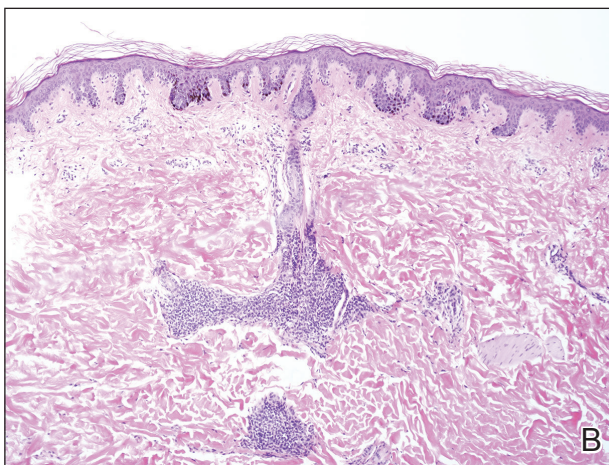
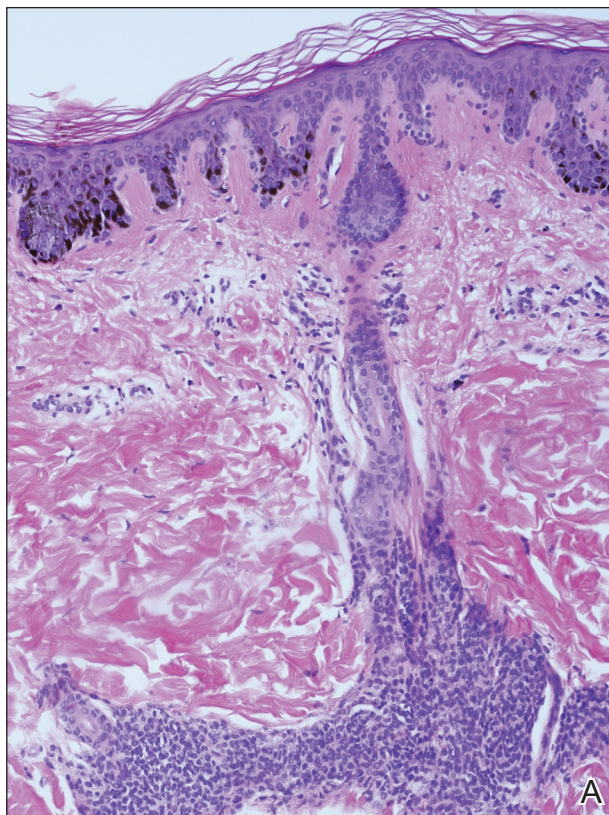


**Figure 1.** A 7×8-cm tan-brown macule studded with darker macules and slightly raised papules on the thigh that was later diagnosed as nevus spilus. Terminal hairs were present.

A 4-mm punch biopsy from one of the dark blue macules demonstrated uniform lentiginous melanocytic hyperplasia and nevus cell nests adjacent to the sweat glands extending into the mid dermis (Figure 2). No clinical evidence of malignant degeneration was present.

### Comment

The risk for melanoma is increased in classic non-speckled congenital nevi and the risk correlates with the size of the lesion and most probably the number of nevus cells in the lesion that increase the risk for a random mutation.<sup>8,10,11</sup> It is likely that NS with or without hair presages a small increased risk for melanoma,<sup>6,9,12</sup> which is not surprising because NS is a subtype of congenital melanocytic nevus (CMN), a condition that is present at birth and results from a proliferation of melanocytes.<sup>6</sup> Nevus spilus, however, appears to have a notably lower risk for malignant degeneration than other classic CMN of the same size. The following support for this hypothesis is offered: First, CMN have nevus cells broadly filling the dermis that extend more deeply into the dermis than NS (Figure 2A).<sup>10</sup> In our estimation, CMN have at least 100 times the number of nevus cells per square centimeter compared to NS. The potential for malignant degeneration of any one melanocyte is greater when more are present. Second, although some NS lesions evolve, classic CMN are universally more proliferative than NS.<sup>10,13</sup> The involved skin in CMN thickens over time with increased numbers of melanocytes and marked overgrowth of adjacent



**Figure 2.** Histopathology revealed lentiginous melanocytic hyperplasia, most prominent at the tips of rete pegs, correlating clinically with the café au lait background coloration, and nevus cells adjacent to the sweat glands extending into the mid dermis, correlating with the blue-black papules (A and B)(H&E, original magnifications ×200 and ×100).

tissue. Melanocytes in a proliferative phase may be more likely to undergo malignant degeneration.<sup>10</sup>

A PubMed search of articles indexed for MEDLINE using the search term *nevus spilus and melanoma* yielded 2 cases<sup>4,8</sup> of melanoma arising among 15 cases of hairy NS in the literature,

## Incidence of Hypertrichosis and Malignant Degeneration in Nevus Spilus Cases

Reference (Year)	No. of Cases Reported	Lesion Size, cm	Melanoma Present?	Comment
Prose et al <sup>3</sup> (1983)	2	Unknown	No	Multiple benign juvenile melanoma
Grinspan et al <sup>4</sup> (1997)	1	Unknown	Yes, size not specified	Hypertrichosis over intradermal nevus within nevus spilus
Langenbach et al <sup>5</sup> (1998)	1	0.3–4	No	Café au lait spots and CMN oriented alongside lines of Blaschko
Schaffer et al <sup>6</sup> (2001)	5	7.0×8.0, 20.0×17.0, 22.0×19.0, 10.0×11.0, and 8.5×6.5	No	All showed histologic features consistent with CMN
Saraswat et al <sup>7</sup> (2003)	1	Several ranging from 0.2–5	No	Associated with phakomatosis pigmentokeratocita and hypophosphatemic vitamin D-resistant rickets
Zeren-Bilgin et al <sup>8</sup> (2006)	1	10×18	Yes, 2×2 cm	
Singh et al <sup>9</sup> (2013)	4	Unknown	No	
Current report	1	7×8	No	

Abbreviation: CMN, congenital melanocytic nevi.

which led to the suggestion that the presence of hair could be associated with an increased risk for malignant degeneration in NS (Table). This apparent high incidence of melanoma most likely reflects referral/publication bias rather than a statistically significant association. In fact, the clinical lesion most clinically similar to hairy NS is Becker nevus, with tan macules demonstrating lentiginous melanocytic hyperplasia associated with numerous coarse terminal hairs. There is no indication that Becker nevi have a considerable premalignant potential, though one case of melanoma arising in a Becker nevus has been reported.<sup>9</sup> There is no evidence to suggest that classic CMN with hypertrichosis has a greater premalignant potential than similar lesions without hypertrichosis.

We noticed the presence of hair in our patient's lesion only after reports in the literature caused us to look for this phenomenon.<sup>9</sup> This occurrence may

actually be quite common. We do not recommend prophylactic excision of NS and believe the risk for malignant degeneration is low in NS with or without hair, though larger NS (>4 cm), especially giant, zosteriform, or segmental lesions, may have a greater risk.<sup>1,6,9,10</sup> It is prudent for physicians to carefully examine NS and sample suspicious foci, especially when patients describe a lesion as changing.

## REFERENCES

1. Vidaurri-de la Cruz H, Happle R. Two distinct types of speckled lentiginous nevi characterized by macular versus papular speckles. *Dermatology*. 2006;212:53-58.
2. Ly L, Christie M, Swain S, et al. Melanoma(s) arising in large segmental speckled lentiginous nevi: a case series. *J Am Acad Dermatol*. 2011;64:1190-1193.
3. Prose NS, Heilman E, Felman YM, et al. Multiple benign juvenile melanoma. *J Am Acad Dermatol*. 1983;9:236-242.

4. Grinspan D, Casala A, Abulafia J, et al. Melanoma on dysplastic nevus spilus. *Int J Dermatol.* 1997; 36:499-502 .
5. Langenbach N, Pfau A, Landthaler M, et al. Naevi spili, café-au-lait spots and melanocytic naevi aggregated alongside Blaschko's lines, with a review of segmental melanocytic lesions. *Acta Derm Venereol.* 1998;78:378-380.
6. Schaffer JV, Orlow SJ, Lazova R, et al. Speckled lentiginous nevus: within the spectrum of congenital melanocytic nevi. *Arch Dermatol.* 2001;137:172-178.
7. Saraswat A, Dogra S, Bansali A, et al. Phakomatosis pigmentokeratolica associated with hypophosphataemic vitamin D-resistant rickets: improvement in phosphate homeostasis after partial laser ablation. *Br J Dermatol.* 2003;148:1074-1076.
8. Zeren-Bilgin i, Gür S, Aydın O, et al. Melanoma arising in a hairy nevus spilus. *Int J Dermatol.* 2006;45:1362-1364.
9. Singh S, Jain N, Khanna N, et al. Hairy nevus spilus: a case series. *Pediatr Dermatol.* 2013;30:100-104.
10. Price HN, Schaffer JV. Congenital melanocytic nevi—when to worry and how to treat: facts and controversies. *Clin Dermatol.* 2010;28:293-302.
11. Alikhan Ali, Ibrahim OA, Eisen DB. Congenital melanocytic nevi: where are we now? *J Am Acad Dermatol.* 2012;67:495.e1-495.e17.
12. Haenssle HA, Kaune KM, Buhl T, et al. Melanoma arising in segmental nevus spilus: detection by sequential digital dermatoscopy. *J Am Acad Dermatol.* 2009;61:337-341.
13. Cohen LM. Nevus spilus: congenital or acquired? *Arch Dermatol.* 2001;137:215-216.