

Acute Localized Exanthematous Pustulosis Caused by Flurbiprofen

Nicola di Meo, MD; Giuseppe Stinco, MD; Pasquale Patrone, MD; Sara Trevisini, MD; Giusto Trevisan, MD

PRACTICE POINTS

- Acute localized exanthematous pustulosis is a form of a pustular drug eruption in which lesions are consistent with acute generalized exanthematous pustulosis but typically localized in a single area.
- The medications most frequently responsible are antibiotics. Flurbiprofen, a propionic acid derivative, could be a rare causative agent of this disease.

To the Editor:

Acute generalized exanthematous pustulosis (AGEP) is an acute skin reaction that is characterized by generalized, nonfollicular, pinhead-sized, sterile pustules on an erythematous and edematous background. The eruption can be accompanied by fever and neutrophilic leukocytosis. Skin symptoms arise quickly (within a few hours), most commonly following drug administration. The medications most frequently responsible are beta-lactam antibiotics, macrolides, calcium channel blockers, and antimalarials. Pustules spontaneously resolve in 15 days and generalized desquamation occurs approximately 2 weeks later. The estimated incidence rate of AGEP is approximately 1 to 5 cases per million per year. Acute localized exanthematous pustulosis (ALEP) is a less common form of AGEP. We report a case of ALEP localized on the face that was caused by flurbiprofen,

a propionic acid derivative from the family of nonsteroidal anti-inflammatory drugs (NSAIDs).

A 40-year-old woman was referred to the dermatology department due to the sudden onset of multiple pustules on the face. One week earlier she started oral flurbiprofen (8.75 mg daily) for a sore throat. After 3 days of therapy, multiple pruritic, erythematous and edematous lesions appeared abruptly on the face with associated multiple small nonfollicular pustules. At presentation the patient was febrile (temperature, 38.2°C) and presented with bilateral ocular edema and superficial small nonfollicular pustules on an erythematous background over the face, scalp, and oral mucosa (Figure 1). The rest of the body was not involved. The patient denied prior adverse reactions to other drugs. The white blood cell count was 15,000/ μL (reference range, 4500–11,000/ μL), with an increased neutrophil count (12,000/ μL [reference range, 1800–7800/ μL]). The erythrocyte sedimentation rate and C-reactive protein level was elevated (erythrocyte sedimentation rate, 53 mm/h [reference range, 0–20 mm/h]; C-reactive protein, 98 mg/dL [reference range, 0–5 mg/dL]). Bacterial and fungal cultures of skin lesions were negative. The results of a viral polymerase chain reaction analysis proved the absence of varicella-zoster virus or herpes simplex virus. Histopathology of a skin biopsy specimen showed subcorneal pustules composed of neutrophils and

Drs. di Meo, Trevisini, and Trevisan are from the Institute of Dermatology and Venereology, University of Trieste, Italy. Drs. Stinco and Patrone are from the Department of Clinical and Experimental Pathology and Medicine, Institute of Dermatology, University of Udine, Italy.

The authors report no conflict of interest.

Correspondence: Nicola di Meo, MD, Institute of Dermatology, University of Trieste, Ospedale "Maggiore," Piazza Ospedale, 1 34100, Trieste, Italy (nickdimeo@libero.it).

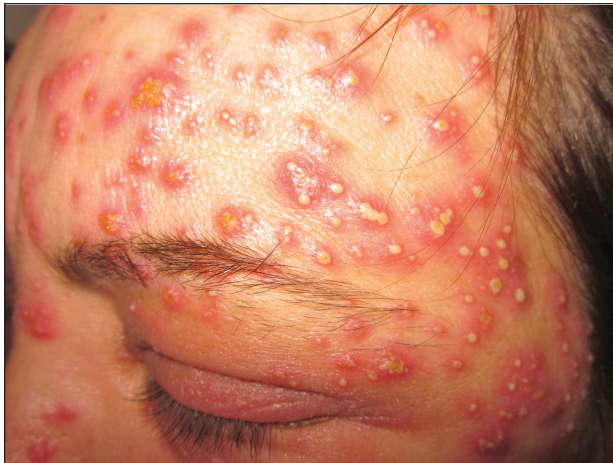

Figure 1. Multiple pruritic, erythematous and edematous lesions with multiple small nonfollicular pustules localized over the face.

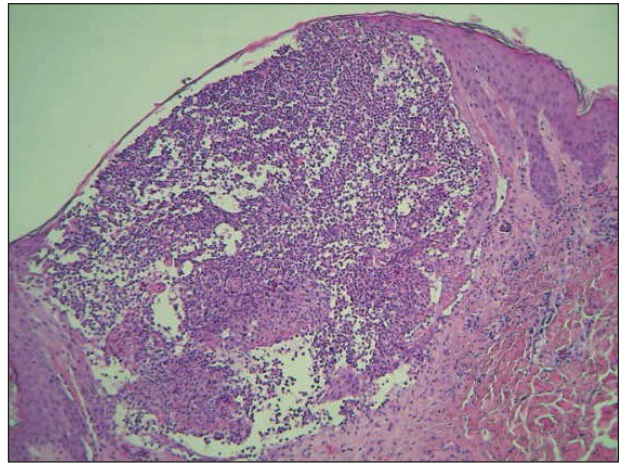


Figure 2. Subcorneal neutrophilic pustules with eosinophils (H&E, original magnification $\times 25$).

eosinophils, epidermal spongiosis, some necrotic keratinocytes, vacuolization of the basal layer, papillary edema, and a perivascular neutrophil and lymphocyte infiltrate (Figure 2). A leukocytoclastic infiltrate within and around the walls of blood vessels at the superficial level of the dermis and red cell extravasation in the epidermis was present. She discontinued use of flurbiprofen and was treated with a systemic corticosteroid (methylprednisolone 0.5 mg/kg daily). The pustules rapidly resolved within 7 days after discontinuation of flurbiprofen and were followed by transient scaling and discrete residual hyperpigmentation.

Acute localized exanthematous pustulosis is a less common form of a pustular drug eruption in which lesions are consistent with AGEP but typically are localized to the face, neck, or chest. The definition of ALEP was introduced by Prange et al¹ to describe a woman who was diagnosed with a localized pustular eruption on the face without a generalized distribution as in AGEP. In the past, this localized eruption was described under different names (eg, localized pustular eruption, localized toxin follicular pustuloderma, nongeneralized acute exanthematic pustulosis).²⁻⁵ According to a PubMed search of articles indexed for MEDLINE using the terms *localized pustulosis*, *localized pustular eruption*, and *localized pustuloderma*, only 16 separate cases of ALEP have been documented since the report by Prange et al.¹ The medications most frequently responsible are antibiotics. Three cases developed following administration of amoxicillin^{2,5,6}; 2 cases of amoxicillin-clavulanic acid^{7,8}; 1 of penicillin¹; 1 of azithromycin⁹; 1 of levofloxacin¹⁰; and 1 of combination of cephalosporin,

sulfamethoxazole-trimethoprim, and vancomycin.¹¹ Other nonantibiotic causative drugs include sulfamethoxazole-trimethoprim,¹² infliximab,¹³ sorafenib,¹⁴ docetaxel,¹⁵ finasteride,¹⁶ ibuprofen,¹⁷ and paracetamol.¹⁸ In reported cases, the lesions are consistent with the characteristics of AGEP both clinically and histopathologically but are localized typically to the face, neck, or chest. In the majority of patients with ALEP, the absence of fever has been observed, but it does not appear distinctive for diagnosis. Our patient represents another case of ALEP with flurbiprofen as the causative drug. The close relationship between the administration of the drug and the development of the pustules, the rapid acute resolution as soon as treatment was interrupted, and the histologic findings all supported the diagnosis of ALEP following administration of flurbiprofen. This NSAID—2-fluoro- α -methyl-(1,1'-biphenyl)-4-acetic acid—is a prostaglandin synthetase inhibitor with anti-inflammatory activity. It is a propionic acid derivative that is similar to ibuprofen, which was once involved in the occurrence of ALEP.¹⁷ In 2009, Rastogi et al¹⁷ reported a case of a 64-year-old woman with an acute outbreak of multiple pustular lesions and underlying erythema affecting the cheeks and chin without fever who had been taking ibuprofen for a toothache. The case is similar to ours and confirms that NSAIDs can induce ALEP. Compared with other NSAIDs, propionic acid derivatives are usually well tolerated and serious adverse reactions rarely have been documented.¹⁹

The physiopathologic mechanisms of ALEP are unknown but likely are similar to AGEP. The demonstration of drug-specific positive patch test

responses and in vitro lymphocyte proliferative responses in patients with a history of AGEp strongly suggests that this adverse cutaneous reaction occurs via a drug-specific T cell-mediated process.²⁰

Further study is needed to understand the etio-pathogenesis of the localized form of the disease and to facilitate a correct diagnosis of this rare disorder.

REFERENCES

1. Prange B, Marini A, Kalke A, et al. Acute localized exanthematous pustulosis (ALEP). *J Dtsch Dermatol Ges.* 2005;3:210-212.
2. Shuttleworth D. A localized, recurrent pustular eruption following amoxicillin administration. *Clin Exp Dermatol.* 1989;14:367-368.
3. De Argila D, Ortiz-Frutos J, Rodriguez-Peralto JL, et al. An atypical case of non-generalized acute exanthematous pustulosis. *Actas Dermosifiliogr.* 1996;87:475-478.
4. Corbalan-Velez R, Peon G, Ara M, et al. Localized toxic follicular pustuloderma. *Int J Dermatol.* 2000;39:209-211.
5. Prieto A, de Barrio M, López-Sáez P, et al. Recurrent localized pustular eruption induced by amoxicillin. *Allergy.* 1997;52:777-778.
6. Vickers JL, Matherne RJ, Mainous EG, et al. Acute localized exanthematous pustulosis: a cutaneous drug reaction in a dental setting. *J Am Dent Assoc.* 2008;139:1200-1203.
7. Betto P, Germi L, Bonoldi E, et al. Acute localized exanthematous pustulosis (ALEP) caused by amoxicillin-clavulanic acid. *Int J Dermatol.* 2008; 47:295-296.
8. Ozkaya-Parlakay A, Azkur D, Kara A, et al. Localized acute generalized exanthematous pustulosis with amoxicillin and clavulanic acid. *Turk J Pediatr.* 2011;53:229-232.
9. Zweegers J, Bovenschen HJ. A woman with skin abnormalities around the mouth [in Dutch]. *Ned Tijdschr Geneesk.* 2012;156:A4613.
10. Corral de la Calle M, Martín Díaz MA, Flores CR, et al. Acute localized exanthematous pustulosis secondary to levofloxacin. *Br J Dermatol.* 2005;152:1076-1077.
11. Sim HS, Seol JE, Chun JS, et al. Acute localized exanthematous pustulosis on the face. *Ann Dermatol.* 2011;23(suppl 3):S3368-S3370.
12. Lee I, Turner M, Lee CC. Acute patchy exanthematous pustulosis caused by sulfamethoxazole-trimethoprim. *J Am Acad Dermatol.* 2010;63:e41-e43.
13. Lee HY, Pelivani N, Beltraminelli H, et al. Amicrobial pustulosis-like rash in a patient with Crohn's disease under anti-TNF-alpha blocker. *Dermatology.* 2011;222:304-310.
14. Liang CP, Yang CS, Shen JL, et al. Sorafenib-induced acute localized exanthematous pustulosis in a patient with hepatocellular carcinoma. *Br J Dermatol.* 2011; 165:443-445.
15. Kim SW, Lee UH, Jang SJ, et al. Acute localized exanthematous pustulosis induced by docetaxel. *J Am Acad Dermatol.* 2010;63:e44-e46.
16. Tresch S, Cozzio A, Kamarashev J, et al. T cell-mediated acute localized exanthematous pustulosis caused by finasteride. *J Allergy Clin Immunol.* 2012;129:589-594.
17. Rastogi S, Modi M, Dhawan V. Acute localized exanthematous pustulosis (ALEP) caused by Ibuprofen. a case report. *Br J Oral Maxillofac Surg.* 2009;47:132-134.
18. Wohl Y, Goldberg I, Sharazi I, et al. A case of paracetamol-induced acute generalized exanthematous pustulosis in a pregnant woman localized in the neck region. *Skinmed.* 2004;3:47-49.
19. Mehra KK, Rupawala AH, Gogtay NJ. Immediate hypersensitivity reaction to a single oral dose of flurbiprofen. *J Postgrad Med.* 2010;56:36-37.
20. Girardi M, Duncan KO, Tigelaar RE, et al. Cross comparison of patch-test and lymphocyte proliferation responses in patients with a history of acute generalized exanthematous pustulosis. *Am J Dermatopathol.* 2005;27:343-346.