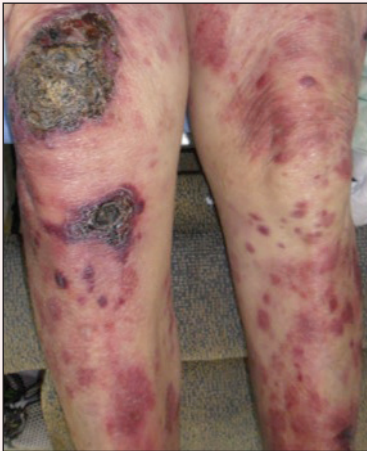

# Diffuse Rash With Associated Ulceration

Antoinette Day, MD; C. Grant Staples, MD; Katherine Fiala, MD



A 72-year-old woman who was admitted for pneumonia and acute hypoxic respiratory failure was seen for an inpatient consultation for a diffuse rash with associated ulceration. She reported a rash of 20 months' duration that began on the legs and then spread to the trunk, arms, head, and neck with minimal pruritus and no pain or photosensitivity. She had been treated with hydroxychloroquine, mycophenolate mofetil, and prednisone without improvement. The patient noted recent ulceration on the rash. Physical examination revealed violaceous patches, plaques, nodules, and tumors with rare ulceration involving the face, trunk, and extremities.

Biopsy showed a diffuse infiltration of the dermis with medium-sized atypical lymphocytes with scant cytoplasm and round to irregular hyperchromatic nuclei with clumped chromatin. Epidermotropism with small collections of atypical lymphocytes also was present within the epidermis.

## What's the diagnosis?

- a. cutaneous coccidioidomycosis
- b. cutaneous histoplasmosis
- c. epidermotropic CD8<sup>+</sup> T-cell lymphoma
- d. pemphigus vegetans
- e. verrucous psoriasis

Dr. Day is from the Department of Internal Medicine, Baylor Medical Center, Dallas, Texas. Drs. Staples and Fiala are from the Department of Dermatology, Baylor Scott & White Health Medical Center, Temple, Texas.

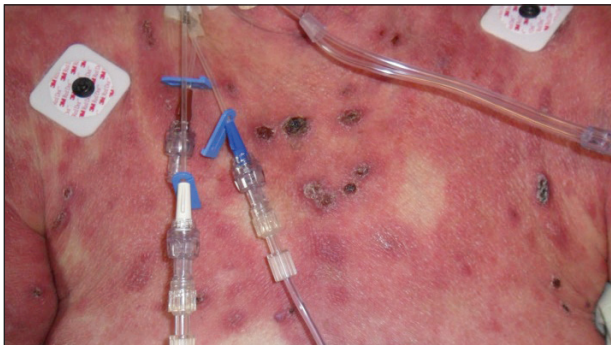
The authors report no conflict of interest.

Correspondence: Katherine Fiala, MD, 409 W Adams Ave, Temple, TX 76501 (Katherine.fiala@bswhealth.org).

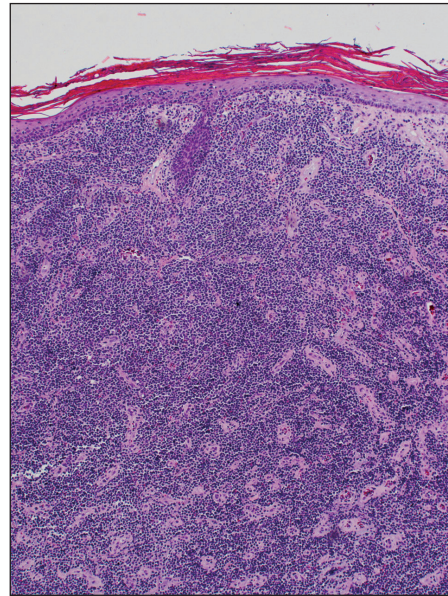
## The Diagnosis: Epidermotropic CD8<sup>+</sup> T-Cell Lymphoma

Epidermotropic CD8<sup>+</sup> T-cell lymphoma is a rare aggressive form of cutaneous T-cell lymphoma (CTCL), accounting for less than 1% of all cases.<sup>1</sup> Since this subtype of CTCL was first described in 1999 by Berti et al,<sup>2</sup> approximately 45 cases have been reported in the literature.<sup>1</sup> It typically is found in elderly men and presents as disseminated or localized papules, patches, plaques, nodules, and tumors, often with central necrosis, ulceration, crusting, and hemorrhage (Figure 1).<sup>1,3</sup> These lesions rapidly progress and can affect any skin site, but acral accentuation and mucosal involvement are common.<sup>4</sup> Due to the rapidly progressive nature of this disease, patients typically present with widespread plaque- and tumor-stage disease.<sup>3</sup> Frequency of systemic spread is high, with metastasis to the central nervous system, lungs, and testes being most common. Lymph nodes typically are spared, helping to differentiate this form of CTCL from classic mycosis fungoides.

Diagnosis of epidermotropic CD8<sup>+</sup> T-cell lymphoma is based on a combination of clinical, histopathologic, and immunohistochemical features. Histopathologic components include epidermotropism, particularly in the basal cell layer, in a pagetoid or linear pattern. A second feature is a dermal infiltrate consisting of a nodular or diffuse pattern of atypical lymphocytes that extend to the subcutaneous fat (Figure 2). All cases of epidermotropic CD8<sup>+</sup> T-cell lymphoma express the CD8<sup>+</sup> phenotype and most have a high Ki-67 proliferation index and are CD3, CD45RA, and/or T-cell intracellular antigen 1 positive.<sup>1</sup>



**Figure 1.** Background erythema of the chest with overlying ulcerated nodules.



**Figure 2.** Diffuse dense dermal infiltrate of lymphocytes filling the entire dermis (H&E, original magnification  $\times 40$ ).

Due to its aggressive nature, epidermotropic CD8<sup>+</sup> T-cell lymphoma has a poor prognosis, with an average 5-year survival rate of 18% and median survival of 22.5 months.<sup>3</sup> Treatment proves difficult as conventional therapies for CD4<sup>+</sup> CTCL have proven ineffective for epidermotropic CD8<sup>+</sup> T-cell lymphoma. Partial response has been seen with bexarotene alone and with total skin electron beam therapy combined with oral retinoids.<sup>1</sup>

### REFERENCES

1. Nofal A, Abdel-Mawla MY, Assaf M, et al. Primary cutaneous aggressive epidermotropic CD8<sup>+</sup> T-cell lymphoma: proposed diagnostic criteria and therapeutic evaluation. *J Am Acad Dermatol.* 2012;67:748-759.
2. Berti E, Tomasini D, Vermeer MH, et al. Primary cutaneous CD8-positive epidermotropic cytotoxic T cell lymphomas. a distinct clinicopathological entity with an aggressive clinical behavior. *Am J Pathol.* 1999; 155:483-492.
3. Gormley RH, Hess SD, Anand D, et al. Primary cutaneous aggressive epidermotropic CD8<sup>+</sup> T-cell lymphoma. *J Am Acad Dermatol.* 2010;62:300-307.
4. Nofal A, Abdel-Mawla MY, Assaf M, et al. Primary cutaneous aggressive epidermotropic CD8<sup>+</sup> T cell lymphoma: a diagnostic and therapeutic challenge. *Int J Dermatol.* 2014;53:76-81.