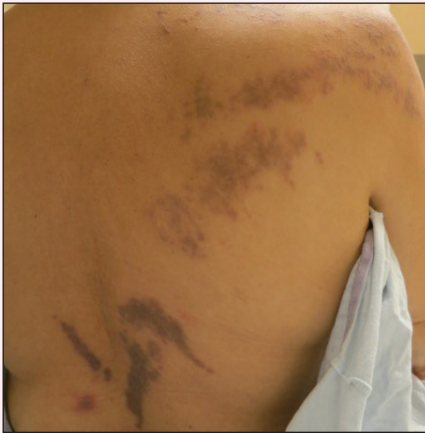

Purple Curvilinear Papules on the Back

Sara A. Berg, MD; Adam I. Rubin, MD; Robert G. Micheletti, MD



A 56-year-old woman with a history of bone marrow transplant presented for evaluation of a nonpruritic rash of 3 months' duration. Physical examination revealed confluent purple-colored and hyperpigmented papules localized to the back and right arm in a curvilinear pattern. Laboratory results were notable for mildly elevated aspartate transaminase and alanine transaminase levels.

What's the diagnosis?

- a. blaschkoid graft-vs-host disease
- b. herpes zoster
- c. incontinentia pigmenti
- d. inflammatory linear verrucous epidermal nevus
- e. lichen striatus

From the Department of Dermatology, Perelman School of Medicine, University of Pennsylvania, Philadelphia. Dr. Micheletti also is from the Department of Medicine.

The authors report no conflict of interest.

Correspondence: Robert G. Micheletti, MD, Departments of Dermatology and Medicine, University of Pennsylvania, Perelman Center for Advanced Medicine, Room 724, 3400 Civic Center Blvd, Philadelphia, PA 19104 (Robert.micheletti@uphs.upenn.edu).

The Diagnosis: Blaschkoid Graft-vs-host Disease

The patient had a history of myelodysplastic syndrome and underwent a bone marrow transplant 1 year prior to presentation. She had acute graft-vs-host disease (GVHD) 6 weeks following the transplant, which resolved with high-dose prednisone followed by UVB phototherapy. Skin biopsy demonstrated lichenoid dermatitis with vacuolar degeneration, dyskeratosis, and prominent pigment incontinence (Figure). Based on these findings and her clinical presentation, a diagnosis of blaschkoid GVHD was made.

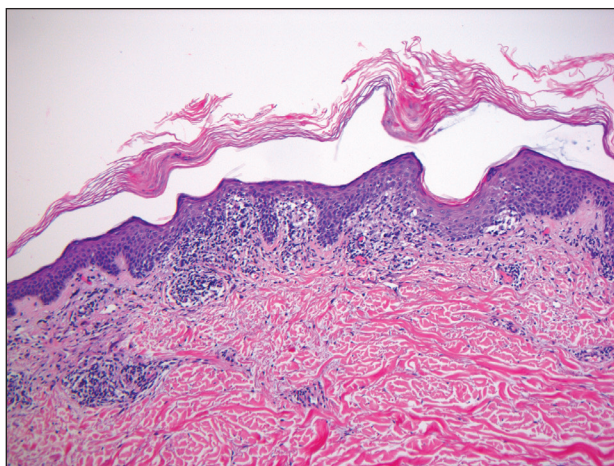
Although acute GVHD is the result of immunocompetent donor T cells recognizing host tissues as foreign and initiating an immune response, the pathophysiology of chronic GVHD is not well understood.^{1,2} Theories for disease pathogenesis in chronic GVHD suggest an underlying autoimmune and/or alloreactive process.^{2,5} The skin often is the first organ affected in acute GVHD, and patients generally present with a pruritic morbilliform eruption that begins on the trunk and spreads to the rest of the body.^{1,2} Cutaneous manifestations of chronic GVHD may be protean. Lesions can resemble systemic sclerosis or morphea, lichen planus, psoriasis, ichthyosis, and many other conditions.²

The differential diagnosis of linear dermatoses includes herpes zoster, contact dermatitis, lichen

striatus (blaschkitis), nevus unius lateris, inflammatory linear verrucous epidermal nevus, and incontinentia pigmenti.^{6,7} Lichen planus–like chronic GVHD occurring in a linear distribution has been described.⁶⁻¹⁴ Distinction between dermatomal and blaschkoid processes is diagnostically important. In the case of GVHD, dermatomal distribution may suggest an association between GVHD and prior herpes simplex virus or varicella-zoster virus infection.^{6,8} Herpesvirus may alter surface antigens of keratinocytes, rendering them targets of donor lymphocytes, and antibodies to viral particles may cross-react with host keratinocyte HLA antigens. It also is possible that dermatomal GVHD may simply be a type of isomorphic response (Köbner phenomenon).⁸

When cutaneous GVHD follows Blaschko lines, other mechanisms appear to be at play.⁹⁻¹⁴ It is plausible that these patients have an underlying genetic mosaicism, perhaps the result of a postzygotic mutation, that results in a daughter cell population that expresses surface antigens different from those of the primary cell population found elsewhere in the skin. Donor lymphocytes may selectively react to this mosaic population, leading to the clinical picture of chronic GVHD oriented along Blaschko lines.^{10,11,13,14}

In conclusion, lichenoid linear GVHD following Blaschko lines is an uncommon presentation of chronic GVHD that highlights the heterogeneity of this disease and should be considered in the appropriate clinical setting.



Histopathology revealed an interface dermatitis, including lymphocytes that approximate the dermoepidermal junction, vacuolar degeneration of basilar keratinocytes, and dyskeratotic keratinocytes, as well as pigment incontinence (H&E, original magnification $\times 100$).

REFERENCES

1. Ferrara JL, Levine JE, Reddy P, et al. Graft-versus-host disease. *Lancet*. 2009;373:1550-1561.
2. Hymes SR, Alousi AM, Cowen EW. Graft-versus-host disease: part I. pathogenesis and clinical manifestations of graft-versus-host disease. *J Am Acad Dermatol*. 2012;66:515.e1-515.e18; quiz 533-534.
3. Patriarca F, Skert C, Sperotto A, et al. The development of autoantibodies after allogeneic stem cell transplantation is related with chronic graft-vs-host disease and immune recovery. *Exp Hematol*. 2006;34:389-396.
4. Shimada M, Onizuka M, Machida S, et al. Association of autoimmune disease-related gene polymorphisms with chronic graft-versus-host disease. *Br J Haematol*. 2007;139:458-463.
5. Zhang C, Todorov I, Zhang Z, et al. Donor CD4+ T and B cells in transplants induce chronic

- graft-versus-host disease with autoimmune manifestations. *Blood*. 2006;107:2993-3001.
6. Freemer CS, Farmer ER, Corio RL, et al. Lichenoid chronic graft-vs-host disease occurring in a dermatomal distribution. *Arch Dermatol*. 1994;130:70-72.
 7. Kikuchi A, Okamoto S, Takahashi S, et al. Linear chronic cutaneous graft-versus-host disease. *J Am Acad Dermatol*. 1997;37:1004-1006.
 8. Sanli H, Anadolu R, Arat M, et al. Dermatomal lichenoid graft-versus-host disease within herpes zoster scars. *Int J Dermatol*. 2003;42:562-564.
 9. Kennedy FE, Hilari H, Ferrer B, et al. Lichenoid chronic graft-vs-host disease following Blaschko lines. *Actas Dermosifiliogr*. 2014;105:89-92.
 10. Lee SW, Kim YC, Lee E, et al. Linear lichenoid graft versus host disease: an unusual configuration following Blaschko's lines. *J Dermatol*. 2006;33:583-584.
 11. Beers B, Kalish RS, Kaye VN, et al. Unilateral linear lichenoid eruption after bone marrow transplantation: an unmasking of tolerance to an abnormal keratinocyte clone? *J Am Acad Dermatol*. 1993;28(5, pt 2):888-892.
 12. Wilson B, Lockman D. Linear lichenoid graft-vs-host disease. *Arch Dermatol*. 1994;130(9):1206-1208.
 13. Reisfeld PL. Lichenoid chronic graft-vs-host disease. *Arch Dermatol*. 1994;130:1207-1208.
 14. Vassallo C, Derlino F, Ripamonti F, et al. Lichenoid cutaneous chronic GvHD following Blaschko lines. *Int J Dermatol*. 2014;53:473-475.