

Actinomycetoma: An Update on Diagnosis and Treatment

Roberto Arenas, MD; Ramón Felipe Fernandez Martinez, MD; Edoardo Torres-Guerrero, MD; Carlos Garcia, MD

PRACTICE POINTS

- Diagnosis of actinomycetoma is based on clinical manifestations including increased swelling and deformity of affected areas, presence of granulation tissue, scars, abscesses, sinus tracts, and a purulent exudate containing microorganisms.
- The feet are the most commonly affected location, followed by the trunk (back and chest), arms, forearms, legs, knees, and thighs.
- Specific diagnosis of actinomycetoma requires clinical examination as well as direct examination of culture and biopsy results.
- Overall, the cure rate for actinomycetoma ranges from 60% to 90%.

Mycetoma is a chronic infection that develops after traumatic inoculation of the skin with either true fungi or aerobic actinomycetes. The resultant infections are known as eumycetoma or actinomycetoma, respectively. Although actinomycetoma is rare in developed countries, migration of patients from endemic areas makes knowledge of this condition crucial for dermatologists worldwide. We present a review of the current concepts in the epidemiology, clinical presentation, diagnosis, and treatment of actinomycetoma.

Cutis. 2017;99:E11-E15.

Mycetoma is a subcutaneous disease that can be caused by aerobic bacteria (actinomycetoma) or fungi (eumycetoma). Diagnosis is based on clinical manifestations, including swelling and deformity of affected areas, as well as the presence of granulation tissue, scars, abscesses, sinus tracts, and a purulent exudate that contains the microorganisms.

The worldwide proportion of mycetomas is 60% actinomycetomas and 40% eumycetomas.¹ The disease is endemic in tropical, subtropical, and temperate regions, predominating between latitudes 30°N and 15°S. Most cases occur in Africa, especially Sudan, Mauritania, and Senegal; India; Yemen; and Pakistan. In the Americas, the countries with the most reported cases are Mexico and Venezuela.¹

Although mycetoma is rare in developed countries, migration of patients from endemic areas makes knowledge of this condition crucial for dermatologists worldwide. We present a review of the current concepts in the epidemiology, clinical presentation, diagnosis, and treatment of actinomycetoma.

Epidemiology

Actinomycetoma is more common in Latin America, with Mexico having the highest incidence. At last count, there were 2631 cases reported in Mexico.²

Drs. Arenas, Fernandez Martinez, and Torres-Guerrero are from the Mycology Section, Department of Dermatology, Dr. Manuel Gea González General Hospital, Mexico City, Mexico. Dr. Garcia is from Dawson Medical Group, Oklahoma City, Oklahoma.

The authors report no conflict of interest

Correspondence: Carlos Garcia, MD, Dawson Medical Group, 4805 S Western Ave, Oklahoma City, OK 73109 (cg.derm@yahoo.com).

The majority of cases of mycetoma in Mexico are actinomycetoma (98%), including *Nocardia* (86%) and *Actinomadura madurae* (10%). Eumycetoma is rare in Mexico, constituting only 2% of cases.² Worldwide, men are affected more commonly than women, which is thought to be related to a higher occupational risk during agricultural labor.

Clinical Features

Mycetoma can affect the skin, subcutaneous tissue, bones, and occasionally the internal organs. It is characterized by swelling, deformation of the affected area, and fistulae that drain serosanguineous or purulent exudates.

In Mexico, 60% of cases of mycetoma affect the lower extremities; the feet are the most commonly affected area, followed by the trunk (back and chest), arms, forearms, legs, knees, and thighs.¹ Other sites include the hands, shoulders, and abdominal wall. The head and neck area are seldom affected.³ Mycetoma lesions grow and disseminate locally. Bone lesions are possible depending on the osteophilic affinity of the etiological agent and on the interactions between the fungus and the host's immune system. In severe advanced cases of mycetoma, the lesions may involve tendons and nerves. Dissemination via blood or lymphatics is extremely rare.⁴

Diagnosis

Diagnosis of actinomycetoma is suspected based on clinical features and confirmed by direct examination of exudates with Lugol iodine or saline solution. On direct microscopy, actinomycetes are recognized by the production of filaments with a width of 0.5 to 1 μm . On hematoxylin and eosin stain, the small grains of *Nocardia* appear eosinophilic with a blue center and pink filaments. On Gram stain, actinomycetoma grains show positive branching filaments. Culture of grains recovered from aspirated material or biopsy specimens provides specific etiologic diagnosis. Cultures should be held for at least 4 weeks. Additionally, there are some enzymatic, molecular, and serologic tests available for diagnosis.⁵⁻⁷ Serologic diagnosis is available in a few centers in Mexico and can be helpful in some cases for diagnosis or follow-up during treatment. Antibodies can be determined via enzyme-linked immunosorbent assay, Western blot analysis, immunodiffusion, or counterimmunoelectrophoresis.⁸

The causative agents of actinomycetoma can be isolated in Sabouraud dextrose agar. Deep wedge biopsies (or puncture aspiration) are useful in observing the diagnostic grains, which can be identified adequately with Gram stain. Grains usually are

surrounded and/or infiltrated by neutrophils. The size, form, and color of grains can identify the causative agent.¹ The granules of *Nocardia* are small (80–130 μm) and reniform or wormlike, with club structures in their periphery (Figure 1). *Actinomadura madurae* is characterized by large, white-yellow granules that can be seen with the naked eye (1–3 mm). On microscopic examination with hematoxylin and eosin stain, these grains are purple and exhibit peripheral pink pseudofilaments (Figure 2).² The grains of *Actinomadura pelletieri* are large (1–3 mm) and red or violaceous. They fragment or break easily, giving the appearance of a broken dish (Figure 3). *Streptomyces somaliensis* forms round grains approximately 0.5 to 1 cm in diameter. These grains stain poorly and are extremely hard. Cutting the grains

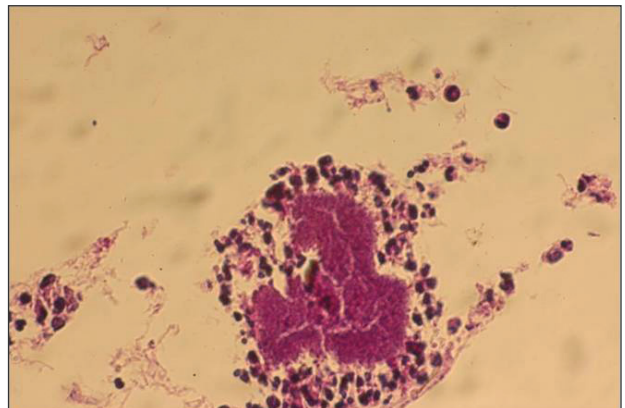


Figure 1. Reniform grain with peripheral club structures in an actinomycetoma caused by *Nocardia brasiliensis* (H&E, original magnification $\times 40$).

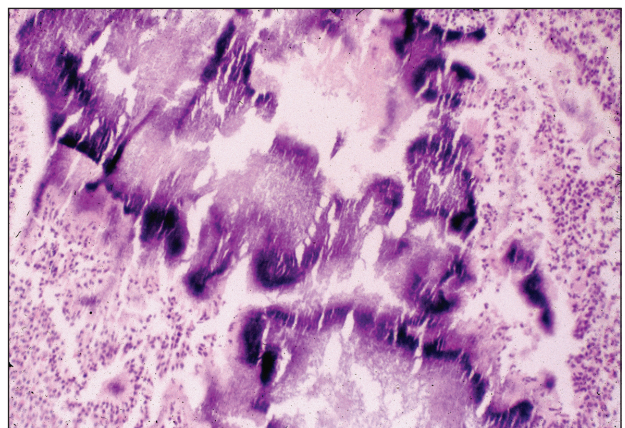


Figure 2. Purple grain with pink pseudofilaments in an actinomycetoma caused by *Actinomadura madurae* (H&E, original magnification $\times 10$).

during processing results in striation, giving them the appearance of a potato chip (Figure 4).²

Treatment of Actinomycetoma

Precise identification of the etiologic agent is essential to provide effective treatment of actinomycetoma. Without treatment, or in resistant cases, progressive osseous and visceral involvement is inevitable.⁹ Actinomycetoma without osseous involvement usually responds well to medical treatment.

The treatment of choice for actinomycetoma involving *Nocardia brasiliensis* is a combination of dapsone 100 to 200 mg once daily and trimethoprim-sulfamethoxazole (TMP-SMX) 80/400 to 160/800 mg once daily for 2 to 3 years.¹⁰ Other treatments have included the following: (1) amikacin

15 mg/kg or 500 mg intramuscularly twice daily for 3 weeks plus dapsone 100 to 200 mg once daily plus TMP-SMX 80/400 to 160/800 mg daily for 2 to 3 years (amikacin, however, is expensive and potentially toxic [nephrotoxicity and ototoxicity] and therefore is used only in resistant cases); (2) dapsone 100 to 200 mg once daily or TMP-SMX 80/400 to 160/800 mg daily for 2 to 3 years plus intramuscular kanamycin 15 mg/kg once daily for 2 weeks at the beginning of treatment, alternating with rest periods to reduce the risk for nephrotoxicity and ototoxicity¹⁰; (3) dapsone 1.5 mg/kg orally twice daily plus phosphomycin 500 mg once daily; (4) dapsone 1.5 mg/kg orally twice daily plus streptomycin 1 g once daily (14 mg/kg/d) for 1 month, then the same dose every other day for 1 to 2 months monitoring for ototoxicity; and (5) TMP-SMX 80/400 to 160/800 mg once daily for 2 to 3 years or rifampicin (15–20 mg/kg/d) plus streptomycin 1 g once daily (14 mg/kg/d) for 1 month at the beginning of treatment, then the same dose every other day for 2 to 3 months until a total dose of 60 g is administered, monitoring for ototoxicity.¹¹ Audiometric tests and

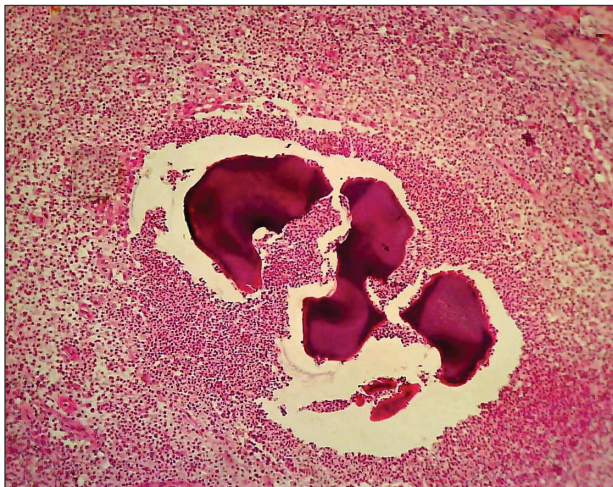

Figure 3. Red violaceous grain with appearance of a broken dish in an actinomycetoma caused by *Actinomadura pelletieri* (H&E, original magnification $\times 10$).

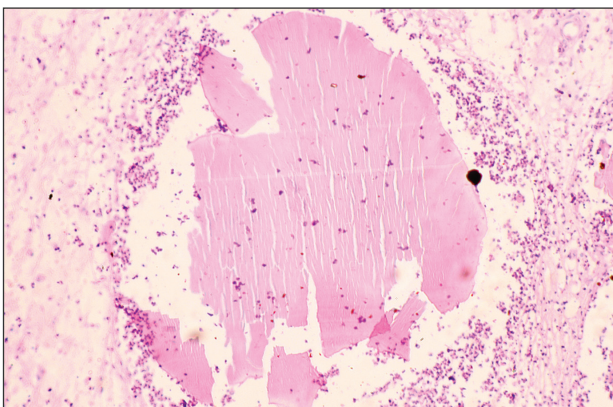


Figure 4. Poorly stained hard grain with appearance of a potato chip in an actinomycetoma caused by *Streptomyces somaliensis* (H&E, original magnification $\times 10$).

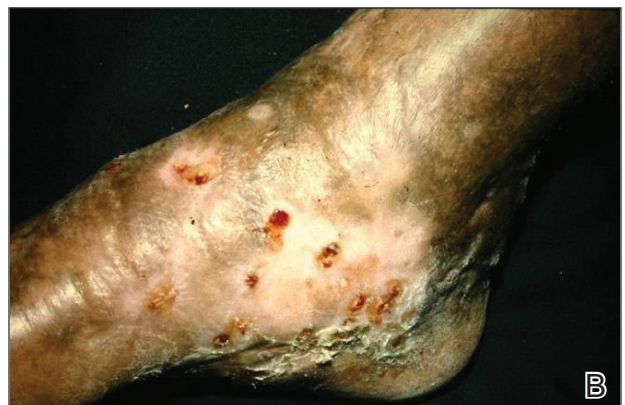
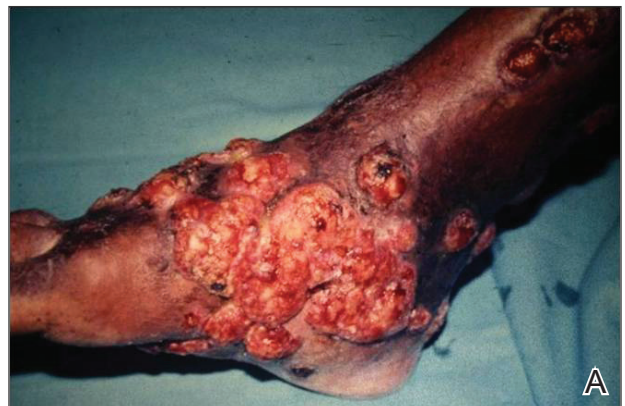
Figure 5. An actinomycetoma on the right foot before (A) and 1 year after treatment with streptomycin (B).

creatinine levels must be performed every 5 weeks during the treatment to monitor toxicity.¹⁰

The best results for infections with *A pelletieri*, *A madurae*, and *S somaliensis* have been with streptomycin (1 g once daily in adults; 20 mg/kg once daily in children) until a total dose of 50 g is reached in combination with TMP-SMX or dapsone¹² (Figure 5). Alternatives for *A madurae* infections include streptomycin plus oral clofazimine (100 mg once daily), oral rifampicin (300 mg twice daily), oral tetracycline (1 g once daily), oral isoniazid (300–600 mg once daily), or oral minocycline (100 mg twice daily; also effective for *A pelletieri*).

More recently, other drugs have been used such as carbapenems (eg, imipenem, meropenem), which have wide-spectrum efficacy and are resistant to β -lactamases. Patients should be hospitalized to receive intravenous therapy with imipenem.² Carbapenems are effective against gram-positive and gram-negative as well as *Nocardia* species.^{13,14} Mycetoma that is resistant, severe, or has visceral involvement can be treated with a combination of amikacin and imipenem.^{15,16} Meropenem is a similar drug that is available as an oral formulation. Both imipenem and meropenem are recommended in cases with bone involvement.^{17,18} Alternatives for resistant cases include amoxicillin–clavulanic acid 500/125 mg orally 3 times daily for 3 to 6 months or intravenous cefotaxime 1 g every 8 hours plus intramuscular amikacin 500 mg twice daily plus oral levamisole 300 mg once weekly for 4 weeks.^{19,23}

For resistant cases associated with *Nocardia* species, clindamycin plus quinolones (eg, ciprofloxacin, moxifloxacin, garenoxacin) at a dose of 25 mg/kg once daily for at least 3 months has been suggested in *in vivo* studies.²³

Overall, the cure rate for actinomycetoma treated with any of the prior therapies ranges from 60% to 90%. Treatment must be modified or stopped if there is clinical or laboratory evidence of drug toxicity.^{13,24} Surgical treatment of actinomycetoma is contraindicated, as it may cause hematogenous dissemination.

Prognosis

Actinomycetomas of a few months' duration and without bone involvement respond well to therapy. If no therapy is provided or if there is resistance, the functional and cosmetic prognosis is poor, mainly for the feet. There is a risk for spine involvement with mycetoma on the back and posterior head. Thoracic lesions may penetrate into the lungs. The muscular fascia impedes the penetration of abdominal lesions, but the inguinal canals can offer a path for intra-abdominal dissemination.⁴ Advanced cases lead to a poor general condition of patients, difficulty

in using affected extremities, and in extreme cases even death.

The criteria used to guide the discontinuation of initial therapy for any mycetoma include a decrease in the volume of the lesion, closure of fistulae, 3 consecutive negative monthly cultures, imaging studies showing bone regeneration, lack of echoes and cavities on echography, and absence of grains on examination of fine-needle aspirates.¹¹ After the initial treatment protocol is finished, most experts recommend continuing treatment with dapsone 100 to 300 mg once daily for several years to prevent recurrence.¹²

Prevention

Mycetoma is a disease associated with poverty. It could be prevented by improving living conditions and by regular use of shoes in rural populations.²

Conclusion

Mycetoma is a chronic infection that develops after traumatic inoculation of the skin with either true fungi or aerobic actinomycetes. The resultant infections are known as eumycetoma or actinomycetoma, respectively. The etiologic agents can be found in the so-called grains. Black grains suggest a fungal infection, minute white grains suggest *Nocardia*, and red grains are due to *A pelletieri*. Larger white grains or yellow-white grains may be fungal or actinomycotic in origin.

Specific diagnosis requires direct examination, culture, and biopsy. The treatment of choice for actinomycetoma by *N brasiliensis* is a combination of dapsone 100 to 200 mg once daily and TMP-SMX 80/400 to 160/800 mg once daily for 2 to 3 years. Other effective treatments include aminoglycosides (eg, amikacin, streptomycin) and quinolones. More recently, some other agents have been used such as carbapenems and natural products of *Streptomyces cattleya* (imipenem), which have wide-spectrum efficacy and are resistant to β -lactamases.

REFERENCES

1. Welsh O, Vera-Cabrera L, Welsh E, et al. Actinomycetoma and advances in its treatment. *Clin Dermatol*. 2012;30:372-381.
2. Arenas R. *Micología Médica Ilustrada*. 4th ed. Mexico City, Mexico: McGraw-Hill Interamericana; 2011:125-146.
3. McGinnis MR. Mycetoma. *Dermatol Clin*. 1996;14:97-104.
4. Fahal AH. *Mycetoma: Clinico-pathological Monograph*. Khartoum, Sudan: University of Khartoum Press; 2006:20-23, 81-82.
5. Estrada-Chavez GE, Vega-Memije ME, Arenas R, et al. Eumycotic mycetoma caused by *Madurella mycetomatis* successfully treated with antifungals, surgery, and topical negative pressure therapy. *Int J Dermatol*. 2009; 48:401-403.

6. Chávez G, Arenas R, Pérez-Polito A, et al. Eumycetoma due to *Madurella mycetomatis*. report of six cases. *Rev Iberoam Micol*. 1998;15:90-93.
7. Vasquez del Mercado E, Arenas R, Moreno G. Sequelae and long-term consequences of systemic and subcutaneous mycoses. In: Fratamico PM, Smith JL, Brogden KA, eds. *Sequelae and Long-term Consequences of Infectious Diseases*. Washington, DC: ASM Press; 2009:415-420.
8. Mancini N, Ossi CM, Perotti M, et al. Molecular mycological diagnosis and correct antimycotic treatments. *J Clin Microbiol*. 2005;43:3584-3585.
9. Arenas R, Lavalle P. Micetoma (madura foot). In: Arenas R, Estrada R, eds. *Tropical Dermatology*. Austin, TX: Landes Bioscience; 2001:51-61.
10. Welsh O, Saucedo E, González J, et al. Amikacin alone and in combination with trimethoprim-sulfamethoxazole in the treatment of actinomycetoma. *J Am Acad Dermatol*. 1987;17:443-448.
11. Fahal AH. Mycetoma: clinico-pathological monograph. In: Fahal AH. *Evidence Based Guidelines for the Management of Mycetoma Patients*. Khartoum, Sudan: University of Khartoum Press; 2002:5-15.
12. Welsh O, Salinas MC, Rodríguez MA. Treatment of eumycetoma and actinomycetoma. *Curr Top Med Mycol*. 1995;6:47-71.
13. Valle ACF, Welsh O, Vera-Cabrera L. Subcutaneous mycoses—mycetoma. In: Tyring SK, Lupi O, Hengge UR, eds. *Tropical Dermatology*. Philadelphia, PA: Elsevier Churchill Livingstone; 2006:197-200.
14. Fuentes A, Arenas R, Reyes M, et al. Actinomycetoma por *Nocardia* sp. Informe de cinco casos tratados con imipenem solo o combinado con amikacina. *Gac Med Mex*. 2006;142:247-252.
15. Gombert ME, Aulicino TM, DuBouchet L, et al. Therapy of experimental cerebral nocardiosis with imipenem, amikacin, trimethoprim-sulfamethoxazole, and minocyclina. *Antimicrob Agents Chemother*. 1986;30:270-273.
16. Calandra GB, Ricci FM, Wang C, et al. Safety and tolerance comparison of imipenem-cilastatin to cephalotin and cefazolin. *J Antimicrob Chemother*. 1983;12:125-131.
17. Ameen M, Arenas R, Vasquez del Mercado E, et al. Efficacy of imipenem therapy for *Nocardia* actinomycetomas refractory to sulfonamides. *J Am Acad Dermatol*. 2010;62:239-246.
18. Ameen M, Vargas F, Vasquez del Mercado E, et al. Successful treatment of *Nocardia* actinomycetoma with meropenem and amikacin combination therapy. *Int J Dermatol*. 2011;50:443-445.
19. Ameen M, Arenas R. Emerging therapeutic regimes for the management of mycetomas. *Expert Opin Pharmacother*. 2008;9:2077-2085.
20. Vera-Cabrera L, Daw-Garza A, Said-Fernández S, et al. Therapeutic effect of a novel oxazolidinone, DA-7867 in BALB/c mice infected with *Nocardia brasiliensis*. *PloS Negl Trop Dis*. 2008;2:e289.
21. Gómez A, Saúl A, Bonifaz A. Amoxicillin and clavulanic acid in the treatment of actinomycetoma. *Int J Dermatol*. 1993;32:218-220.
22. Méndez-Tovar L, Serrano-Jaen L, Almeida-Arvizu VM. Cefotaxima mas amikacina asociadas a inmunomodulación en el tratamiento de actinomycetoma resistente a tratamiento convencional. *Gac Med Mex*. 1999;135:517-521.
23. Chacon-Moreno BE, Welsh O, Cavazos-Rocha N, et al. Efficacy of ciprofloxacin and moxifloxacin against *Nocardia brasiliensis* in vitro in an experimental model of actinomycetoma in BALB/c mice. *Antimicrob Agents Chemother*. 2009;53:295-297.
24. Welsh O. Treatment of actinomycetoma. *Arch Med Res*. 1993;24:413-415.