

# Misdiagnosed Crusted Scabies in an AIDS Patient Leads to Hyperinfestation

Niloofer Yari, MD; C. Helen Malone, MD; Antonio Rivas, MD

## PRACTICE POINTS

- Keep scabies in mind, especially in immunocompromised patients or populations in overcrowded areas.
- Treatment consists of isolating the patient, starting topical permethrin and oral ivermectin (in severe cases), washing all linens, and prophylactically treating contacts.

*Crusted scabies is a severe, highly contagious form of classic scabies caused by the mite *Sarcoptes scabiei var hominis*. Crusted scabies is more common in immunosuppressed populations and overcrowded environments. In this condition, the host's immune system is overwhelmed and unable to defend against the mites on the skin, resulting in hyperinfestation of the host. Diagnosis can be challenging because the condition resembles other common skin conditions, such as plaque psoriasis. Furthermore, delayed diagnosis and inappropriate treatment can lead to worsening of the condition. We report a case of crusted scabies that was initially misdiagnosed in a 34-year-old incarcerated man with multidrug-resistant human immunodeficiency virus/AIDS. The patient had a complicated but complete recovery after treatment with permethrin and ivermectin was instituted.*

*Cutis.* 2017;99:202-204.

## Case Report

A recently incarcerated 34-year-old man with an 11-year history of multidrug-resistant human

immunodeficiency virus/AIDS (CD4 count, 121 cells/mm<sup>3</sup>; viral load, 49,625 particles/mm<sup>3</sup> one week prior to presentation) was admitted to the hospital for an intensely pruritic, hyperkeratotic, scaly rash involving the entire body. The rash first appeared on the feet approximately 1 year prior to admission. At that time the patient was given oral fluconazole and a steroid cream with near resolution of the rash. He was then transferred multiple times to different units with subsequent discontinuation of the medications. The rash flared and progressed to involve the knees. He was restarted on the fluconazole and steroid cream and placed in isolation by medical personnel at the prison 6 months prior to presentation. The rash continued to spread, and he was given a working diagnosis of plaque-type psoriasis by several providers after several months of nonresponse to treatment. Additional attempts at treatment at outside facilities included oral fluconazole, trimethoprim-sulfamethoxazole, and other antibiotics. He was referred to dermatology at our institution but missed the appointment and was admitted to the hospital before the appointment could be rescheduled.

On admission to the hospital, he denied similar lesions in close contacts. On review of systems he had subjective fevers and chills, decreased appetite, nausea without vomiting, dysphagia to solids, epigastric pain, and 70-lb weight loss over the last 6 months. Facial involvement of the rash impaired the ability to open the mouth, speak, and eat. He had no known drug allergies. His only medications at the time of admission were nortriptyline, trimethoprim-sulfamethoxazole, and oral combination

---

Dr. Yari was from and Drs. Malone and Rivas are from the University of Texas Medical Branch, Galveston. Dr. Yari was from the Department of Internal Medicine, Dr. Malone is from the Department of Dermatology, and Dr. Rivas is from the Department of Internal Medicine. Dr. Yari currently is from the Department of Neurology, Baylor Scott & White Health, Texas A&M University Health Center, Temple.

The authors report no conflict of interest.

Correspondence: Niloofer Yari, MD, Department of Neurology, Baylor Scott & White Health, 2401 S 31st, MS-01-E524, Temple, TX 76508 (niloofer.yari@bswhealth.org).

elvitegravir-cobicistat-emtricitabine-tenofovir for human immunodeficiency virus treatment.

On physical examination he was cachectic, shivering, and foul smelling. He was afebrile, slightly tachycardic (112 beats per minute), and hypertensive (144/83 mm Hg) with a respiratory rate of 18 breaths per minute. His height was 1.83 m (6 ft) and weight was 48.5 kg (107 lb) with a body mass index of 14.5. Extensive erythematous, hyperkeratotic, crusted, and fissured plaques covered the entire body including the face, hands, and feet. The tongue was covered with bilateral white-colored plaques, and he had patches of alopecia, excoriations, and scales on the scalp. The elbows were fixed in a flexed position and he had decreased range of motion in the wrists and fingers due to the severe hyperkeratosis (Figure 1A). Hyperkeratosis also was prominent on the knees and feet with associated burrows (Figure 2A). He had foot drop on the left.

The differential diagnosis included a drug eruption; fungal or parasite infestation, such as crusted scabies; psoriasis; or cutaneous lymphoma. Laboratory studies were difficult to obtain, as there were limited areas suitable for vascular access. Blood work showed leukocytosis ( $18.9 \times 10^9$  cells/L [reference range,  $4.8\text{--}10.8 \times 10^9$  cells/L] with 13.3% eosinophils (reference range, 1%–6%). This eosinophilia narrowed the likely diagnoses to a drug eruption or parasite infection.

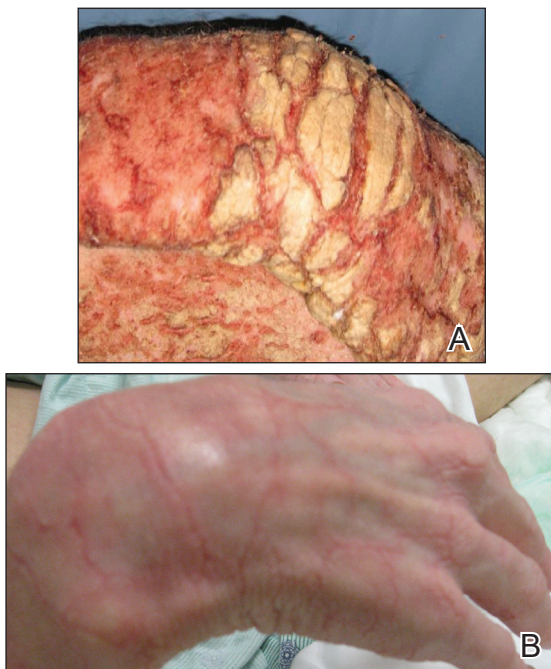The dermatology service was consulted. A mineral oil preparation was performed and showed numerous

mites and feces consistent with a diagnosis of crusted scabies (Figure 3). The patient was started on a regimen of permethrin cream 5% applied to the entire body, except the face, which was left on overnight and washed off. This regimen was repeated daily for 1 week, then twice weekly until the rash resolved after a total of 3 weeks. Due to the severity of his condition, immunocompromised status, and concern for superinfection, oral ivermectin 200  $\mu\text{g}/\text{kg}$  once daily was added on days 1, 2, 8, 9, 15, 22, and 29.<sup>1</sup>

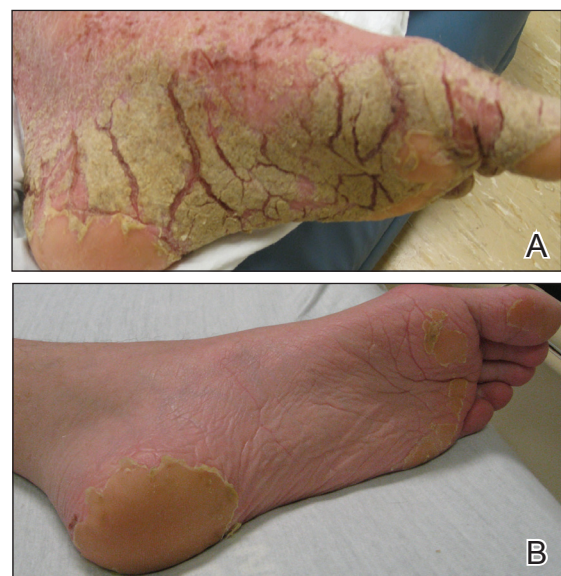Our patient's hospital course was further complicated by symptomatic hypoglycemia, altered mental status, and superimposed methicillin-resistant *Staphylococcus aureus* bacteremia, as well as *Pseudomonas aeruginosa* bacteremia, pneumonia, and coffee ground emesis. He was transferred to the intensive care unit but fortunately did not require intubation. His overall condition, mental status, and rash gradually improved. Three weeks after admission he only had a few residual lesions on the feet with clearing elsewhere (Figures 1B and 2B). He was discharged with a skin moisturizer and was referred for physical and occupational therapy. On follow-up clinic visits at 3 and 6 months, he had recovered well with general improvement in his condition.

### Comment

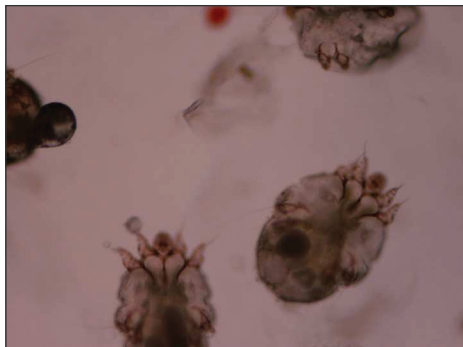
Classic (noncrusted) scabies is common worldwide, with an estimated 300 million cases per year. It is caused by the mite *Sarcoptes scabiei* var *hominis*, and transmission occurs by direct skin-to-skin contact or less commonly by fomites (eg, linens, bedsheets) and



**Figure 1.** Hyperkeratotic lesions on the right hand before (A) and after 3 weeks of treatment with permethrin cream 5% and oral ivermectin (B).



**Figure 2.** Hyperkeratosis and visible burrows on the left foot before (A) and after 3 weeks of treatment with permethrin cream 5% and oral ivermectin (B).



**Figure 3.** Mineral oil preparation showed scabies mites. The diagnosis was made after the mites were visualized under the microscope (original magnification  $\times 400$ ). Photograph provided by Matthew Petit, DO (Galveston, Texas).

therefore is common in overcrowded environments.<sup>2</sup> Crusted scabies is a severe, highly contagious form of the disease in which the host's immune system is overwhelmed and unable to defend against mites on the skin, resulting in hyperinfestation of the host. The mites use secretions to dissolve the epidermis and burrow through the skin, leaving feces in their tracks.<sup>3</sup> Interestingly, the native aboriginal populations of Australia have a high incidence of crusted scabies even though they show no signs of immunosuppression. The reason remains unclear but may be due to a skewed T-cell response.<sup>4</sup> Various mechanisms have been described for the symptoms of scabies, and it is believed that there is a hypersensitivity reaction to the mites and the feces. Increased IL-17 production by skin T cells may be responsible.<sup>5</sup>

**Clinical Features**—Crusted scabies is characterized by severe hyperkeratosis and plaques with desquamation and erythroderma that is worse in the acral regions and large joints, such as the elbows and the knees, as seen in our patient. Because of the deep burrows, patients are predisposed to secondary superinfections by bacteria. In our case, the patient had methicillin-resistant *S aureus* bacteremia, which persisted for some time despite treatment with intravenous antibiotics.

**Diagnosis**—Because scabies can imitate different conditions, it can be difficult to diagnose. Misdiagnosis of psoriasis in our patient led to ineffective treatment and subsequent worsening of his condition. Burrows are pathognomonic for scabies, though in severe cases, the burrows may be concealed by extreme hyperkeratosis. Diagnosis is confirmed by mineral oil preparation from the plaques showing numerous scabies mites and feces.

**Treatment**—It is important to control the spread of scabies, as it is highly contagious, and if the living environment is not properly cleaned, the patient

can be reinfected. All clothing, bedsheets, and linens in the household must be washed in hot water and dried in a hot dryer, and nonwashable items should be placed in a closed plastic bag for 72 hours. All contacts also should be treated with 1 application of permethrin cream to the entire body including the head and neck, left on overnight, and washed off with warm water.<sup>1</sup> The washing also helps remove some of the skin crusts. Patients should be educated that pruritus and burning may initially worsen with permethrin treatment due to the body's reaction to the parasite.<sup>1,2</sup> In addition, keratolytic agents such as topical urea or salicylic acid can be used as an adjuvant therapy to improve the efficacy of permethrin.

Permethrin is effective against both mites and eggs and works by inhibiting sodium channels, resulting in nerve signal conduction block and subsequent paralysis. Ivermectin is thought to act on glutamate-gated chloride channels, which are present in invertebrates but absent in vertebrates, causing hyperpolarization and paralysis of the adult mite.<sup>1,6</sup>

## Conclusion

Crusted scabies is a highly contagious and intensely pruritic condition. Scabies can mimic other conditions, such as psoriasis or severe dermatitis, so it is important to keep this diagnosis in mind, especially in immunocompromised patients or populations in overcrowded areas (eg, those who are incarcerated or in nursing homes). Treatment consists of isolating the patient, starting topical permethrin and oral ivermectin (in severe cases), washing all linens, and prophylactically treating contacts. A delay in diagnosis can lead to severe debilitating disease, as seen in the extreme case of our patient. However, our patient made a full recovery with appropriate treatment and care.

## REFERENCES

1. Currie BJ, McCarthy JS. Permethrin and ivermectin for scabies. *N Engl J Med*. 2010;362:717-725.
2. World Health Organization. Water-related diseases: scabies. [http://www.who.int/water\\_sanitation\\_health/diseases-risks/diseases/scabies/en/](http://www.who.int/water_sanitation_health/diseases-risks/diseases/scabies/en/). Accessed February 23, 2017.
3. Chosidow O. Scabies and pediculosis. *Lancet*. 2000;355:819-826.
4. Roberts LJ, Huffam SE, Walton SF, et al. Crusted scabies: clinical and immunological findings in seventy-eight patients and a review of the literature. *J Infect*. 2005;50:375-381.
5. Liu X, Walton SF, Murray HC, et al. Crusted scabies is associated with increased IL-17 secretion by skin T cells. *Parasite Immunol*. 2014;36:594-604.
6. Geary TG. Ivermectin 20 years on: maturation of a wonder drug [published online August 26, 2005]. *Trends Parasitol*. 2005;21:530-532.