

# Unilateral Verrucous Porokeratosis of the Gluteal Cleft

Bruno Agelune Schmitz, MD; Timothy Clifton Sorrells, MD; Wilber Delorme, NP

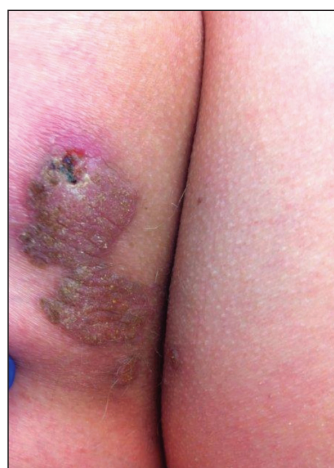### PRACTICE POINT

- Porokeratosis of the gluteal cleft typically is bilateral but may be unilateral.

To the Editor:

Verrucous porokeratosis of the gluteal cleft is a rare skin condition that has distinct clinical and histologic features. A review of 5 cases described a characteristic clinical presentation of a butterfly-shaped bilateral gluteal cleft lesion on most patients.<sup>1</sup> We present an unusual case of verrucous porokeratosis presenting as a unilateral single lesion in the gluteal area that emulated seborrheic keratosis with histology consistent with verrucous porokeratosis. This case adds to the variable presentation of this unusual disease.

A 40-year-old man who presented to the dermatology clinic for a follow-up on a basal cell carcinoma of the temple region was concerned about a lesion on the left buttock of 1 year's duration. Physical examination revealed a unilateral hyperkeratotic plaque that clinically resembled seborrheic keratosis (Figure 1). Biopsy revealed hyperkeratosis with numerous columns of parakeratosis, psoriasiform epidermal hyperplasia (Figures 2A and 2B), dyskeratotic keratinocytes (Figure 2C), pigment incontinence, and mild superficial chronic inflammation consistent with verrucous porokeratosis. The patient was treated with urea lotion but ultimately was lost to follow-up.



**Figure 1.** Verrucous porokeratosis. A unilateral hyperkeratotic plaque on the gluteal cleft that clinically resembled seborrheic keratosis.

We present a unique case of unilateral verrucous porokeratosis of the gluteal cleft. The clinical differential diagnosis included seborrheic keratosis, condyloma acuminata, and inflammatory linear verrucous epidermal nevus. Histopathology was consistent with verrucous porokeratosis. Porokeratosis is a heterogeneous group of keratinization disorders containing several described variants such as classic porokeratosis of Mibelli, disseminated superficial porokeratosis, porokeratosis palmaris et plantaris disseminata, linear porokeratosis, and punctuate porokeratosis.<sup>1,2</sup> Most patients present clinically with plaque-like bilateral (butterfly) lesions with threadlike (ridge) borders, though some patients initially have a unilateral lesion that subsequently develops into a bilateral

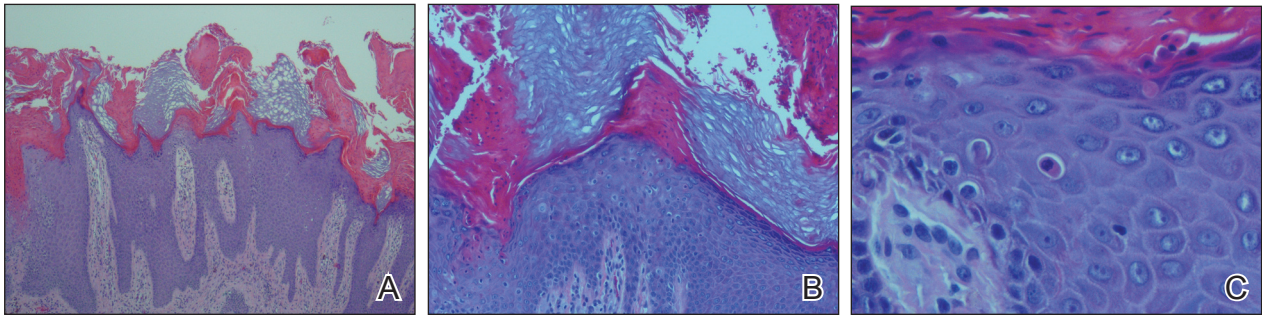
---

From the Naval Medical Center, Portsmouth, Virginia.

The authors report no conflict of interest.

The views expressed in this article are those of the authors and do not necessarily reflect the official policy or position of the US Department of the Navy, Department of Defense, or the US Government.

Correspondence: Bruno Agelune Schmitz, MD  
(bruno.schmitz@med.navy.mil).



**Figure 2.** Verrucous porokeratosis. Biopsy revealed psoriasiform epidermal hyperplasia (A and B) and dyskeratotic keratinocytes (C)(all H&E; original magnifications  $\times 40$ ,  $\times 200$ , and  $\times 400$ , respectively).

lesion.<sup>1</sup> The clinical course is slow growing, but it can potentially give rise to malignancies such as squamous cell carcinoma.<sup>3</sup> Histologically, numerous columns of parakeratosis overlying epidermal cells with attenuated granular layer are observed with the concentric cornoid lamellae considered unique to the verrucous variant.<sup>1</sup> Although our patient had only a single unilateral lesion on the gluteal cleft, the histology was consistent with verrucous porokeratosis. Our case adds to the growing clinical presentations of this unusual disease.

## REFERENCES

1. Takiguchi R, White K, Clifton W, et al. Verrucous porokeratosis of the gluteal cleft (porokeratosis stychotropica): a rare disorder easily misdiagnosed. *J Cutan Pathol.* 2010;37:802-807.
2. McGuigan K, Shurman D, Campanelli C, et al. Porokeratosis ptychotropica: a clinically distinct variant of porokeratosis. *J Am Acad Dermatol.* 2009;60:501-503.
3. Malek J, Chedraoui A, Kibbi AG, et al. Genitogluteal porokeratosis: 10 years to make the diagnosis! *Am J Dermatopathol.* 2009;31:604-606.