

Eumycetoma Pedis in an Albanian Farmer

Monika Fida, MD; Rosita Saraceno, MD; Najada Gjylametaj, MD; Orjana Dervishi, MD; Alma Barbullushi, MD; Suela Kellici, MD; Ermira Vasili, MD

PRACTICE POINTS

- A critical step in the diagnosis of mycetomas is to distinguish between eumycetoma and actinomycetoma.
- Potassium hydroxide preparation is helpful to identify fungal infection.
- Eumycetomas generally are more difficult to treat and require a combined strategy including systemic treatment and surgical therapy.

To the Editor:

Mycetoma is a noncontagious chronic infection of the skin and subcutaneous tissue caused by exogenous fungi or bacteria that can involve deeper structures such as the fasciae, muscles, and bones. Clinically it is characterized by increased swelling of the affected area, fibrosis, nodules, tumefaction, formation of draining sinuses, and abscesses that drain pus-containing grains through fistulae.¹ The initiation of the infection is related to local trauma and can involve muscle, underlying bone, and adjacent organs. The feet are the most commonly affected region, and the incubation period is variable. Patients rarely report prior trauma to the affected area and only seek medical consultation when the nodules and draining sinuses become evident. The etiopathogenesis of mycetoma is associated with aerobic actinomycetes (ie, *Nocardia*, *Actinomadura*, *Streptomyces*), known as actinomycetoma, and fungal infections, known as eumycetomas.¹

We report the case of a 57-year-old Albanian man who was referred to the outpatient clinic of our

dermatology department for diagnosis and treatment of a chronic, suppurative, subcutaneous infection on the right foot presenting as abscesses and draining sinuses. The patient was a farmer and reported that the condition appeared 4 years prior following a laceration he sustained while at work. Dermatologic examination revealed local tumefaction, fistulated nodules, and abscesses discharging a serohemorrhagic fluid on the right foot (Figure 1). Perilesional erythema and subcutaneous swelling were evident. There was no regional lymphadenopathy. Standard laboratory examination was normal. Radiography of the right foot showed no osteolytic lesions or evidence of osteomyelitis.

A skin biopsy from a lesion on the right foot was performed, and identification of the possible etiologic agent was based on direct microscopic examination of the granules, culture isolation of the agent, and fungal microscopic morphology.² Granules were studied under direct examination with potassium hydroxide solution 20% and showed septate branching hyphae (Figure 2). The culture produced colonies that were white, yellow, and brown. Colonies were comprised of dense mycelium with melanin pigment and were grown at 37°C. A lactose tolerance test was positive.² Therefore, the strain was identified as *Madurella mycetomatis*, and a diagnosis of eumycetoma pedis was made.

The patient was hospitalized for 2 weeks and treated with intravenous fluconazole, then treatment with oral itraconazole 200 mg once daily was initiated. At 4-month follow-up, he had self-discontinued treatment but demonstrated partial improvement of the tumefaction, healing of sinus tracts, and functional recovery of the right foot.

One year following the initial presentation, the patient's clinical condition worsened (Figure 3A).

Drs. Fida, Gjylametaj, Dervishi, Barbullushi, Kellici, and Vasili are from the University of Medicine, Tirana, Albania. Drs. Fida and Vasili are from the Department of Dermatology; Drs. Gjylametaj, Dervishi, and Barbullushi are from the Laboratory Department; and Dr. Kellici is from the Faculty of Pharmacy. Dr. Saraceno is from the Department of Dermatology, University of Rome Tor Vergata, Italy.

The authors report no conflict of interest.

Correspondence: Rosita Saraceno, MD, Department of Dermatology, University of Rome Tor Vergata, Policlinico Tor Vergata, viale Oxford 81, IT-00133, Rome, Italy (rositasaraceno@yahoo.it).

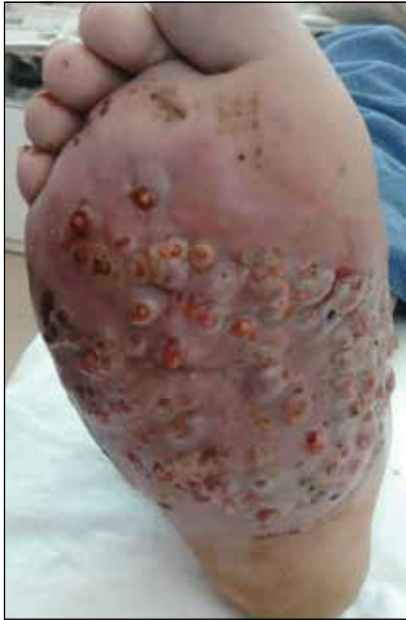

FIGURE 1. Local tumefaction, fistulated nodules, and abscesses discharging a serohemorrhagic fluid on the right foot of a patient with eumycetoma pedis.

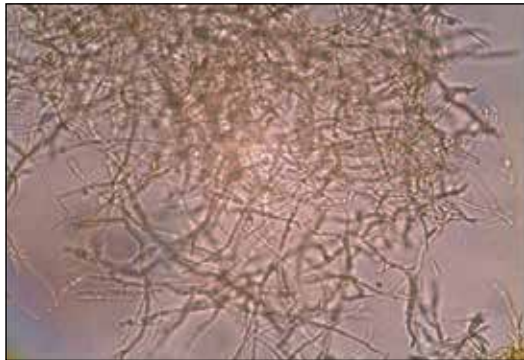


FIGURE 2. Septate branching hyphae were noted with potassium hydroxide solution 20%.

Radiography of the right foot showed osteolytic lesions on bones in the right foot (Figure 3B), and a repeat culture showed the presence of *Staphylococcus aureus*; thus, treatment with itraconazole 200 mg once daily along with antibiotics (cefuroxime and gentamicin) was started immediately. Surgical treatment was recommended, but the patient refused treatment.

Mycetomas are rare in Albania but are common in countries of tropical and subtropical regions. Known as “Madura foot” by the native people, mycetoma was recognized as a disease entity in 1842.¹ In 1860, Carter³ (who established the fungal etiology of this disorder) first proposed the term *mycetoma* and further proposed the terms *melanoid mycetoma* and *ochroid mycetoma* in an attempt to classify the disease into 2 varieties on the basis of the black or pale-colored granules (ie,

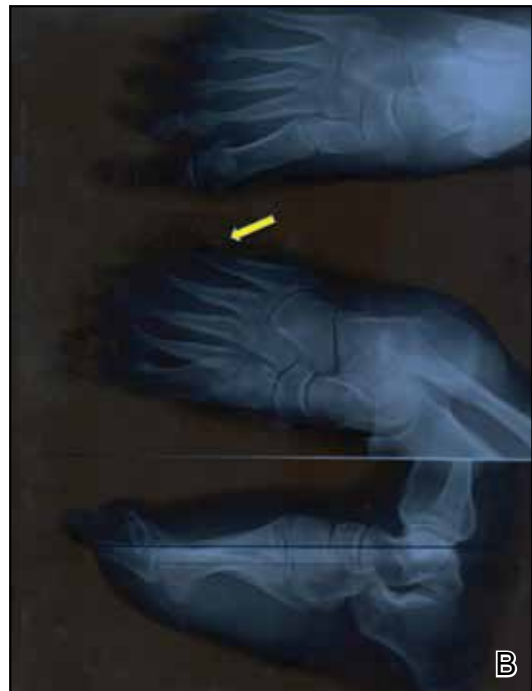
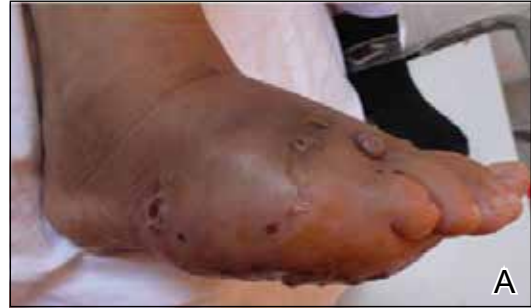
FIGURE 3. Relapse of the lesions (A) and diffuse osteolytic lesions (arrow) on bones in the right foot (B) were noted after treatment discontinuation.

grains, sclerotia) on histology produced by the etiologic agents.²⁻⁴

Clinical features of eumycetoma include lesions with clear margins, few sinuses, black grains, slow progression, and long-term involvement of bone. The grains represent an aggregate of hyphae produced by fungi; thus, the characteristic feature of eumycetoma is the formation of large granules that can involve bone.¹ A critical diagnostic step is to distinguish between eumycetoma and actinomycetoma. If possible, it is important to culture the organism because treatment varies depending on the cause of the infection.

Fungal identification is crucial in the diagnosis of mycetoma. In our case, diagnosis of eumycetoma pedis was based on clinical examination and detection of fungal species by microscopic examination and culture. The color of small granules (black grains) is a parameter used to identify different pathogens on histology but is not sufficient for

diagnosis.⁵ The examination by potassium hydroxide preparation is helpful to identify the hyphae; however, culture is necessary.²

Therapeutic management of eumycetoma needs a combined strategy that includes systemic treatment and surgical therapy. Eumycetomas generally are more difficult to treat than actinomycetomas. Some authors recommend a high dose of amphotericin B as the treatment of choice for eumycetoma,^{6,7} but there are some that emphasize that amphotericin B is partially effective.^{8,9} There also is evidence in the literature of resistance of eumycetoma to ketoconazole treatment^{10,11} and successful treatment with fluconazole and itraconazole.¹⁰⁻¹³ For this reason, we treated our patient with the latter agents. In cases of osteolysis, amputation often is required.

In conclusion, eumycetoma pedis is a rare deep fungal infection that can cause considerable morbidity. Patients should be well educated about this condition and be made aware of the risk of environmental exposure (eg, contact of broken skin with contaminated soil and water) and the need to wear protective footwear in potentially contaminated environments. Early diagnosis, correct treatment, and regular follow-up can reduce the risk of osteolytic complications and increase the possibility of complete recovery.

REFERENCES

1. Rook A, Burns T. *Rook's Textbook of Dermatology*. 8th ed. West Sussex, UK; Hoboken, NJ: Wiley-Blackwell; 2010.
2. Balows A, Hausler WJ, eds. *Manual of Clinical Microbiology*. 5th ed. Washington, DC: American Society for Microbiology; 1991.
3. Carter HV. On a new striking form of fungus disease principally affecting the foot and prevailing endemically in many parts of India. *Trans Med Phys Soc Bombay*. 1860;6:104-142.
4. Kwon-Chung KJ, Bennet JE. *Medical Mycology*. Philadelphia, PA: Lea & Febiger; 1992.
5. Venugopal PV, Venugopal TV. Pale grain eumycetomas in Madras. *Australas J Dermatol*. 1995;36:149-151.
6. Guarro J, Gams W, Pujol I, et al. *Acremonium* species: new emerging fungal opportunists—in vitro antifungal susceptibilities and review. *Clin Infect Dis*. 1997;25:1222-1229.
7. Lau YL, Yuen KY, Lee CW, et al. Invasive *Acremonium falciforme* infection in a patient with severe combined immunodeficiency. *Clin Infect Dis*. 1995;20:197-198.
8. Fincher RM, Fisher JF, Lovell RD, et al. Infection due to the fungus *Acremonium* (cephalosporium). *Medicine (Baltimore)*. 1991;70:398-409.
9. Milburn PB, Papayanopoulos DM, Pomerantz BM. Mycetoma due to *Acremonium falciforme*. *Int J Dermatol*. 1988;27:408-410.
10. Welsh O, Salinas MC, Rodriguez MA. Treatment of eumycetoma and actinomycetoma. *Curr Top Med Mycol*. 1995;6:47-71.
11. Restrepo A. Treatment of tropical mycoses. *J Am Acad Dermatol*. 1994;31:S91-S102.
12. Gugnani HC, Ezeanolue BC, Khalil M, et al. Fluconazole in the therapy of tropical deep mycoses. *Mycoses*. 1995;38:485-488.
13. Welsh O. Mycetoma. current concepts in treatment. *Int J Dermatol*. 1991;30:387-398.