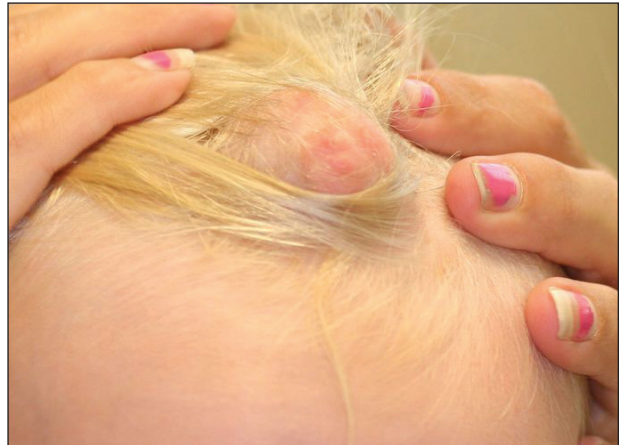

# Lipoblastoma of the Scalp in a Child

Jill S. Wallace, MD; Nicole C. Pace, MD

## PRACTICE POINTS

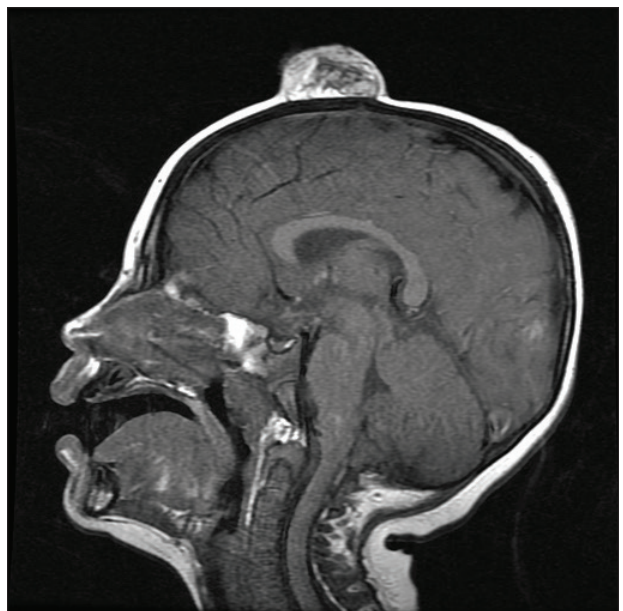
- Lipoblastoma is a benign neoplasm of immature white fat cells primarily seen in children younger than 3 years.
- Lipoblastomas often present as painless nodules located on the extremities.
- Histologically, lipoblastoma reveals immature adipose cells in varying stages of maturity arranged into lobules separated by septae.
- Consider magnetic resonance imaging if visceral extension is a concern; otherwise, surgical excision is curative in most cases.



**FIGURE 1.** Lipoblastoma of the scalp in a 2-year-old boy.

To the Editor:

A 2-year-old boy was referred to our pediatric dermatology clinic by his pediatrician for an enlarging mass on the mid frontal scalp. The lesion had been present since birth and slowly enlarged. His parents thought the lesion was mostly asymptomatic; however, if it was irritated, the child would cry. He was otherwise healthy and had no history of skin conditions. There was no family history of skin conditions, birthmarks, or vascular malformations. On physical examination, we observed an isolated, approximately 3-cm, well-circumscribed, mobile, flesh-colored and violaceous nodule on the mid frontal scalp (Figure 1). At that time our differential diagnosis included a complex hemangioma or other vascular proliferation, nevus lipomatosis, or even a soft-tissue malignancy such as a sarcoma. Prior to biopsy, we ordered magnetic resonance imaging (MRI) to evaluate for intracranial extension of the lesion. The MRI revealed a 3.2-cm frontal midline scalp mass with complex imaging characteristics, and the radiologist gave a differential diagnosis of hemangioma, teratoma, or less likely liposarcoma (Figure 2). Fortunately, there was no evidence of central nervous system or intracranial invasion. We then proceeded with excisional biopsy, which grossly revealed a nodular, well-circumscribed, yellow mass (Figure 3). The wound was closed with primary closure. Histologically, there was

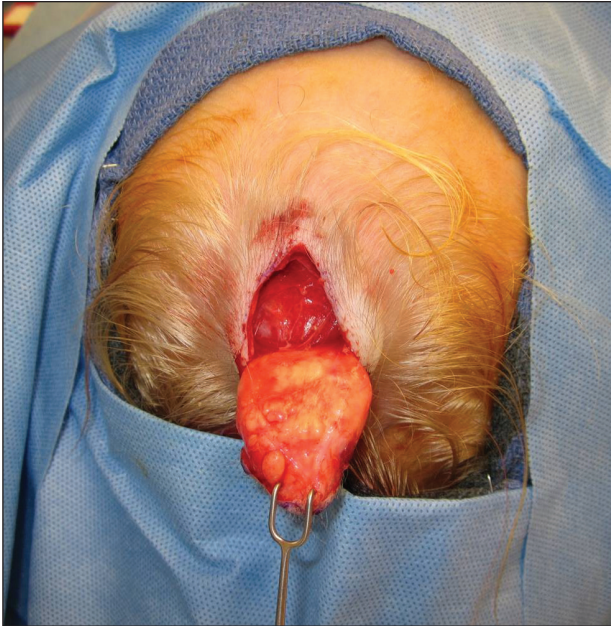


**FIGURE 2.** Magnetic resonance imaging revealed a 3.2-cm soft-tissue mass without intracranial extension.

Dr. Wallace was from and Dr. Pace is from the Section of Dermatology, Dartmouth Hitchcock Medical Center, Lebanon, New Hampshire. Dr. Wallace currently is in private practice, Kansas City, Missouri.

The authors report no conflict of interest.

Correspondence: Jill S. Wallace, MD (wallacejills@gmail.com).



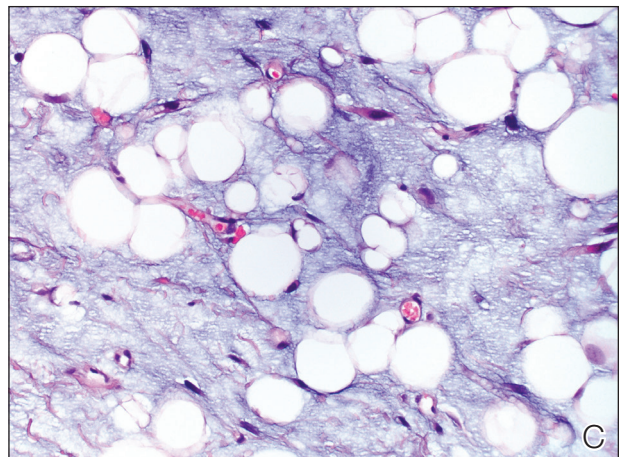
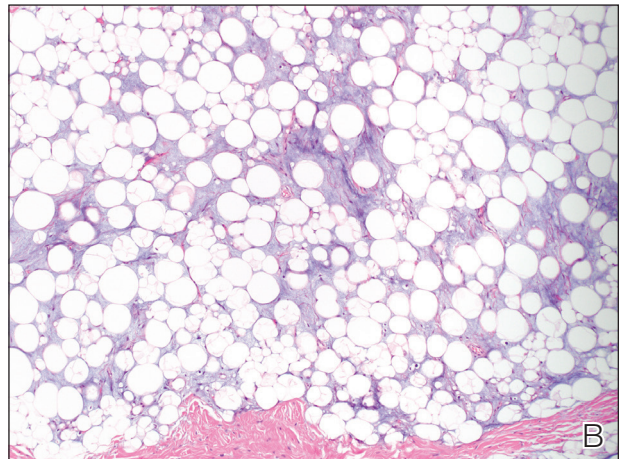
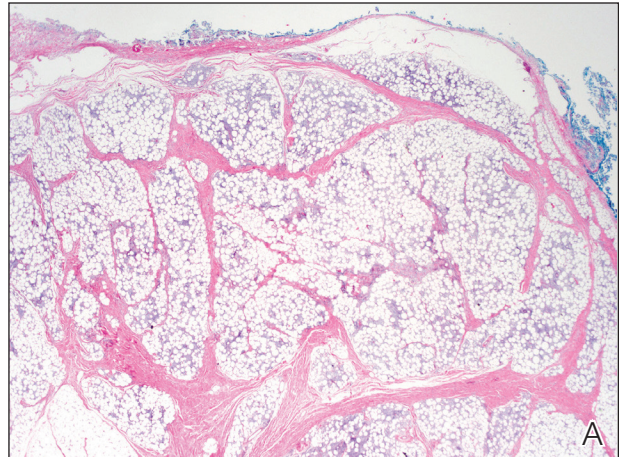
**FIGURE 3.** Gross appearance of the tumor revealed a well-circumscribed yellow mass.

a lobulated tumor with thin, well-vascularized connective tissue septa within a myxoid stroma (Figure 4A). The tumor was composed of lipocytes in varying stages of maturity without obvious nuclear atypia (Figures 4B and 4C), leading to a diagnosis of lipoblastoma.

Lipoblastoma (also known as an embryonic lipoma) is a rare variant of lipoma. It is a benign neoplasm of immature white fat cells primarily seen in children younger than 3 years. It is reportedly twice as common in boys versus girls. Lipoblastomas present as enlarging, soft, mobile, painless nodules, usually 3 to 5 cm in diameter. The extremities are the favored location, but they also have been described on the head, neck, and trunk. Additionally, mediastinal and retroperitoneal lipoblastomas have been documented.<sup>1</sup> The tumors may be symptomatic, particularly when involving the neck or mediastinum. In rare instances, they may present with respiratory distress.<sup>2</sup> Multiple cases of head and neck lipoblastomas have been published in the English-language literature.<sup>3</sup> Growing evidence supports that a chromosomal breakpoint abnormality at 8q11-q13 may be implicated in the pathogenesis.<sup>4</sup>

Most lipoblastomas are well circumscribed, encapsulated, and limited to the subcutis. However, lipoblastomatosis is the diffuse counterpart to lipoblastoma, affecting deeper soft tissue and often infiltrating adjacent skeletal muscle.<sup>1</sup>

Diagnosis is made by histologic evaluation. Lipoblastoma appears as immature fat cells in varying stages of maturity with septa separating them into lobules. There should not be nuclear atypia.<sup>5</sup> The histologic differential diagnosis includes other adipose



**FIGURE 4.** Histopathology showed a lobulated tumor with thin, well-vascularized connective tissue septa with a myxoid stroma (A) (H&E, original magnification  $\times 2$ ). Higher-power view showed mature fat cells intermingled with spindle-shaped mesenchymal cells and lipoblasts (B) as well as cellular features (C) (H&E, original magnifications  $\times 4$  and  $\times 10$ ).

tumors, most chiefly myxoid liposarcoma. These tumors have a lobular pattern without prominent septae and contain nuclear atypia with atypical mitotic figures. Myxoid liposarcoma has an infiltrating pattern similar to

lipoblastomatosis and has a metastatic rate up to 60%.<sup>6</sup> Imaging studies such as MRI are helpful in diagnosis, particularly in head and neck or visceral cases.<sup>3</sup> The treatment of choice of lipoblastoma is wide excision. With complete removal, tumors rarely recur. Recurrences are more common in lipoblastomatosis or with incompletely excised primary lesions.<sup>3</sup> A 14% to 24% recurrence rate has been recognized. Cytogenetic analysis of lipomatous tumors has begun to reveal translocations in chromosome 8q11-13 region breakpoint abnormalities and translocations, specifically involving the pleomorphic adenoma gene 1, *PLAG1*, as the oncogenic target in lipoblastoma.<sup>6</sup> Identification of these molecular mutations may provide aid in differentiating histologically similar-appearing tumors in the future.

This case illustrates a rare benign childhood tumor that can be difficult to diagnose prior to histologic examination. Our patient did not fit the typical description of a lipoblastoma, as his tumor was axially located as

opposed to the more common peripheral presentation. We aim to raise awareness of this diagnosis as more cases are being recognized.

#### REFERENCES

1. Kaddu S, Kohler S. Muscle, adipose, and cartilage neoplasms. In: Bologna JL, Jorizzo JL, Rapini RP, eds. *Dermatology*. St. Louis, MO: Mosby; 2003:1988-1989.
2. Benato C, Falezza G, Lonardoni A, et al. Acute respiratory distress caused by a giant mediastinal lipoblastoma in a 16-month-old boy. *Ann Thorac Surg*. 2011;92:119-120.
3. Pham NS, Poirier B, Fuller SC, et al. Pediatric lipoblastoma in the head and neck: a systematic review of 48 reported cases. *Int J Pediatr Otorhinolaryngol*. 2010;74:723-728.
4. Chen Z, Coffin CM, Scott S, et al. Evidence by spectral karyotyping that 8q11.2 is nonrandomly involved in lipoblastoma. *J Mol Diagn*. 2000;2:73-77.
5. Weedon, D. *Weedon's Skin Pathology*. 3rd ed. China: Churchill Livingstone; 2010.
6. Hicks J, Dilley A, Patal D. Lipoblastoma and lipoblastomatosis in infancy and childhood: histopathologic, ultrastructural, and cytogenetic features. *Ultrastruct Pathol*. 2001;25:321-333.