

# Clinical Pearl: Advantages of the Scalp as a Split-Thickness Skin Graft Donor Site

Julie Ann Amthor Croley, MD; Jason M. Hirshburg, MD, PhD; Richard F. Wagner Jr, MD

Common challenges associated with split-thickness skin graft (STSG) donor site wounds include slow healing times and poor scar cosmesis. The technique described here improves these shortcomings by utilizing a Weck knife with adjustable thickness controls to harvest STSGs from the scalp.

*Cutis*. 2019;103:369-370.

## Practice Gap

Common donor sites for split-thickness skin grafts (STSGs) include the abdomen, buttocks, inner upper arms and forearms, and thighs. Challenges associated with donor site wounds in these areas include slow healing times and poor scar cosmesis. Although the scalp is not commonly considered when selecting a STSG donor site, harvesting from this area yields optimal results to improve these shortcomings.

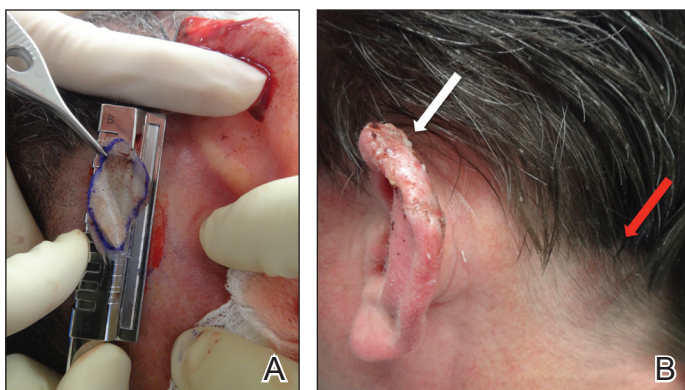
## Tools

A Weck knife facilitates STSG harvesting in an operationally timely, convenient fashion from larger donor sites up to 5.5 cm in width, such as the scalp, using adjustable thickness control guards.

## The Technique

The donor site is lubricated with a sterile mineral oil. An assistant provides tension, leading the trajectory of the Weck knife with a guard. Small, gentle, back-and-forth strokes are made with the Weck knife to harvest the graft, which is then meshed with a No. 15 blade by placing the belly of the blade on the tissue and rolling it to-and-fro. The recipient site cartilage is fenestrated with a 2-mm punch biopsy.

A 48-year-old man underwent Mohs micrographic surgery for treatment of a primary basal cell carcinoma of the left helix, resulting in a 2.5×1.3-cm defect after 2 stages. A Weck knife with a 0.012-in guard was used to harvest an STSG from the postauricular scalp (Figure, A), and the graft was inset to the recipient wound bed. Hemostasis at the scalp donor site was achieved through application of pressure and sterile gauze that was saturated with local 1% lidocaine anesthesia containing 1:400,000 epinephrine. Both recipient and donor sites were dressed with tie-over bolsters that were sutured into place. At 2-week follow-up, the donor site was fully reepithelialized and hair regrowth obscured the defect (Figure, B).



A, The Weck knife technique for harvesting donor tissue from the scalp following Mohs micrographic surgery on the left helix. B, At 2-week follow-up, the postauricular scalp donor site demonstrated complete reepithelialization and hair regrowth hiding the cosmetic defect (red arrow). The white arrow indicates the recipient site at the left helix.

From the Department of Dermatology, The University of Texas Medical Branch at Galveston.

The authors report no conflict of interest.

Correspondence: Julie Ann Amthor Croley, MD, Office of the Department of Dermatology, 301 University Blvd, 4.112 McCullough Bldg, Galveston, TX 77555 (jaamthor@utmb.edu).

## Practice Implications

Our case demonstrates the advantages of the scalp as an STSG donor site with prompt healing time and excellent cosmesis. Because grafts are harvested at a depth superficial to the hair follicle, the hair regrows to conceal the donor site scar. Additionally, the robust blood supply of the scalp and hair follicle density optimize healing time. The location of the donor site at the postauricular scalp facilitates accessibility for wound care by the patient. Electrocautery or chemical styptics used for hemostasis may traumatize the hair follicles and risk causing alopecia; therefore, as demonstrated in our case, the preferred method to achieve hemostasis is the use of pressure or application of sterile gauze that has been saturated with local 1% lidocaine anesthesia containing 1:400,000 epinephrine, followed by a pressure dressing provided by a sutured bolster.

Our case also demonstrates the utility of the Weck knife, which was introduced in 1968 as a modification of existing instruments to improve the ease of harvesting STSGs by appending a fixed handle and interchangeable depth gauges to a straight razor.<sup>1,2</sup> The Weck knife can obtain grafts up to 5.5 cm in width (length may be as long as anatomically available), often circumventing the need to overlap grafts of smaller widths for repair of larger defects. Furthermore, grafts are harvested at a depth superficial to the hair follicle, averting donor site alopecia. These characteristics make the technique an ideal option for harvesting grafts from the scalp and other large donor sites.

Limitations of the Weck knife technique include the inability to harvest grafts from small donor sites in difficult-to-access anatomic regions or from areas with notable 3-dimensional structure. For harvesting such grafts, we prefer the DermaBlade (AccuTec Blades). Furthermore, assistance for providing tension along the trajectory of the Weck blade with a guard is optimal when performing the procedure. For practices not already utilizing a Weck knife, the technique necessitates additional training and cost. Nonetheless, for STSGs in which large donor site surface area, adjustable thickness, and convenient and timely operational technique are desired, the Weck knife should be considered as part of the dermatologic surgeon's armamentarium.

## REFERENCES

1. Aneer F, Singh AK, Kumar S. Evolution of instruments for harvest of the skin grafts. *Indian J Plast Surg*. 2013;46:28-35.
2. Goulian D. A new economical dermatome. *Plast Reconstr Surg*. 1968;42:85-86.