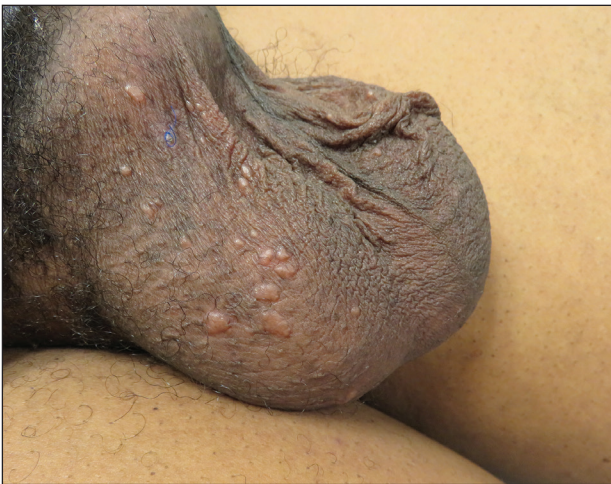

# Flesh-Colored Papules on the Scrotum

Shatha Ahmad Al Hajjaj, MD; Thomas M. R nger, MD, PhD; Hye Jin Chung, MD, MMS



A 44-year-old black man presented with “bumps on the scrotum” of approximately 4 months’ duration. They were asymptomatic and untreated. The patient denied extramarital sexual contacts or a history of any sexually transmitted infection. His medical history was notable for sarcoidosis diagnosed 4 years prior to presentation when hilar lymphadenopathy was incidentally found on routine screening. His condition was managed with regular follow-up without treatment. He also had a positive tuberculosis skin test in the past without radiologic evidence of active pulmonary disease. Physical examination revealed multiple 2- to 5-mm, flesh-colored, shiny, polygonal, flat-topped papules spread diffusely over the scrotum. A 1-cm, barely palpable, nonscaly, violaceous to brown plaque also was seen on the tip of the nose. A punch biopsy was taken from a lesion on the scrotum.

## WHAT’S THE DIAGNOSIS?

- condyloma acuminatum
- cutaneous sarcoidosis
- idiopathic scrotal calcinosis
- lichen planus
- steatocystoma multiplex

PLEASE TURN TO **PAGE E24** FOR THE DIAGNOSIS

From the Department of Dermatology, Boston University School of Medicine, Massachusetts.

The authors report no conflict of interest.

Correspondence: Hye Jin Chung, MD, MMS, 609 Albany St, Room J-401, Boston, MA 02118 (hyejin.chung@bmc.org).

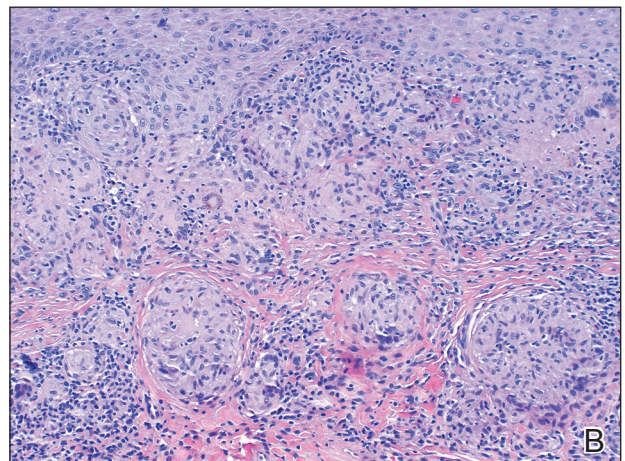
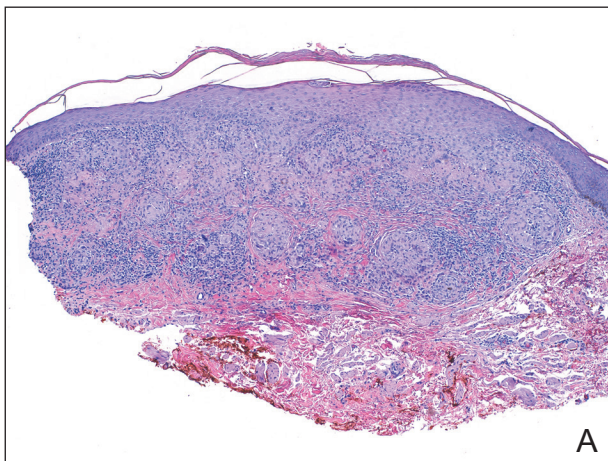
## THE DIAGNOSIS: Cutaneous Sarcoidosis

**H**istologic examination of the shave biopsy showed focal parakeratosis, irregular epidermal hyperplasia, and multiple noncaseating naked granulomas with occasional multinucleated giant cells in the dermis (Figure, A). The granulomas were surrounded by mild lymphocytic infiltration with rare eosinophils (Figure, B). Periodic acid–Schiff and Fite stains were negative for organisms, and polariscopic examination was negative; these findings confirmed the diagnosis of cutaneous sarcoidosis. Topical or intralesional steroids were recommended, but our patient declined treatment given that the lesions were asymptomatic.

Sarcoidosis is a multisystem granulomatous disease of unknown etiology that affects the skin in approximately 25% of patients.<sup>1</sup> Cutaneous lesions manifest in 2 forms: specific and nonspecific. Noncaseating granulomas are considered specific. Nonspecific lesions include erythema nodosum, calcinosis cutis, Sweet syndrome, and nail clubbing. The most common sites of specific sarcoidosis lesions include the face, lips, neck, upper trunk, and extremities. Few cases have reported cutaneous sarcoidosis involving the genitalia; most reports describe vulvar cutaneous sarcoidosis.<sup>2–4</sup> Although there have been reports of sarcoidosis involving the epididymis and testes, which presented as scrotal masses, cutaneous scrotal involvement with the skin as the primary site of involvement is rare.<sup>5,6</sup> McLaughlin et al<sup>5</sup> reported an extensive, pruritic, and eczematous eruption of the scrotum with associated edema and tenderness. Wei et al<sup>6</sup> reported cutaneous sarcoidosis in the form of multiple indurated papules involving the penis and scrotum, similar to our case.

Comparing our patient to the case reported by Wei et al,<sup>6</sup> both patients had Fitzpatrick skin type V or VI and systemic involvement including pulmonary disease. However, Wei et al<sup>6</sup> did not clearly mention if the cutaneous manifestations preceded the diagnosis of systemic sarcoidosis or if they were present at the time of the diagnosis. Our patient developed cutaneous lesions 4 years after being diagnosed with systemic sarcoidosis from hilar lymphadenopathy. In addition to the scrotal lesions, he also had a lesion of lupus pernio presenting as a violaceous to brown plaque on the tip of the nose. Although both patients denied pruritus, the other patient's lesions were painful.<sup>6</sup> Wei et al<sup>6</sup> mentioned that treatment with topical, intralesional, and systemic steroids failed, and the patient's lesions continued to progress. Generally, topical and intralesional steroids are considered mainstay treatment of cutaneous sarcoidosis despite insufficient data to support their efficacy.<sup>7</sup>

The differential diagnosis of papules on the scrotum can be broad. Our provisional diagnoses for this particular morphology of small, flesh-colored, shiny, polygonal, flat-topped papules included condyloma acuminatum; lichen planus; idiopathic scrotal calcinosis; steatocystoma multiplex; and sarcoidosis (although uncommon for the site), given the history of pulmonary involvement. We considered a diagnosis of condyloma acuminatum, but the lesions were too shiny and smooth. On histology, condyloma acuminatum shows a hyperkeratotic and parakeratotic stratum corneum, an exophytic growth with marked acanthosis, and superficially located koilocytes. Morphologically, our patient's lesions resembled genital lichen planus. However, Wickham striae were absent, and



Cutaneous sarcoidosis. A and B, Shave biopsy specimen with multiple noncaseating naked granulomas surrounded by mild lymphocytic infiltration (H&E, original magnifications  $\times 40$  and  $\times 100$ ).

our patient's lesions were asymptomatic while lesions of lichen planus usually are pruritic. Histologically, lichen planus is characterized by hyperkeratosis, hypergranulosis, sawtooth rete ridges, and lichenoid interface inflammation. Idiopathic scrotal calcinosis also could be included in the differential; however, the lesions would look whiter and firmer than those of our patient, and biopsy will clearly show calcium deposition. Steatocystoma multiplex is another condition that can affect the scrotum, along with the trunk, axillae, extremities, and neck. However, the lesions are expected to discharge oily material if squeezed and have a characteristic corrugated eosinophilic cuticle lining a cyst histologically.

Although it is undetermined if the risk for systemic involvement increases in patients with cutaneous sarcoidosis, evaluation for probable systemic involvement is necessary.<sup>1</sup> Because cutaneous sarcoidosis generally can precede any systemic involvement, it would be

reasonable to consider skin biopsies in patients who present with atypical wartlike lesions on the scrotum and penis to rule out sarcoidosis.

#### REFERENCES

1. Marcoval J, Mañá J, Rubio M. Specific cutaneous lesions in patients with systemic sarcoidosis: relationship to severity and chronicity of disease. *Clin Exp Dermatol*. 2011;36:739.
2. Vera C, Funaro D, Bouffard D. Vulvar sarcoidosis: case report and review of the literature. *J Cutan Med Surg*. 2013;17:287-290.
3. Watkins S, Ismail A, McKay K, et al. Systemic sarcoidosis with unique vulvar involvement. *JAMA Dermatol*. 2014;150:666-667.
4. Pereira IB, Khan A. Sarcoidosis rare cutaneous manifestations: vulvar and perianal involvement. *J Obstet Gynaecol*. 2017;6:1-2.
5. McLaughlin SS, Linquist AM, Burnett JW. Cutaneous sarcoidosis of the scrotum: a rare manifestation of systemic disease. *Acta Derm Venereol*. 2002;82:216-217.
6. Wei H, Friedman KA, Rudikoff D. Multiple indurated papules on penis and scrotum. *J Cutan Med Surg*. 2000;4:202-204.
7. Doherty CB, Rosen T. Evidence-based therapy for cutaneous sarcoidosis. *Drugs*. 2008;68:1361.