

Chondrodermatitis Nodularis Helicis in an Adolescent Boy: Not Just for Old Men

Larisa M. Lehmer, MD; Victoria M. Roseman; Kurt F. Lundquist, MD

PRACTICE POINTS

- Chondrodermatitis nodularis helicis should be in the differential for nodular lesions on the ears of adolescents, as societal shifts in behavior have altered the epidemiology of this condition such that it is no longer exclusive to the geriatric population.
- Make sure to get a thorough history of potential pressure triggers when evaluating nodules on the ears of adolescents.

Chondrodermatitis nodularis helicis (CNH) is a solitary, chronic, painful, often ulcerated lesion on the upper portion of the ear, mostly in older men. We present an unusual case of CNH in a 17-year-old adolescent boy who was a lifeguard. Correlation between clinical and histopathologic characteristics of CNH is outlined in the context of the existing literature to increase awareness of this condition in younger patients as well as to guide appropriate management and surveillance.

Cutis. 2019;104:E6-E8.

Chondrodermatitis nodularis helicis (CNH) is a chronic painful or crusted, 4- to 6-mm, solitary nodule, primarily on the upper part of the ear (most commonly on the right side). The presence of pain, which increases the likelihood that a person will seek treatment, clinically distinguishes CNH from other cutaneous tumors in the differential diagnosis that produce painless ulceration.

It is roughly 5 times more prevalent in males (72.9%),¹ with an average age of onset of 65 years.²

However, CNH has been reported in females³ and rarely in individuals younger than 20 years. According to a PubMed search of articles indexed for MEDLINE and a Google Scholar search using the terms *chondrodermatitis nodularis helicis child*, only 6 cases of CNH have been reported in the pediatric population.⁴⁻⁸ The youngest reported case was a 9-month-old infant.⁸ Including the present case, males and females in the pediatric population are equally affected; 4 patients had an underlying dermatomyositis,⁷ rheumatoid nodule,⁸ or systemic disease, including systemic lupus erythematosus and Beckwith-Wiedemann syndrome.^{5,9} Chronic intermittent pressure from headwear was the etiologic agent in the remaining cases.⁴ Recognizing that CNH can occur in young patients and can be associated with underlying autoimmune disease helps direct management and avoid overly invasive treatment.

Case Report

A 17-year-old adolescent boy presented with a painful ulcerated papule on the right upper helix of 3 months' duration (Figure 1). The patient habitually slept on the right side, pressed a cell phone to that ear, and wore a tight-fitting visor while lifeguarding, which, along with solar damage, all may have contributed to the disease process. He was otherwise in good health, without a history of underlying systemic disease. Given the patient's extensive occupational sun exposure, biopsy of the lesion was taken under the impression of CNH vs squamous cell carcinoma or basal cell carcinoma.

Histopathologic analysis revealed a central area of ulceration with edematous degenerated dermal collagen and overlying inflammatory crust, characteristic of CNH

Dr. Lehmer is from University of California Irvine Health. Ms. Roseman and Dr. Lundquist are from Western Diagnostic Services Laboratories, San Luis Obispo, California.

The authors report no conflict of interest.

Correspondence: Larisa M. Lehmer, MD, 333 City Blvd W, Ste 400, Orange, CA (lmllehmer@gmail.com).

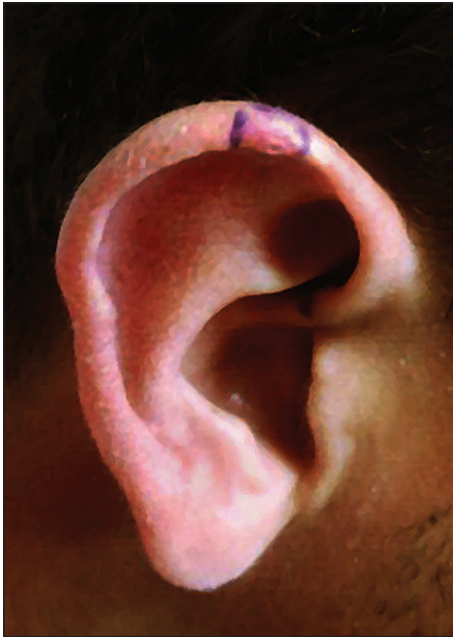

FIGURE 1. Chondrodermatitis nodularis helicis. An erythematous 7-mm papule with central ulceration on the right upper helix of 3 months' duration.

(Figure 2A). Biopsy in this patient demonstrated classic histopathologic findings of CNH, including a central area of epidermal ulceration capped by an inflammatory crust and an underlying edematous degenerated dermal collagen (Figure 2B).

Following biopsy, the patient was advised of this diagnosis and recommended to avoid applying pressure to the area with cell phones or hats or when sleeping to prevent recurrence. At 3-month follow-up, no residual lesion remained.

Comment

Pathogenesis—The exact cause of CNH is unknown but is probably the result of prolonged and excessive pressure on the ear that leads to ischemic injury to cartilage and skin. The external location of CNH, lack of bony support, and exquisitely thin padding or insulation in the form of subcutaneous tissue make the small dermal blood vessels supplying the outer ear vulnerable to compression. Dermal inflammation; edema; and necrosis from trauma, cold, or actinic damage also can help initiate CNH. This disruption of blood perfusion to the external ear also inhibits the ear's ability to heal. A cycle of pressure from objects such as a pillow or cell phone, followed by inadequate healing, leads to secondary perichondritis and remodeling of perichondrial arterioles, which is demonstrated histologically by the presence of perichondrial fibrous thickening, mild chronic inflammation, collagen degeneration, hyalinization, and rarely necrosis or calcification. Healed lesions often show dermal fibrosis overlying perichondrium.

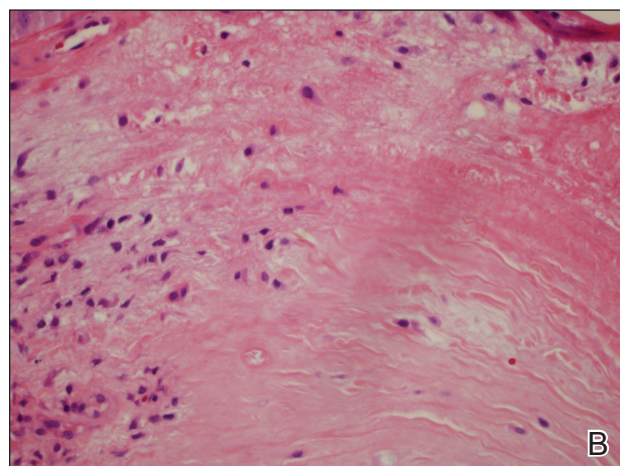
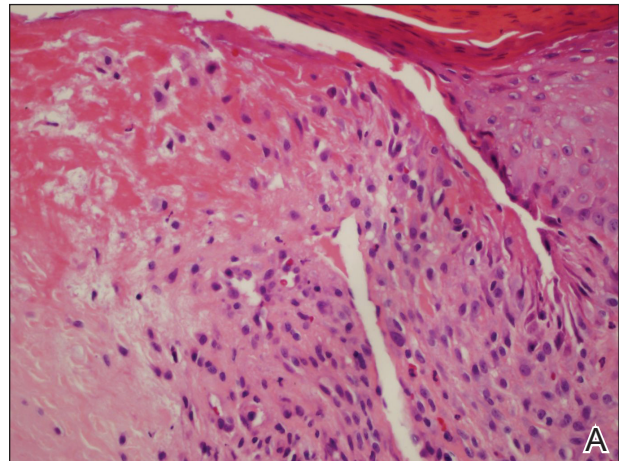


FIGURE 2. A, Histopathology revealed variable epidermal acanthosis at the margins of the central defect, which in rare cases assumes the proportions of pseudoepitheliomatous hyperplasia (H&E, original magnification $\times 10$). Palisaded histiocytes surrounded the necrobiotic zone. B, Irregular slit-like spaces extended into degenerated dermal collagen (H&E, original magnification $\times 40$).

Repeated pressure can lead to vascular changes, but underlying vascular disease also can predispose a person to CNH at a younger age. A striking case of bilateral CNH was reported in an 8-year-old girl with a known history of dermatomyositis.⁷ Furthermore, in 24 patients with CNH (mean age, 43 years), Magro et al⁹ observed an association between CNH and collagen vascular disease, scleroderma, hypertension, thyroid disease, and heart disease, with a higher incidence of any of these medical problems in younger patients. Therefore, screening all patients presenting with CNH, particularly those younger than their fourth decade, for underlying vasculopathy and an autoimmune connective tissue disorder is advised.⁹

Other findings of CNH reported in the literature include loss of elastic fibers in the central area of degenerated dermal collagen and nerve hyperplasia, which might account for pain.⁶ Many of the biopsies in cases of CNH reported in the literature also demonstrate

perichondrial fibrous thickening, mild chronic inflammation, and degenerative changes in collagen, including hyalinization and rarely necrosis and calcification. Skin at the periphery of the lesion usually contains granulation tissue, with a mild to moderate inflammatory infiltrate and dilated vessels extending beyond the lesion.²

Genetics might play a role in the disorder, which is suggested by the occurrence of CNH in monozygotic twins¹⁰ and in an otherwise healthy 16-year-old adolescent girl with CNH of the right ear who screened negative for underlying connective tissue disease—serologic tests included antinuclear antibody, anti-Sm, anti-SCL-70, anti-Ro, anti-La, and rheumatoid factor—but who had a family history of a maternal grandmother with CNH, also on the right side.⁶

In the present case, there was no family history or signs and symptoms of underlying systemic disease at the time of diagnosis. The social history revealed excessive occupational sun exposure, habitually wearing a tight visor, and frequent cell phone use, all of which might have contributed to CNH.

Management—Medical management is geared toward relieving pressure at the site of the lesion, which was accomplished by use of an off-loading, ring-shaped, foam pillow at night in a 9-month-old girl with CNH, in which the smaller of her 2 left-sided lesions completely resolved by 6-month follow-up.⁸ However, it often is difficult to achieve adequate relief of pressure because of the patient's preference for holding a cell phone to a particular ear or unconscious sleeping habits that perpetuate lesions. There are many creative physical interventions to offload aggravating pressure from the area during sleep. A prosthesis can be fashioned by cutting a hole from the center of a bath sponge and securing it with a headband,¹¹ or a crescentic or rectangular piece of self-adhering foam sponge can be applied to the non-hair-bearing postauricular scalp during sleep.¹² Topical antibiotics might relieve pain caused by secondary infection.

Surgical intervention, with or without placement of a full-thickness skin graft, is the mainstay of therapy. Excision was performed in 3 previously reported pediatric cases, with no recurrence reported at 6- to 24-month follow-up. Other treatments employed to varying effect include topical and intralesional steroids, collagen injection, cryotherapy, nitroglycerin paste 2% twice daily,¹³ and electrodesiccation and curettage.¹⁴ In adults, if full resolution is desired, multiple surgeries might be required to remove underlying protuberant cartilage; however, this strategy is not without risk of complication, including formation of adjacent cartilaginous nodules that can

become site(s) of CNH recurrence due to a change in pressure points.

Conclusion

Although uncommon, CNH can present on the ears of young patients. A causal link between underlying vasculopathy and CNH has yet to be determined, but the association discovered by Magro et al⁹ merits obtaining a more detailed rheumatologic history and examination, followed by serologic testing (if indicated). Once the diagnosis of CNH is determined, patient education is paramount to prevent recurrence. Increased awareness of habits that inflict persistent repetitive trauma or pressure to the site—from sleeping patterns to cell phone use—will help to extinguish the behavior and therefore the lesion.

REFERENCES

1. Rex J, Rivera M, Bielsa I, et al. Narrow elliptical skin excision and cartilage shaving for treatment of chondrodermatitis nodularis. *Dermatol Surg.* 2006;32:400-404.
2. Wettlé C, Keller F, Will F, et al. Chondrodermatitis nodularis chronica helioides: a descriptive study of 99 patients [in French]. *Ann Dermatol Venerol.* 2013;140:687-692.
3. Oelzner S, Elsner P. Bilateral chondrodermatitis nodularis chronica helioides on the free border of the helix in a woman. *J Am Acad Dermatol.* 2003;49:720-722.
4. Grigoryants V, Qureshi H, Patterson J, et al. Pediatric chondrodermatitis nodularis helioides. *J Craniofac Surg.* 2007;18:228-231.
5. Fix WC, Cornejo C, Duffy KA, et al. Pediatric chondrodermatitis nodularis helioides (CNH) in a child with Beckwith-Wiedemann syndrome (BWS). *Pediatr Dermatol.* 2019;36:388-390.
6. Rogers NE, Farris PK, Wang AR. Juvenile chondrodermatitis nodularis helioides: case report and literature review. *Pediatr Dermatol.* 2003;20:488-490.
7. Sasaki T, Nishizawa H, Sugita Y. Chondrodermatitis nodularis helioides in childhood dermatomyositis. *Br J Dermatol.* 1999;141:363-365.
8. Tsai TH, Lin YC, Chen HC. Infantile chondrodermatitis nodularis. *Pediatr Dermatol.* 2007;24:337-339.
9. Magro CM, Frambach GE, Crowson AN. Chondrodermatitis nodularis helioides as a marker of internal disease associated with microvascular injury. *J Cutan Pathol.* 2005;32:329-333.
10. Chan HP, Neuhaus IM, Maibach HI. Chondrodermatitis nodularis chronica helioides in monozygotic twins. *Clin Exp Dermatol.* 2009;34:358-359.
11. Moncrieff M, Sassoon EM. Effective treatment of chondrodermatitis nodularis chronica helioides using a conservative approach. *Br J Dermatol.* 2004;150:892-894.
12. Travelute CR. Self-adhering foam: a simple method for pressure relief during sleep in patients with chondrodermatitis nodularis helioides. *Dermatol Surg.* 2013;39:317-319.
13. Flynn V, Chisholm C, Grimwood R. Topical nitroglycerin: a promising treatment option for chondrodermatitis nodularis helioides. *J Am Acad Dermatol.* 2011;65:531-536.
14. Kromann N, Høyer H, Reymann F. Chondrodermatitis nodularis chronica helioides treated with curettage and electrocauterization: follow-up of a 15-year material. *Acta Derm Venereol.* 1983;63:85-87.