

# Subungual Hemorrhage From an Epidermal Growth Factor Receptor Inhibitor

Josh A. Hammel, MD; Dean Elhag, MD; Nkanyezi N. Ferguson, MD

## PRACTICE POINTS

- Subungual hemorrhage is a potential adverse side effect of epidermal growth factor receptor inhibitors.
- Epidermal growth factor receptor inhibition may lead to enhanced fragility of the periungual skin and nail plate as well as a proinflammatory microenvironment in the skin, predisposing patients to nail toxicity.

To the Editor:

The epidermal growth factor receptor (EGFR) signaling pathway plays a role in the differentiation, proliferation, and survival of several cell types.<sup>1</sup> Erlotinib is an EGFR inhibitor that targets aberrant cells that overexpress this receptor and has been used in the treatment of various solid malignant tumors.<sup>2,3</sup> Common dermatologic side effects associated with EGFR inhibitors include papulopustular rash, xeroderma, and paronychia.<sup>2,3</sup> We present a unique finding of subungual hemorrhage of the thumbnails in a patient taking erlotinib.

A 50-year-old man presented with acute-onset tenderness and discoloration of the thumbnails of 1 week's duration. There was no preceding trauma or history of similar symptoms. His medical history was notable for recurrent lung adenocarcinoma with *EGFR* L858R mutation. Erlotinib therapy was initiated 5 weeks prior to symptom onset. He developed notable xeroderma of the palms and soles that preceded nail changes by a few days. He completed treatment with carboplatin and pemetrexed

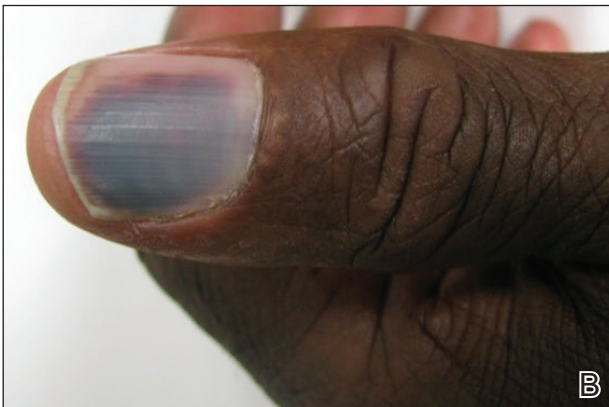
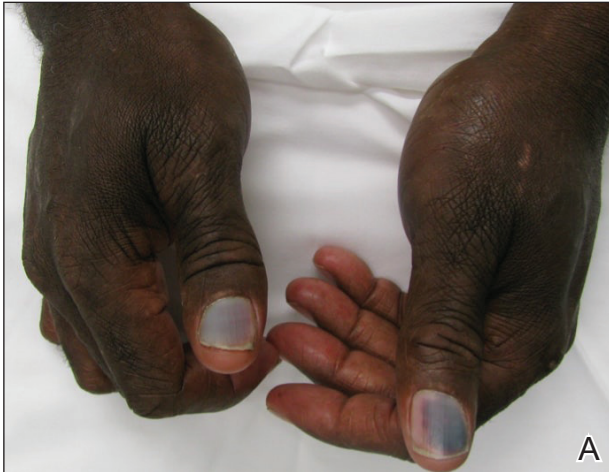16 months prior to relapse after paclitaxel failed due to a severe allergic reaction. There were no nail symptoms during that time. The patient did not have a documented coagulation disorder and was not on any known medications that would predispose him to bleeding. Physical examination demonstrated subungual hemorrhage of the thumbnails with tenderness on palpation (Figure). There was no evidence of periungual changes or nail plate abnormality. All other nails appeared normal. Laboratory test results showed normal platelets. Supportive therapeutic measures were recommended, and the patient was advised to avoid trauma to the nails.

Nail toxicities reported with EGFR inhibitors include paronychia, periungual pyogenic granulomas, and ingrown nails.<sup>1-3</sup> Inflammation of the nail bed also can lead to secondary nail changes, such as onychodystrophy or onycholysis.<sup>2</sup> Subungual hemorrhage has been reported as a side effect of taxanes, anticoagulants, anthracyclines, anti-inflammatory agents, and retinoids.<sup>4,5</sup>

The pathogenesis of nail toxicity secondary to EGFR inhibitors is not entirely clear. Symptoms commonly occur several weeks to months after therapy initiation.<sup>6</sup> Epidermal growth factor receptor inhibitors disrupt proliferation and promote apoptosis of keratinocytes that is thought to enhance fragility of the periungual skin and nail plate.<sup>1,3</sup> Under the influence of EGFR inhibition, a proinflammatory microenvironment in the skin is created through a type I interferon response leading to tissue damage.<sup>7</sup> These changes may predispose patients to develop subungual hemorrhage in response to repeated nail microtrauma. Subungual asymptomatic splinter hemorrhage is a nail finding described in patients treated

From the University of Iowa Hospitals and Clinics, Iowa City. Drs. Hammel and Ferguson are from the Department of Dermatology. The authors report no conflict of interest.

Correspondence: Nkanyezi N. Ferguson, MD, Department of Dermatology, University of Iowa Hospitals and Clinics, Room 40039 PFP, 200 Hawkins Dr, Iowa City, IA 52246 (nkanyezi-ferguson@uiowa.edu).



A, Violaceous discoloration of the thumbnails consistent with subungual hemorrhage. B, An expanded view of the left thumbnail showed no evidence of periungual changes or nail aberrations.

with the multikinase inhibitors sorafenib and sunitinib. Splinter hemorrhages of the nails are thought to be secondary to capillary microinjuries of the digits that cannot be repaired due to inhibition of vascular EGFRs.<sup>4</sup>

The time course of erlotinib administration and the simultaneous onset of xeroderma, a known side effect of the drug, in our patient are consistent with other cases.<sup>6</sup>

Subungual hemorrhage, which the patient reported observing only days after the onset of xeroderma, provides increased support that the anti-EGFR medication was likely responsible for both side effects concurrently. Bilateral involvement of the thumbs makes trauma as an inciting event unlikely.

Management of subungual hemorrhage depends on the grade of toxicity and degree in which symptoms interfere with quality of life. Acute management includes supportive care with consideration for nail trephination only as clinically indicated. Preventative measures should be encouraged including avoidance of nail trauma. Interrupting drug therapy for nail toxicity generally is discouraged given the likely need for prolonged duration of interruption due to the long half-life of EGFR inhibitors and overall slow nail growth.<sup>2</sup>

Incidence of nail changes secondary to anti-EGFR drugs are likely underestimated and underreported.<sup>3</sup> Subungual hemorrhage should be considered as an additional, less common nail side effect of EGFR inhibitors that clinicians and patients may encounter. Improved awareness and understanding of nail toxicities associated with EGFR inhibitors may offer better insight into the pathogenesis of these side effects and management options.

#### REFERENCES

1. Piraccini BM, Alessandrini A. Drug-related nail disease. *Clin Dermatol.* 2013;31:618-626.
2. Kiyohara Y, Yamazaki N, Kishi A. Erlotinib-related skin toxicities: treatment strategies in patients with metastatic non-small cell lung cancer. *J Am Acad Dermatol.* 2013;69:463-472.
3. Minisini AM, Tosti A, Sobrero AF, et al. Taxane-induced nail changes: incidence, clinical presentation and outcome. *Ann Oncol.* 2003;333-337.
4. Garden BC, Wu S, Lacouture ME. The risk of nail changes with epidermal growth factor receptor inhibitors: a systematic review of the literature and meta-analysis. *J Am Acad Dermatol.* 2012;67:400-408.
5. Fox LP. Nail toxicity associated with epidermal growth factor receptor inhibitor therapy. *J Am Acad Dermatol.* 2007;56:460-465.
6. Chen KL, Lin CC, Cho YT, et al. Comparison of skin toxic effects associated with gefitinib, erlotinib or afatinib treatment for non-small cell lung cancer. *JAMA Dermatol.* 2016;152:340-342.
7. Lulli D, Carbone ML, Pastore S. Epidermal growth factor receptor inhibitors trigger a type I interferon response in human skin. *Oncotarget.* 2016;7:47777-47793.