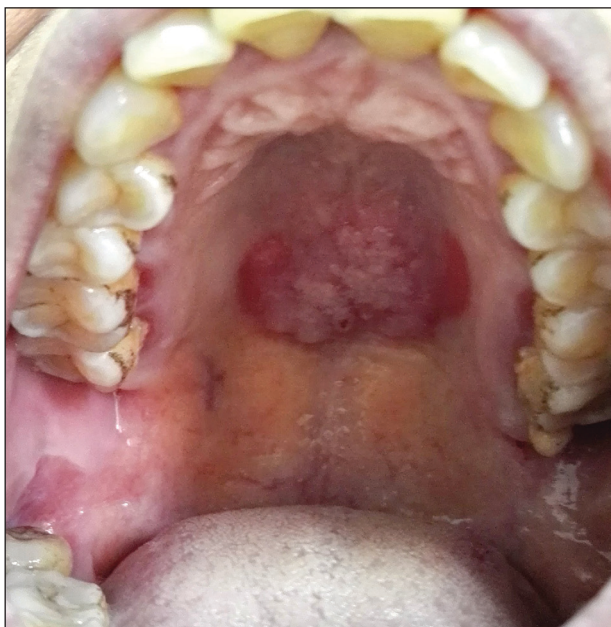

Solitary Warty Mucosal Lesion on the Hard Palate

Wei Cai, MD; Jun Chen, MD; Zhengqiu Huang, MD; Xiaomo Wu, PhD



A 50-year-old Chinese woman presented with a painless, well-demarcated, nontender, elevated, flat-topped verrucous plaque on the hard palate of 1 month's duration. The lesion measured 2 cm in diameter. The patient reported no other dermatologic or systemic concerns, and no other skin or genital lesions were observed.

WHAT'S THE DIAGNOSIS?

- a. cavernous hemangioma
- b. condyloma acuminatum
- c. granulomatosis with polyangiitis
- d. oral squamous cell carcinoma
- e. solitary oral condyloma lata of secondary syphilis

PLEASE TURN TO [PAGE E29](#) FOR THE DIAGNOSIS

From the Dermatology Institute of Fuzhou, Dermatology Hospital of Fuzhou, Fujian, China.

The authors report no conflict of interest.

This work was supported by the key Clinical Specialty Discipline Construction Program of Fuzhou, Fujian, China (Grant No. 201807111).

Correspondence: Xiaomo Wu, PhD, Dermatology Institute of Fuzhou, Dermatology Hospital of Fuzhou, Xihong Rd 243, Fuzhou 350025, China (Xiaomo.Wu@gmail.com).

THE DIAGNOSIS:

Solitary Oral Condyloma Lata of Secondary Syphilis

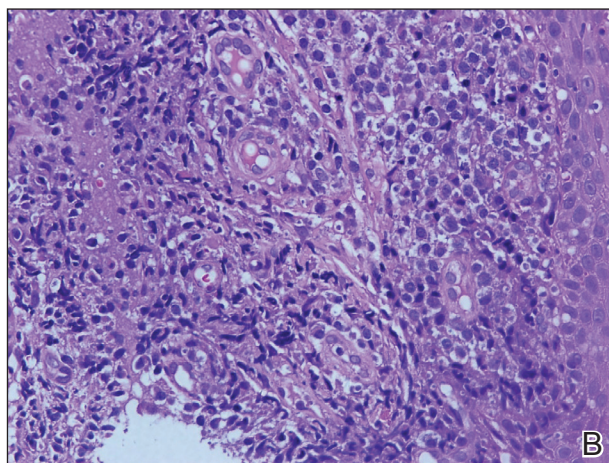
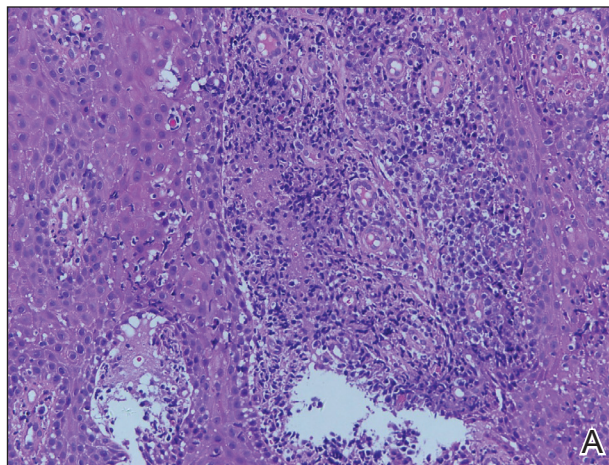
A punch biopsy of the lesion revealed acanthosis with elongation of rete ridges; interface dermatitis; and a moderately dense, predominantly lymphoid dermal infiltration (Figure). Based on a serologic toluidine red unheated serum test (TRUST) titer of 1:64 and positive *Treponema* antibodies, a diagnosis of secondary syphilitic infection was made. A test for human immunodeficiency virus infection was negative, and the patient was not immunocompromised. Due to allergy to benzathine penicillin G, she was prescribed oral minocycline 100 mg twice daily for 15 days. (See the Table for current recommended regimens from the Centers for Disease Control and Prevention for the treatment of syphilis.¹) The hard palate plaque began to fade after 2 days of treatment and completely regressed 2 weeks later. The TRUST titer decreased to 1:4 after 6 months.

The patient's husband was examined following confirmation of his wife's infection; his TRUST titer was 1:64 and *Treponema* antibodies were positive. No skin lesions were detected. A test for human immunodeficiency virus infection also was negative. Further inquiry revealed that he had had sexual intercourse with a prostitute about 3 months prior. He was diagnosed with latent syphilis and prescribed the same medication regimen as his wife. However, after 6 months, his TRUST titer was still 1:64, possibly due to irregular medication use.

Secondary syphilis often is preceded by flulike symptoms of fever, sore throat, headache, malaise, generalized painless lymphadenopathy, and myalgia 4 to 10 weeks after onset of infection.²⁻⁵ Condyloma lata can be one of the characteristic mucosal signs of secondary syphilis; however, it is typically located in the anogenital area or less commonly in atypical areas such as the umbilicus, axillae, inframammary folds, and toe web spaces.⁶ Condyloma lata in the oral cavity is rare. In fact, this unusual manifestation prompted the patient to suspect cancer and she initially presented to a local tumor hospital. However, oral computed tomography did not detect any tumor cells, and subsequent testing yielded the diagnosis of secondary syphilis.

The differential diagnosis for a warty oral mass includes squamous cell carcinoma, condyloma acuminatum, oral submucous fibrosis, and Wegener granulomatosis.

Similar to other nontreponemal tests, TRUST is a flocculation-based quantitative test that can be used to follow treatment response, as its antibody titers may correlate with disease activity.⁷ Clinically, a 4-fold change in titer (equivalent to a change of 2 dilutions) is considered necessary to demonstrate a notable difference between 2 nontreponemal test results obtained using the same serologic



A, Biopsy revealed papillary hyperplasia of squamous epithelium (H&E, original magnification $\times 200$). B, Interstitial infiltration with a large number of lymphocytes in the presence of vascular proliferation was observed (H&E, original magnification $\times 400$).

test. The TRUST titers for the case patient decreased from 1:64 to 1:4, indicating a good response to minocycline. In contrast, the TRUST of her husband remained as high at 6-month follow-up as it had been at initial examination. This serofast state was most likely related to his irregular medication use; however, other possibilities should be considered, including confounding nontreponemal inflammatory conditions in the host, the variability of host response to infection, or even persistent low-level infection with *Treponema pallidum*.⁸ Because treponemal antibodies typically remain positive for life and most patients who have a reactive treponemal test will have a reactive report for the remainder of their lives, regardless of treatment or

Treatment Guidelines for Syphilis

Stage of Syphilis	Treatment Regimen
Primary/secondary	2.4 million U benzathine penicillin G IM single dose
Early latent <1 y	2.4 million U benzathine penicillin G IM single dose
Latent >1 y or latent of unknown duration	2.4 million U benzathine penicillin G IM at 1-wk intervals for 3 wk (7.2 million U total)
Tertiary with normal CSF examination	2.4 million U benzathine penicillin G IM at 1-wk intervals for 3 wk (7.2 million U total)
Neurosyphilis	Aqueous crystalline penicillin G 18–24 million U/d for 10–14 d administered as 3–4 million U IV every 4 h or continuous IV; procaine penicillin G 2.4 million U IM once daily, plus probenecid 500 mg orally 4 times daily for 10–14 d
Pregnant women	Penicillin regimen appropriate for the stage of syphilis ^a
Penicillin allergy (primary/secondary)	Doxycycline 100 mg orally twice daily for 14 d; tetracycline 500 mg 4 times daily for 14 d; ceftriaxone 1–2 g/d either IM or IV for 10–14 d; azithromycin as a single 2-g oral dose ^b
Penicillin allergy (latent)	Doxycycline 100 mg orally twice daily for 28 d; tetracycline 500 mg orally 4 times daily for 28 d

Abbreviations: IM, intramuscular; CSF, cerebrospinal fluid; IV, intravenous.

^aDesensitization can be safely performed in pregnancy and pregnant woman allergic to penicillin should be desensitized before the treatment.

^bAzithromycin should not be used as first-line treatment of syphilis and should be used with caution only when treatment with penicillin or doxycycline is not feasible.

Data from the Centers for Disease Control and Prevention.¹

disease activity, treponemal antibody titers should not be used to monitor treatment response.⁹

China has experienced a resurgence in the incidence and prevalence of syphilis in recent decades. According to the national reporting database, the annual rate of syphilis in China has increased 14.3% since 2009 (6.5 cases per 100,000 population in 1999 vs 24.66 cases per 100,000 population in 2009).¹⁰ This re-emergence is truly remarkable, given this infection was virtually eradicated in the country 60 years ago. Recognizing this syphilis epidemic as a public health threat, the Ministry of Health of the People's Republic of China in 2010 announced a 10-year plan for syphilis control and prevention to curb the spread of syphilis and other sexually transmitted diseases. Currently, the syphilis burden is still great, with 25.54 cases per 100,000 population in 2016,¹¹ but the situation has been stabilized and the annual increase is less than 1% since the plan's introduction.

Globally, there has been a marked resurgence of syphilis in the last decade, largely attributed to changing social and behavioral factors, especially among the population of men who have sex with men. Despite the availability of effective treatments and previously reliable prevention strategies, there are an estimated

6 million new cases of syphilis in those aged 15 to 49 years, and congenital syphilis causes more than 300,000 fetal and neonatal deaths each year.¹² Continued vigilance and investment is needed to combat syphilis worldwide, and recognition of syphilis, with its versatile presentations, is of vital importance today.¹³

The presentation of secondary syphilis can be highly variable and requires a high level of awareness.^{4–6} Solitary oral involvement in secondary syphilis is rare and can lead to misdiagnosis; therefore, a high level of suspicion for syphilis should be maintained when evaluating oral lesions.

REFERENCES

- Centers for Disease Control and Prevention. 2015 Sexually Transmitted Diseases Treatment Guidelines: *Syphilis*. <https://www.cdc.gov/std/tg2015/syphilis.htm>. Accessed March 25, 2020.
- Lombardo J, Alhashim M. Secondary syphilis: an atypical presentation complicated by a false negative rapid plasma reagin test. *Cutis*. 2018;101:E11–E13.
- Brown DL, Frank JE. Diagnosis and management of syphilis. *Am Fam Physician*. 2003;68:283–290.
- Dourmishev LA, Assen L. Syphilis: uncommon presentations in adults. *Clin Dermatol*. 2005;23:555–564.
- Martin DH, Mroczkowski TF. Dermatological manifestations of sexually transmitted diseases other than HIV. *Infect Dis Clin North Am*. 1994;8:533–583.

6. Liu Z, Wang L, Zhang G, et al. Warty mucosal lesions: oral condyloma lata of secondary syphilis. *Indian J Dermatol Venereol Leprol.* 2017;83:277.
7. Morshed MG, Singh AE. Recent trends in the serologic diagnosis of syphilis. *Clin Vaccine Immunol.* 2015;22:137-147.
8. Seña AC, Wolff M, Behets F, et al. Response to therapy following retreatment of serofast early syphilis patients with benzathine penicillin. *Clin Infect Dis.* 2013;56:420-422.
9. Rhoads DD, Genzen JR, Bashleben CP, et al. Prevalence of traditional and reverse-algorithm syphilis screening in laboratory practice: a survey of participants in the College of American Pathologists syphilis serology proficiency testing program. *Arch Pathol Lab Med.* 2017;141:93-97.
10. Tucker JD, Cohen MS. China's syphilis epidemic: epidemiology, proximate determinants of spread, and control responses. *Curr Opin Infect Dis.* 2011;24:50-55.
11. Yang S, Wu J, Ding C, et al. Epidemiological features of and changes in incidence of infectious diseases in China in the first decade after the SARS outbreak: an observational trend study. *Lancet Infect Dis.* 2016;17:716-725.
12. Noah K, Jeffrey DK. An update on the global epidemiology of syphilis. *Curr Epidemiol Rep.* 2018;5:24-38.
13. Ghanem KG, Ram S, Rice PA. The modern epidemic of syphilis. *N Engl J Med.* 2020;382:845-854.