

What's Eating You?

Megalopyge opercularis

Melba Estrella, MD; Dirk M. Elston, MD

PRACTICE POINTS

- *Megalopyge opercularis* is the most widely distributed caterpillar species in the Americas, and envenomation by it can occur year-round.
- Skin reactions to *M opercularis* stings can present as maculopapular dermatitis, eczematous eruptions, or urticarial reactions.
- During the initial presentation, patients experience intense throbbing pain, yet the severity of symptoms depends on the caterpillar's size and the extent of contact.
- A history of caterpillar exposure helps with diagnosis, and treatment remains empiric.

Caterpillars—the larval form of butterflies and moths—belong to the order Lepidoptera. Some identified caterpillars from this order have developed venomous defense mechanisms such as irritating hairs and spines to protect themselves from predators. Direct contact to allergenic caterpillars' hairs can cause human disease. Cutaneous lesions following caterpillar envenomation can range from mild localized inflammatory signs and pain to a worsening appearance of vesicles, bullae, erosions, petechiae, necrosis, and ulceration. This review addresses the varied general manifestations caused by venomous lepidopteran exposure with special focus on the adverse cutaneous manifestations and therapeutic options of *Megalopyge opercularis*, the caterpillar of the flannel moth.

Cutis. 2020;106:23-24, 27.

Lepidoptera is the second largest order of the class Insecta and comprises approximately 160,000 species of butterflies and moths classified among approximately 124 families and subfamilies. Venomous properties have been identified in 12 of these families, posing a serious threat to human health.¹

The clinical manifestations from Lepidoptera envenomation can range from general systemic symptoms such as fever and abdominal distress; to more complex focal affections including hemorrhage, ophthalmologic

lesions, and irritation of the respiratory tracts; to less severe reactions of the skin, which are the most common presentation.¹

Terminology

Lepidopterism is the term used to address a clinical spectrum of systemic manifestations from direct contact with venomous butterflies or moths and/or their products.² Conversely, *erucism* is a term used to describe localized cutaneous reactions after direct contact with toxins from caterpillars.

Lepidopterism is derived from the Greek roots *lepis*, meaning scale, and *pteron*, meaning wing. The term *erucism* stems from the Latin word *eruca*, which means larva.²

Ideally, lepidopterism should refer solely to reactions from butterflies and moths—adult forms of insects with scaly wings—while erucism should refer to reactions from contact with caterpillars—the larval form of butterflies and moths.

In common use, lepidopterism can describe any reaction from caterpillars, moths, or adult butterflies, as well as any case of Lepidoptera exposure with only systemic manifestations, regardless of cutaneous findings. Concurrently, erucism has been defined as either any reaction from caterpillars or any skin reaction from contact with caterpillars or moths.²

Because caterpillars are the larval form of butterflies and moths, caterpillar-associated skin reactions also have been conveniently denominated *caterpillar dermatitis*.¹ Henceforth in this article, both terms *erucism* and *caterpillar dermatitis* are used interchangeably.

Caterpillar Envenomation

Caterpillars cause the vast majority of adverse events from lepidopteran exposures.² Envenomation by caterpillars might stand as the world's most common envenomation given the larvae proximity to humans.³ Although involvement of internal organs (eg, renal failure), cerebral hemorrhage, and joint lesions can occur, skin manifestations are more predominant with the majority of species. Initial

From the Department of Dermatology and Dermatologic Surgery, Medical University of South Carolina, Charleston.

The authors report no conflict of interest.

The images are in the public domain.

Correspondence: Melba Estrella, MD, Rutledge Tower, 135 Rutledge Ave, Charleston SC 29425 (estrelme@musc.edu).

localized pain, edema, and erythema usually are present at the site of direct contact and subsequently progress toward maculopapular to bullous lesions, erosions, petechiae, necrosis, and ulceration depending on the offending species.^{1,4}

Megalopyge opercularis

In the United States, more than 50 species of caterpillars have been identified as poisonous or venomous.⁵ *Megalopyge opercularis* (Figure 1), the larval form of the flannel moth, is an important cause of caterpillar-associated dermatitis in the southern United States.^{6,7} *Megalopyge opercularis* also is commonly known as the puss caterpillar, opossum bug, wooly slug, el perrito, tree asp, or Italian asp.⁶ This lepidopteran insect is mainly found in the southeastern and southcentral United States, with noted particular abundance in Texas, Louisiana, and Florida.^{6,8} The puss caterpillar has 2 generations per year; the first develops during the months of June to July, and the second develops from September to October, carrying seasonal health hazards.^{6,8}

Megalopyge opercularis is tapered at the ends and can measure 2.5 to 3.5×1 cm at maturity. It is covered by silky, long-streaked, wavy hairs that may appear single colored or as a mix of colors—from white to gray to brown—forming a mid-dorsal crest.⁶ Beneath this furry coat, rows of short sharp spines are hidden. Upon contact with the human skin, these spines will break and discharge venom.^{1,6,8} Toxins contained within the hollow spines are thought to be produced by specialized basal cells, but there still is little knowledge about the dynamics and composition of the venom.¹




FIGURE 1. A and B, Larval stage of *Megalopyge opercularis*.

Clinical Manifestations

The severity of the reaction depends on the caterpillar's size and the extent of contact.^{1,4} Contact with *M opercularis* instantly presents with a throbbing or burning pain that may be followed by localized erythema and rash.^{1,6} A characteristic gridlike pattern of erythematous macules develops, reflecting each site of puncture from the insect's spines (Figure 2).^{8,9} Skin lesions can progress from erythematous macules to hemorrhagic vesicles or pustules, usually self-resolving after a few days. The reaction also can present with radiating pain to regional lymph nodes and numbness of the affected area.^{1,6,8} Moreover, some patients may report urticaria and pruritus.⁹

Envenomation by a puss caterpillar also can present with systemic manifestations including fever, headache, nausea, vomiting, shocklike symptoms, and seizures.^{1,6,7} Anaphylactic reaction is rare but also can present.⁷ Uncommon cases have been reported with severe abdominal pain and muscle spasm mimicking acute appendicitis and latrodectism, respectively.^{7,9}

Diagnosis

The diagnosis of *M opercularis* envenomation is made clinically based on the morphology of the skin lesions and a history of probable exposure. Coexistent leukocytosis is likely, but laboratory testing is not warranted, as it is both nonspecific and insensitive.⁹

Management/Treatment

The most commonly reported immediate approaches to treatment involve attempts to remove the spines from the skin with tape (stripping), application of ice packs over the affected area, oral antihistamines, topical and intralesional anesthetics, regional nerve block, and oral analgesics.^{6,9} There have been several cases detailing the successful use of parenteral calcium gluconate,^{5,7} and diazepam has been used to treat severe muscle spasms. Anaphylactic reactions should be managed in a controlled monitored setting

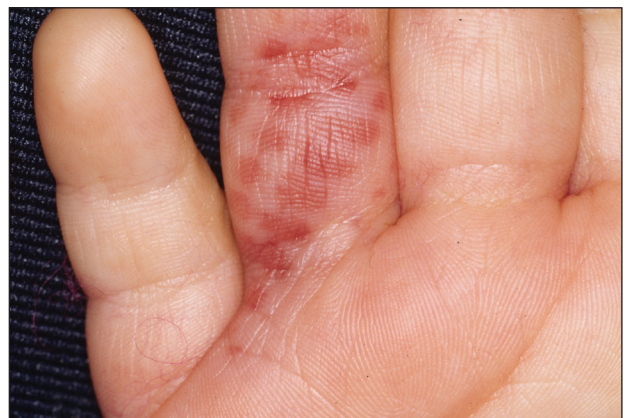

FIGURE 2. Gridlike pattern of hemorrhagic papules and crusts on the palmar aspect of the right hand following *Megalopyge opercularis* envenomation.

CONTINUED ON PAGE 27

CONTINUED FROM PAGE 24

with subcutaneous epinephrine.⁷ Despite their common use, some data suggest that ice packs and mid- to high-potency topical steroids are ineffective.⁹

Incidence

From 2001 to 2005, a mean average of 94,552 annual cases of animal bites and stings were reported to poison control centers in the United States, of which 2094 were linked to caterpillars in this 5-year period.¹⁰ There were 3484 *M opercularis* caterpillar stings reported to the Texas Poison Center Network from 2000 to 2016.^{5,6} Given their ability to sting throughout their life cycle, thousands of *M opercularis* caterpillar stings can occur each year.^{1,6} Existing literature on *M opercularis* caterpillar stings mainly involves case reports with affections of the skin and oral mucosa, self-reported envenomation, and case studies.^{5,6,8}

Although multiple health concerns associated with caterpillar envenomation have been reported worldwide, the lack of official epidemiologic reports highly suggests that this problem remains underestimated. There also may be many unreported cases because certain reactions are mild or self-limited and can even go unnoticed.¹¹ Nonetheless, there is an evident rise of cases reported in the United States. According to the 2018 annual report of the American Association of Poison Control Centers, there were 2815 case mentions from caterpillar envenomation.¹²

In 1921 and 1952, some public schools in Texas were temporarily closed due to outbreaks of puss caterpillar-associated dermatitis.⁸ Similar outbreaks also have been reported in South Carolina, Virginia, and Oklahoma.⁹ Emerging data suggest that plant oil products and the

pesticide cypermethrin may be helpful in controlling local infestations of the puss caterpillar.⁸

REFERENCES

1. Villas-Boas IM, Bonfa G, Tambourgi DV. Venomous caterpillars: from inoculation apparatus to venom composition and envenomation. *Toxicon*. 2018;153:39-52.
2. Hossler EW. Caterpillars and moths: part I. dermatologic manifestations of encounters with Lepidoptera. *J Am Acad Dermatol*. 2010;62:1-10; quiz 11-12.
3. Haddad Junior V, Amorim PC, Haddad Junior WT, et al. Venomous and poisonous arthropods: identification, clinical manifestations of envenomation, and treatments used in human injuries. *Rev Soc Bras Med Trop*. 2015;48:650-657.
4. Haddad V Jr, Cardoso JL, Lupi O, et al. Tropical dermatology: venomous arthropods and human skin: part I. Insecta. *J Am Acad Dermatol*. 2012;67:331.e1-331.e14; quiz 345.
5. Pappano DA, Trout Fryxell R, Warren M. Oral mucosal envenomation of an infant by a puss caterpillar. *Pediatr Emerg Care*. 2017;33:424-426.
6. Forrester MB. *Megalopyge opercularis* caterpillar stings reported to Texas poison centers. *Wilderness Environ Med*. 2018;29:215-220.
7. Hossler EW. Caterpillars and moths: part II. dermatologic manifestations of encounters with Lepidoptera. *J Am Acad Dermatol*. 2010;62:13-28; quiz 29-30.
8. Eagleman DM. Envenomation by the asp caterpillar (*Megalopyge opercularis*). *Clin Toxicol (Phila)*. 2008;46:201-205.
9. Greene SC, Carey JM. Puss caterpillar envenomation: erucism mimicking appendicitis in a young child [published online May 23, 2018]. *Pediatr Emerg Care*. doi:10.1097/PEC.0000000000001514.
10. Langley RL. Animal bites and stings reported by United States Poison Control Centers, 2001-2005. *Wilderness Environ Med*. 2008;19:7-14.
11. Seldeslachts A, Peigneur S, Tytgat J. Caterpillar venom: a health hazard of the 21st century [published online May 30, 2020]. *Biomedicines*. doi:10.3390/biomedicines8060143.
12. Gummin DD, Mowry JB, Spyker DA, et al. 2018 annual report of the American Association of Poison Control Centers' National Poison Data System (NPDS): 36th annual report. *Clin Toxicol (Phila)*. 2019;57:1220-1413.