

# Dystrophic Calcinosis Cutis: Treatment With Intravenous Sodium Thiosulfate

Ahmed H. Badawi, MD, PhD; Vikas Patel, MD; Ann E. Warner, MD; John C. Hall, MD

## PRACTICE POINTS

- Dystrophic calcinosis cutis is a potentially debilitating condition with limited effective therapies.
- Consider intravenous sodium thiosulfate in patients with diffuse and severe dystrophic calcinosis cutis.

To the Editor:

Severe dystrophic calcinosis cutis is a debilitating disease with no universally accepted therapeutic options. This case demonstrates the benefit of intravenous (IV) sodium thiosulfate in alleviating the calcified lesions as well as the associated pain and disability. This application of IV sodium thiosulfate with a favorable outcome is new and should be considered for the treatment of generalized dystrophic calcinosis cutis, especially when topical, procedural, or surgical options are not feasible.

A 54-year-old woman with a history of well-controlled dermatomyositis and systemic lupus erythematosus presented with diffuse, hard, calcified lesions on the legs, arms, clavicular region, and neck that had slowly progressed over at least a 10-year period (Figure 1). The lesions were consistent with dystrophic calcinosis cutis. The patient was started on 12.5 g of IV sodium thiosulfate 3 times weekly infused over 30 minutes. Drastic diminution of the cutaneous calcification was observed at 3-month follow-up (Figure 2). She reported decreased pain and burning as well as increased overall functionality and improved sleep. The patient completed 8 months of therapy, but the treatment was

stopped secondary to suspicion of a lupuslike flare, and the lesions recurred with more widespread involvement, including the trunk, tendons, bony prominences, and supraclavicular soft tissue. The patient reported burning pain and pruritus that resulted in impairment of daily activities such as getting dressed. Sodium thiosulfate was restarted once weekly, which again resulted in reduction of the dystrophic calcinosis cutis.

Dystrophic calcinosis cutis is a debilitating disease that results in considerable morbidity and pain with major implications on quality of life. The pathophysiology is unclear; calcium and phosphate serum levels generally are normal. A proposed mechanism is that chronic inflammation causes tissue damage and defective collagen synthesis, resulting in a distorted architecture that facilitates calcium deposition in the skin and subcutaneous tissues.<sup>1</sup> Dystrophic calcinosis cutis most commonly is associated with systemic sclerosis and dermatomyositis but also can be seen in systemic lupus erythematosus, panniculitis, and other connective tissue diseases. It also can occur with skin neoplasms, collagen and elastin disorders, porphyria cutanea tarda, and pancreatic panniculitis.<sup>1</sup> Progression of dystrophic calcinosis cutis usually is independent of the associated disease status.

Treatment is based on anecdotal evidence from case reports, as there is no universally accepted pharmacologic or procedural intervention available for dystrophic calcinosis cutis. Medications that have been reported to be helpful to varying degrees include diltiazem, colchicine, minocycline, IV immunoglobulin, ceftriaxone, aluminum hydroxide, probenecid, alendronic acid, etidronate disodium, warfarin, intralesional corticosteroids,

Dr. Badawi is from the School of Medicine and Dr. Patel is from the Division of Dermatology, University of Kansas Medical Center, Kansas City.

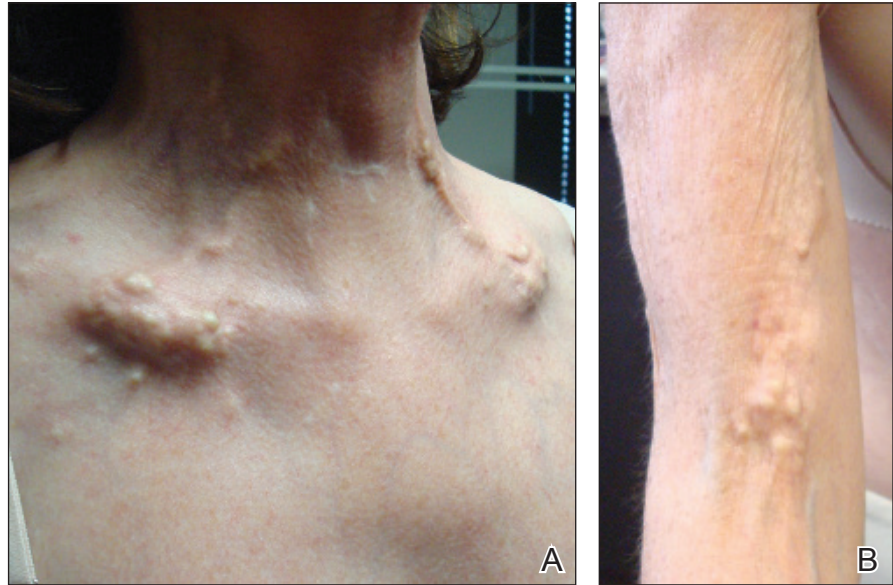Dr. Warner is from the Center for Rheumatic Disease and Dr. Hall is from the Division of Dermatology, Saint Luke's Hospital, Kansas City, Missouri.

The authors report no conflict of interest.

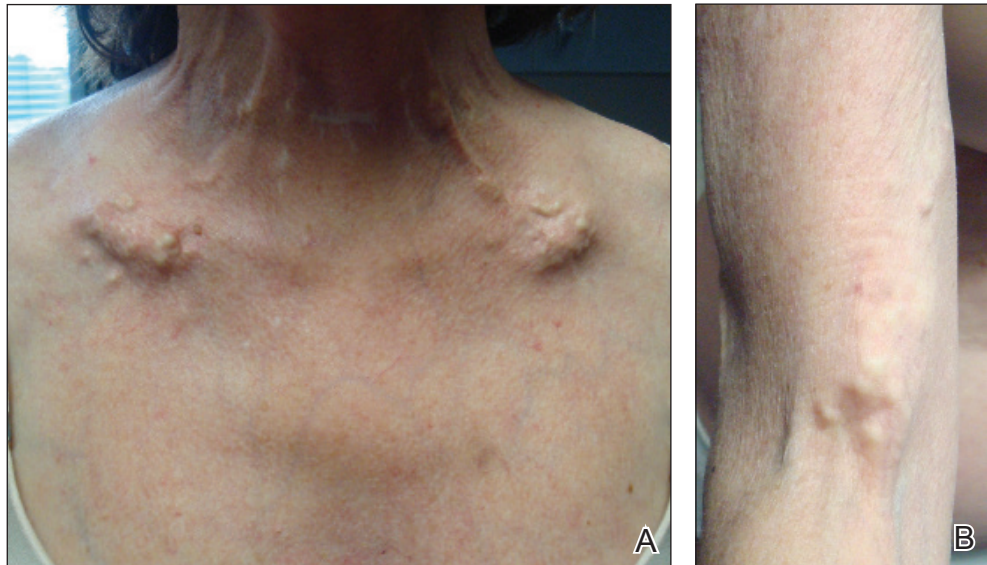
Correspondence: Vikas Patel, MD, 3901 Rainbow Blvd, Kansas City, KS 66160 (vipatel89@yahoo.com).

doi:10.12788/cutis.0071

**FIGURE 1.** A, Cutaneous and subcutaneous, tender, painful calcium deposits over the clavicular region and on the neck. White papules and tumors stretched the skin taut. B, Nodular white calcium deposits in the antecubital fossa made it painful for the patient to fully extend the arms.



**FIGURE 2.** A, After only 3 months of intravenous sodium thiosulfate 12.5 mg 3 times weekly, reduced thickness of the calcium deposits over the clavicular region and on the neck was noted, with some of the smaller deposits almost completely cleared. B, The same improvement also was noted in the antecubital fossa.



and sodium thiosulfate. Procedural interventions also have been reported, such as surgical excision, extracorporeal shock wave lithotripsy, and CO<sub>2</sub> and erbium:YAG lasers.<sup>1</sup> Surgical excision of dystrophic calcinosis cutis is widely implemented but outcomes are poor. Moreover, in patients with widely diffuse calcinosis, targeted procedural therapy is impractical.

Intravenous sodium thiosulfate has been widely used for the treatment of calciphylaxis secondary to end-stage renal failure and tumoral calcinosis.<sup>2</sup> It also has been reported to be effective in iatrogenic calcinosis cutis secondary to extravasation of calcium-containing solutions in a patient with T-cell acute lymphoblastic leukemia.<sup>3</sup> However, reports of its use in treating dystrophic calcinosis cutis are limited. Intravenous sodium thiosulfate—10 g 3 times weekly for 2 weeks, followed by 15 g twice

weekly for the next 3 months—was used with abatacept for treatment of dystrophic calcinosis cutis in a patient with juvenile dermatomyositis.<sup>4</sup> Other formulations of sodium thiosulfate have been reported to result in clearance of calcified lesions, including a topical application compounded in zinc oxide<sup>5</sup> and intradermal injection at the base of a nodule.<sup>6</sup> We used 12.5 g over 30 minutes 3 times weekly; however, the dose can be increased to 25 g over 60 minutes if 3 to 4 treatments are tolerated, with nausea being the only notable side effect. Its mechanism of action in treating dystrophic calcinosis cutis is unclear, but it likely is due to its ability to chelate and dissolve calcium deposits. Topical and intradermal therapy is impractical for widespread, dystrophic calcinosis cutis as in our patient.

Our case highlights the successful use of IV sodium thiosulfate as a stand-alone treatment modality for

generalized dystrophic calcinosis cutis in an adult patient. Both our patient and a child in a previously reported case who received the same treatment<sup>4</sup> had dermatomyositis, but we suspect IV sodium thiosulfate also may be effective for dystrophic calcinosis cutis associated with other diseases. Sodium thiosulfate should be considered as a treatment for patients who experience tremendous pain and disability. It is safe, inexpensive, and easy to administer and is especially helpful in patients for whom topical, intradermal, or procedural therapy is not possible.

#### REFERENCES

1. Gutierrez A Jr, Wetter DA. Calcinosis cutis in autoimmune connective tissue diseases. *Dermatol Ther*. 2012;25:195-206.
2. Mageau A, Guignon V, Ratzimbasafy V, et al. Intravenous sodium thiosulfate for treating tumoral calcinosis associated with systemic disorders: report of four cases. *Joint Bone Spine*. 2017;84:341-344.
3. Raffaella C, Annapaola C, Tullio I, et al. Successful treatment of severe iatrogenic calcinosis cutis with intravenous sodium thiosulfate in a child affected by T-acute lymphoblastic leukemia. *Pediatr Dermatol*. 2009;26:311-315.
4. Arabshahi B, Silverman RA, Jones OY, et al. Abatacept and sodium thiosulfate for treatment of recalcitrant juvenile dermatomyositis complicated by ulceration and calcinosis. *J Pediatrics*. 2012;160:520-522.
5. Bair B, Fivenson D. A novel treatment for ulcerative calcinosis cutis. *J Drugs Dermatol*. 2011;10:1042-1044.
6. Smith GP. Intradermal sodium thiosulfate for exophytic calcinosis cutis of connective tissue disease. *J Am Acad Dermatol*. 2013;69:E146-E147.