

# 24-7 Dressing Technique to Optimize Wound Healing After Mohs Micrographic Surgery

Alexandra Edelman, MD; Megan Foley, BS; Michael McCall Jr, MD

Postoperative wound care can be troublesome, time consuming, and expensive. Patients often are unable to personally take proper care of their wounds at home, leading to complications. We describe the use of a comfortable, effective, and simple technique for wound dressings after dermatologic surgery in patients who are vulnerable to wound complications.

*Cutis.* 2021;107:149-150.

## Practice Gap

Management of surgical wounds is a critical component of postsurgical care for patients during recovery at home.<sup>1</sup> However, postoperative wound care can be troublesome, time consuming, and expensive. Common problems with current standard dressings include an increased risk for infection, pain, and wound damage with frequent dressing changes.<sup>2-4</sup>

Patients often are unable to take proper care of wounds themselves and may not have the financial means or social support to have others assist them.<sup>4-6</sup> For these patients, the option of a hassle-free dressing that they can leave on until their follow-up appointment is preferred. In our experience, what we call a 24-7 bandage has been remarkably successful in patients who are vulnerable to wound complications.

We report a comfortable, effective, and simple technique for wound dressings after dermatologic surgery.

## The Technique

In Figure 1, we demonstrate a simple dressing technique that can be used to optimize wound healing in patients unable to provide adequate wound care for themselves:

1. The surgical site is covered with mupirocin ointment, followed by bismuth tribromophenate gauze (Figure 1A). The bismuth-impregnated gauze helps make the dress-

ing nonadherent and moderately occlusive. It also adds moisture to the wound bed.

2. The gauze is then covered with excess mupirocin. A nonadherent dressing is applied (Figure 1B).

3. The entire area is covered with gauze and cover-roll nonlatex bandaging tape to ensure maximum adhesion (Figures 1C and 1D).

4. When the surgical site is on an extremity, it is wrapped in a self-adherent wrap or bandage roll to prevent clothing from pulling the tape loose.

Once this dressing technique is performed in the office, the bandage requires no wound care at home other than ensuring that the bandage is kept dry. The 24-7 dressing can be left on the surgical site for 7 days until the follow-up appointment. If necessary, it also can be applied for a second week after bolster removal or for multiple weeks following advanced flap repair.

Our patients find this dressing comfortable and unobtrusive. It is easy for the staff to apply and inexpensive.

## Practical Implications

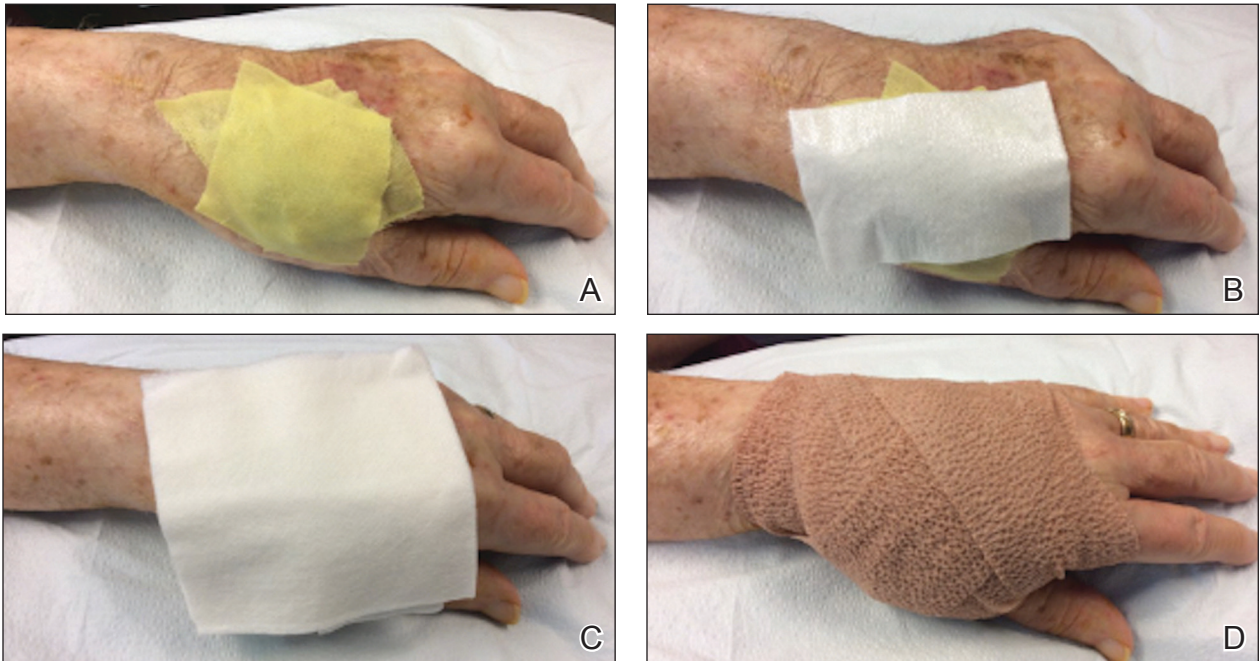
We have treated approximately 200 patients with the 24-7 dressing technique. Our experience is that these patients demonstrated an excellent aesthetic outcome without complications (Figure 2). We have successfully utilized the dressing in several anatomic locations, including the arms, legs, neck, face, and scalp. We use mupirocin for its antimicrobial activity, but we have not performed a study at our clinic looking at the difference between rate of infection and wound healing using mupirocin vs petrolatum. We prefer adding bulk gauze under the tape and leaving the dressing on for 7 days. We seldom have issues with bleeding, and if there is an issue, the patient is told to come back to our clinic so we can change the bandage for them.

From the Division of Dermatology, University of Louisville School of Medicine, Kentucky.

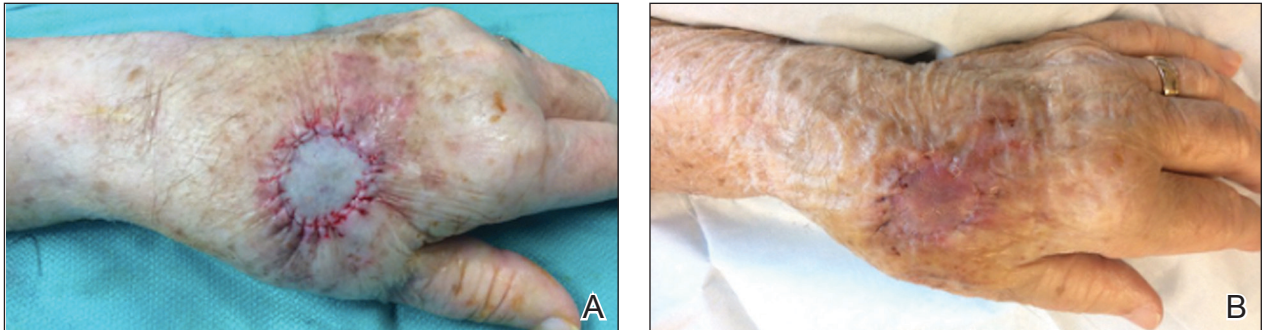
The authors report no conflict of interest.

Correspondence: Alexandra Edelman, MD, 3810 Springhurst Blvd, Ste 200, Louisville, KY 40241 (abbars02@louisville.edu).

doi:10.12788/cutis.0201



**FIGURE 1.** Wound care using a 24-7 dressing. A, Mupirocin is applied to the entire graft site, which is then covered with bismuth tribromophenolate gauze. B, A nonadherent dressing is applied over the bismuth tribromophenolate gauze. C, Gauze loosely covers the bandaged areas to provide more padding. D, The entire hand is wrapped in a self-adherent wrap or bandage roll to hold the bandaging in place.



**FIGURE 2.** A, Postsurgical repair using a full-thickness skin graft on the hand. B, The 24-7 dressing was removed 1 week postoperatively with an excellent cosmetic outcome.

This dressing technique is cost-effective to the patient and clinical staff, provides protection from potential injury to the sutures, decreases the risk for infection, and removes the stress and burden on the patient and family of frequent dressing changes. Furthermore, by preventing patient manipulation and frequent removal of the dressing, the wound retains adequate moisture during healing. This technique also can be applied to a variety of outpatient procedures other than Mohs micrographic surgery.

We hope that our colleagues find this 24-7 dressing technique for dressing wounds after dermatologic surgery useful in patient populations vulnerable to wound complications.

## REFERENCES

1. Winton GB, Salasche SJ. Wound dressings for dermatologic surgery. *J Am Acad Dermatol.* 1995;13:1026-1044.
2. Broussard KC, Powers JG. Wound dressings: selecting the most appropriate type. *Am J Clin Dermatol.* 2013;14:449-459.
3. Kannon GA, Garrett AB. Moist wound healing with occlusive dressings. a clinical review. *Dermatol Surg.* 1995;21:583-590.
4. Jones AM, San Miguel L. Are modern wound dressings a clinical and cost-effective alternative to the use of gauze? *J Wound Care.* 2006;15:65-66.
5. Ubbink DT, Vermeulen H, Goossens A. Occlusive vs gauze dressings for local wound care in surgical patients: a randomized clinical trial. *Arch Surg.* 2008;143:950-955.
6. Sood A, Granick MS, Tomaselli NL. Wound dressings and comparative effectiveness data. *Adv Wound Care (New Rochelle).* 2014;3:511-529.