

Levamisole-Induced Vasculopathy With Gastric Involvement in a Cocaine User

Alan S. Boyd, MD; Melanie Ortleb, MD

PRACTICE POINTS

- More than half of the cocaine illicitly consumed in the United States is contaminated with levamisole, a veterinary drug that can incite a vasculitic/vasculopathic response in the skin as well as in other organ systems.
- Because dermatologists often are the specialists to make the diagnosis of levamisole-induced vasculopathy, clinicians should be made aware that consumption of levamisole-contaminated cocaine may affect more than the skin alone.

Reports of levamisole-induced vasculopathy (LIV) secondary to use of levamisole-contaminated cocaine largely have been limited to the skin. We report the case of a 35-year-old woman with painful purpuric lesions affecting the cheeks, nose, ears, arms, and legs of several days' duration. She recently had used crack cocaine. A biopsy of a lesion on the right arm demonstrated leukocytoclastic vasculitis. She also reported abdominal pain and gastric reflux of recent onset but denied any history of gastrointestinal tract disease. An upper gastrointestinal endoscopy was performed and demonstrated hemorrhagic erosions of the esophagus and stomach similar in appearance to the cutaneous lesions. Because dermatologists often are the specialists making the diagnosis of LIV, it is important they inform other involved clinicians that the skin may not be the sole repository of vascular insult.

Cutis. 2018;102:169-170, 175-176.

In 2010, two separate reports of cutaneous vasculitic/vasculopathic eruptions in patients with recent exposure to levamisole-contaminated cocaine (LCC) were published in the literature.^{1,2} Since then, additional reports have been published.³⁻⁶ Retiform purpura associated with cocaine use appears to be a similar condition, perhaps lying at one end of the spectrum of LCC-induced

cutaneous vascular disease.^{7,8} Although some patients have been described as having nausea and vomiting,^{8,9} including one with a sudden drop in hemoglobin to 5.8 g/dL (reference range, 14.0–17.5 g/dL),¹⁰ there are no known reported cases of LCC and levamisole-induced vasculopathy in organ systems other than the skin. Herein, we report the case of a patient with levamisole-induced vasculopathy (LIV) demonstrating endoscopic evidence of gastric hemorrhage with features similar to those involving the skin.

Case Report

A 35-year-old woman with a history of hepatitis C, intravenous drug abuse, and bipolar disorder presented to the emergency department with painful necrotic lesions on the head, neck, arms, and legs of several days' duration. Approximately 1 year prior she had been admitted to the hospital with similar lesions, with eventual partial necrosis of the left earlobe. The patient reported she had last used crack cocaine 3 days prior to the development of the lesions. A urine drug screen was positive for lorazepam, alprazolam, buprenorphine, methadone, tetrahydrocannabinol, and cocaine. She also reported abdominal pain and gastric reflux of recent onset but denied any history of gastrointestinal tract disease. During the previous admission, the patient demonstrated antinuclear antibodies at a titer of greater than 1:160 (normal, <1:40) in a smooth pattern as well as positive perinuclear antineutrophil cytoplasmic antibodies (p-ANCA) and cytoplasmic antineutrophil cytoplasmic antibodies (c-ANCA) and positive cryoglobulins. Physical examination yielded purpuric and hemorrhagic patches and plaques on the nose, bilateral ears (Figure 1A), face (Figure 1B), arms, and legs. Older lesions exhibited evidence of evolving erosion and ulceration. A biopsy of a lesion on the right arm was obtained, demonstrating extensive epidermal necrosis, hemorrhage, fibrin thrombi

From the Department of Dermatology, Vanderbilt University, Nashville, Tennessee. Dr. Boyd also is from the Department of Pathology.

The authors report no conflict of interest.

Correspondence: Alan S. Boyd, MD, 719 Thompson Ln, Ste 26300, Nashville, TN 37204 (alan.boyd@Vanderbilt.edu).

within dermal blood vessels, fibrinoid mural necrosis, perivascular neutrophils, and leukocytoclasia (Figure 2). These findings were consistent with LIV caused by exposure to LCC. A complete blood cell count was unremarkable. She was started on pain management and was given prednisone to treat the cutaneous eruption. Because of continued reports of epigastric pain and discomfort on swallowing, an upper gastrointestinal endoscopy was performed. Numerous esophageal erosions and gastric submucosal hemorrhages similar to those on the skin were noted (Figure 3). Pathology taken at the time of the endoscopy demonstrated mucosal erosions, but an evaluation for vascular insult was not possible, as submucosal tissue was not obtained. As the skin lesions began to heal, the gastric symptoms gradually subsided, and the patient was released from the hospital after 7 days.

Comment

Levamisole-Contaminated Cocaine—Cocaine is a crystalline alkaloid obtained from the leaves of the coca plant.⁷ Fifty percent of globally produced cocaine is consumed in the United States.¹⁰ There are 2 to 5 million cocaine users in the United States; in 2009, a reported 1.6 million

US adults admitted to having used cocaine in the previous month.^{4,11,12} Cocaine has been known to be cut with similar-appearing substances including lactose and mannitol, though caffeine, acetaminophen, methylphenidate, and other ingredients have been utilized.⁷

Levamisole is a synthetic imidazothiazole derivative initially developed for use as an immunomodulatory agent in patients with rheumatoid arthritis.⁴ It was later paired with

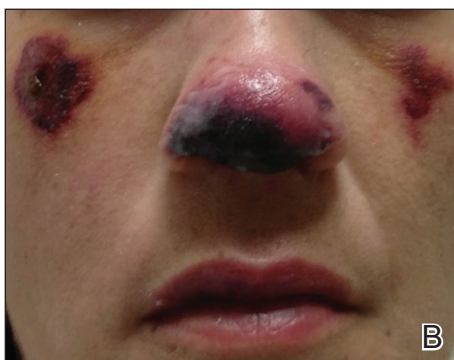
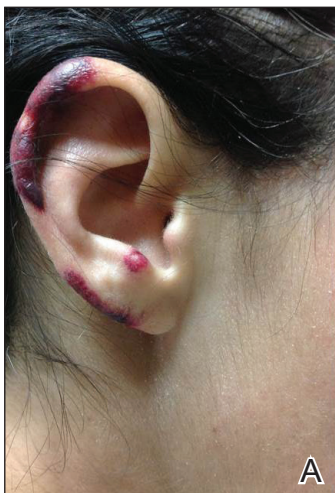
FIGURE 1. Purpura and hemorrhagic bullae of the right ear (A) as well as purpura and crusting of the cheeks and nose (B) in a patient with levamisole-induced vasculopathy.

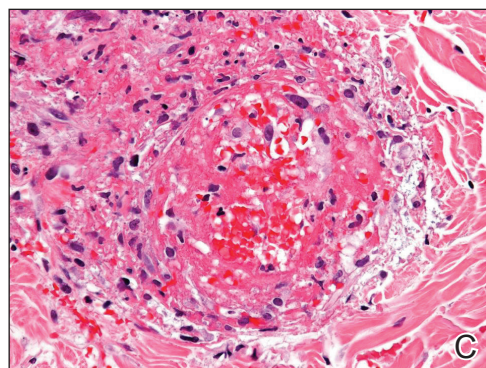
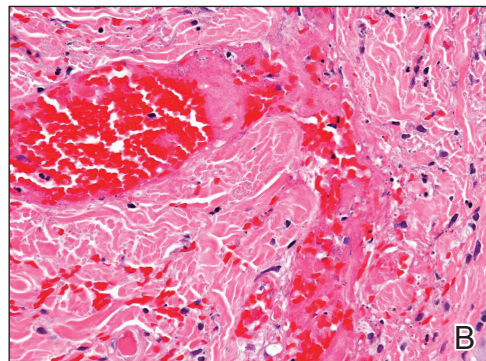
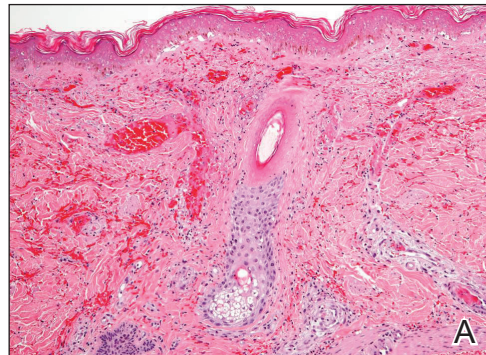


FIGURE 2. Histologic features of a biopsy from a lesion on the patient's right arm revealed epidermal necrosis with diffuse dermal hemorrhage and vessel wall breakdown (A)(H&E, original magnification $\times 40$). Dilated and congested blood vessels were noted with hemorrhage and minimal inflammation typical of the vasculopathic aspect of this disease (B) (H&E, original magnification $\times 200$). Blood vessels with fibrinoid necrosis of the wall and surrounding neutrophils with nuclear dust consistent with the vasculitic features of levamisole-induced vasculopathy also was seen (C)(H&E, original magnification $\times 200$).

CONTINUED ON PAGE 175

CONTINUED FROM PAGE 170

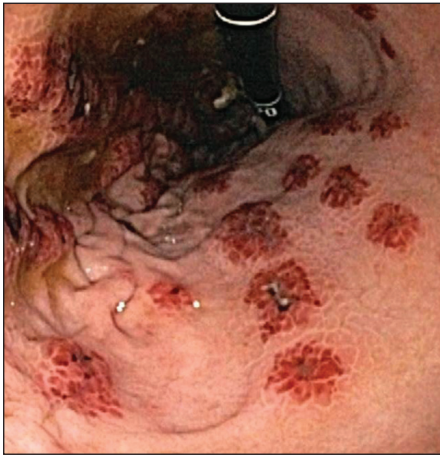

FIGURE 3. Upper gastrointestinal endoscopy revealed linear and plaque-like areas of erythema with focal ulceration and submucosal hemorrhage.

5-fluorouracil for administration in patients with carcinomas of the colon and breasts.^{4,13} In 2000, the drug was withdrawn from the US market for use in humans after an association between levamisole and agranulocytosis was noted in 2.5% to 13% of patients taking the drug for rheumatoid arthritis or as an adjuvant therapy for breast carcinoma.^{9,12} It still is available for veterinary use as an anthelmintic and is administered to humans in other countries. Levamisole acts as an immunomodulator by enhancing macrophage chemotaxis and upregulating T-cell functions as well as stimulating neutrophil chemotaxis and dendritic cell maturation.⁴ It also is known to generate autoantibodies including lupus anticoagulant, p-ANCA, c-ANCA, and antinuclear antibodies.^{7,14} Levamisole is known to exhibit cutaneous reactions. In 1999, Rongioletti et al¹⁴ reported 5 children with purpura of the ears who had been given levamisole for pediatric nephrotic syndrome. Involvement of other body areas was noted. Three patients developed lupus anticoagulant antibodies, 3 exhibited p-ANCA antibodies, and 1 was positive for c-ANCA antibodies. The investigators noted an exceptionally long latency period of 12 to 44 months after starting the drug. Histologically a vasculopathic/vasculitic process was noted.¹⁴ Direct immunofluorescence studies of affected skin in LIV have demonstrated IgM, IgA, IgG, C3, and fibrin staining of blood vessels.^{4,15} Anti-human elastase antibodies are considered both sensitive and specific for LIV and serve to differentiate it from cocaine-induced pseudovasculitis.^{4,7}

In April 2008, the New Mexico Department of Health began evaluating several unexplained cases of agranulocytosis and noted that 11 of 21 cases were associated with cocaine use.⁹ Later that year, public health workers in Alberta and British Columbia, Canada, reported finding traces of levamisole in clinical specimens and drug paraphernalia of cocaine users with agranulocytosis. Officials from the New Mexico Department of Health learned of these findings and investigated the cases, finding 7 of

9 patients with idiopathic agranulocytosis had recent exposure to cocaine. None of the 21 total patients experienced any skin findings. Nausea and vomiting were common symptoms, but abdominal pain was described in only 2 patients from an additional investigation in Washington. Both of these patients used crack cocaine, and one had a positive urine test for levamisole.⁹

The presence of levamisole initially was detected by the US Drug Enforcement Administration in 2003. By July 2009, 69% of cocaine and 3% of heroin seized by this agency was noted to contain levamisole.¹⁶ From 2003 to 2009, the concentration of levamisole contamination rose to 10%.⁴ A 2011 study found levamisole in 194 of 249 cocaine-positive urine samples.¹⁶

It is unclear why cocaine producers add levamisole to their product. Possibilities include increasing the drug's bulk or enhancing its stimulatory effects.¹² Chang et al¹⁷ posited that levamisole increases the stimulatory and euphoric effects of cocaine by increasing dopamine levels in the brain. Additionally, levamisole is metabolized to aminorex, an amphetaminelike hallucinogen that suppresses appetite, in patients with LCC.¹³ Vagi et al¹² interviewed 10 patients who had been hospitalized for agranulocytosis secondary to use of LCC. None were aware of the presence of this additive, suggesting it was not used as a marketing tool.

Cutaneous Vasculopathy—Levamisole-induced vasculopathy (also called levamisole-induced cutaneous vasculopathy¹¹) initially was reported by 2 separate groups in 2010.^{1,2} Patients typically present with tender purpuric to hemorrhagic papules, plaques, and bullae with an affinity to affect the ears, nose, and face, though other areas of the body can be affected. A pattern of retiform purpura may precede these findings in some patients. Women are disproportionately affected.¹¹ Crack cocaine use is overrepresented in LIV compared to insufflation or snorting of the drug. Affected patients may exhibit systemic symptoms including myalgia, arthralgia, and frank arthritis.¹⁰ Additionally, 15% to 80% of patients exhibit positive antinuclear antibodies, anticardiolipin antibodies, lupus anticoagulant antibodies, p-ANCA antibodies, and c-ANCA antibodies. Magro and Wang⁸ hypothesized that levamisole acting in conjunction with cocaine rather than the effects of levamisole alone is responsible for some of these findings.

Histologically, the features of a vasculopathic process are noted in some patients with the presence of frank vasculitis.¹ The vasculopathic component demonstrates vessel dilatation with thrombosis, eosinophilic deposits, and erythrocyte extravasation. Patients with frank vasculitis exhibit fibrinoid vessel wall necrosis and fibrin deposition, extravasated erythrocytes, endothelial cell atypia, and leukocytoclasia.³ Jacob et al³ noted interstitial and perivascular neovascularization in affected tissue, believed to represent one stage in the evolution of medium vessel vasculitis. Intercellular adhesion molecule 1 has been reported in affected vessel walls with endothelial caspase 3

expression and C5b-9 deposition.⁸ Magro and Wang⁸ believe the retiform purpura seen in the early stages of some of these patients with LIV represents a thrombotic dynamic with C5b-9 deposition and enhanced apoptosis. Overt vasculitis follows later, subsequent to the effect of ANCA antibodies and upregulated intercellular adhesion molecule 1 expression on vessel walls.

The clinical course of LIV typically is 2 to 3 weeks for lesion resolution; however, normalization of serologies may require 2 to 14 months. Observation and pain control with or without administration of systemic steroids is sufficient for most patients, but skin grafting, wound debridement, cyclosporine, mycophenolate mofetil, and plasmapheresis also have been employed.^{4,5} Morbidity may be substantive. One report noted LCC to be responsible for 3 cases of pulmonary hemorrhage and acute progression to chronic renal failure in another 2 patients.¹⁵ Ching and Smith¹⁸ described a patient with 52% total body surface area involvement who required skin grafting, nasal amputation, patellectomy, central upper lip excision, and amputation of the leg above the knee.

Gastrointestinal Presentation—Patients with LIV have been reported to exhibit abdominal pain, but our patient exhibited a rare presentation of visualized gastrointestinal purpura. Although support for a vasculitic/vasculopathic process requires a tissue diagnosis, the endoscopic appearance of gastric vasculitis is similar to that of cutaneous vasculitis.¹⁹ Clinicians caring for patients exposed to LCC should bear in mind that the vascular insults associated with LIV are not restricted solely to the skin.

REFERENCES

1. Waller JM, Feramisco JD, Alberta-Wszolek L, et al. Cocaine-associated retiform purpura and neutropenia: is levamisole the culprit? *J Am Acad Dermatol.* 2010;63:530-535.
2. Bradford M, Rosenberg B, Moreno J, et al. Bilateral necrosis of earlobes and cheeks: another complication of cocaine contaminated with levamisole. *Ann Int Med.* 2010;152:758-759.
3. Jacob RS, Silva CY, Powers JG, et al. Levamisole-induced vasculopathy: a report of 2 cases and a novel histopathologic finding. *Am J Dermatopathol.* 2012;34:208-213.
4. Lee KC, Ladizinski B, Federman DG. Complications associated with use of levamisole-contaminated cocaine: an emerging public health challenge. *Mayo Clin Proc.* 2012;87:581-586.
5. Pavenski K, Vandenberghe H, Jakubovic H, et al. Plasmapheresis and steroid treatment of levamisole-induced vasculopathy and associated skin necrosis in crack/cocaine users. *J Cutan Med Surg.* 2013;17:123-126.
6. Mandrell J, Kranc CL. Prednisone and vardenafil hydrochloride refractory levamisole-induced vasculitis. *Cutis.* 2016;98:E15-E19.
7. Walsh NM, Green PJ, Burlingame RW, et al. Cocaine-related retiform purpura: evidence to incriminate the adulterant, levamisole [published online August 25, 2010]. *J Cutan Pathol.* 2010;37:1212-1219.
8. Magro CM, Wang X. Cocaine-associated retiform purpura: a C5b-9 mediated microangiopathy syndrome associated with enhanced apoptosis and high levels of intercellular adhesion molecule-1 expression. *Am J Dermatopathol* 2013;35:722-730.
9. Centers for Disease Control and Prevention (CDC). Agranulocytosis associated with cocaine use—four states, March 2008–November 2009. *MMWR Morb Mortal Wkly Rep.* 2009;58:1381-1385.
10. Espinoza LR, Alamino RP. Cocaine-induced vasculitis: clinical and immunological spectrum. *Curr Rheumatol Rep.* 2012;14:532-538.
11. Arora NP. Cutaneous vasculopathy and neutropenia associated with levamisole-adulterated cocaine. *Am J Med Sci.* 2013;345:45-51.
12. Vagi SJ, Sheikh S, Brackney M, et al. Passive multistate surveillance for neutropenia after of cocaine or heroin possibly contaminated with levamisole. *Ann Emerg Med.* 2013;61:468-474.
13. Lee KC, Ladizinski, Nutan FN. Systemic complications of levamisole toxicity. *J Am Acad Dermatol.* 2012;67:791-792.
14. Rongioletti E, Ghio L, Ginervri E, et al. Purpura of the ears: a distinctive vasculopathy with circulating autoantibodies complicating longer-term treatment with levamisole in children. *Br J Dermatol.* 1999;140:948-951.
15. McGrath MM, Isakova T, Rennke HG, et al. Contaminated cocaine and antineutrophil cytoplasmic antibody-associated diseases. *Clin J Am Soc Nephrol.* 2011;6:2799-2805.
16. Buchanan JA, Heard K, Burbach C, et al. Prevalence of levamisole in urine toxicology screens positive for cocaine in an inner-city hospital. *JAMA.* 2011;305:1657-1658.
17. Chang A, Osterloh J, Thomas J. Levamisole: a dangerous new cocaine adulterant. *Clin Pharmacol Ther.* 2010;88:408-411.
18. Ching JA, Smith DJ. Levamisole-induced necrosis of skin, soft-tissue and bone: case report and review of literature. *J Burn Care Res.* 2012;33:E1-E5.
19. Naruse G, Shimata K. Cutaneous and gastrointestinal purpura. *N Engl J Med.* 2013;369:1843.