

➤ **THE PATIENT**
25-year-old Navy sailor

➤ **SIGNS & SYMPTOMS**

- Mild cough
- Wheezing
- Loud heart sounds

Arneh Babakhani, MD, PhD; Robert N. Clapp, MD, MS; William B. Warner, MD
USS Harpers Ferry (Dr. Babakhani) and Fleet Surgical Team (Drs. Clapp and Warner), San Diego, Calif

✉ navydrb@gmail.com

The authors reported no potential conflict of interest relevant to this article.

The views expressed here are those of the authors and do not reflect the official policy of the Department of the Navy, the Department of Defense, or the US government.

➤ THE CASE

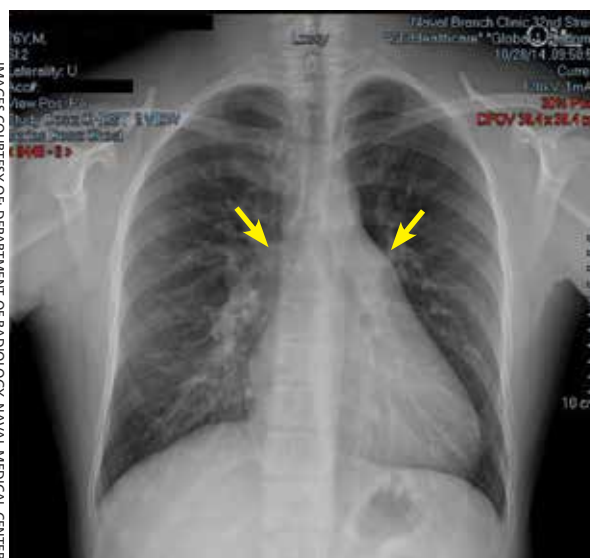
A 25-year-old man, who was an active duty US Navy sailor, went to his ship's medical department complaining of a mild cough that he'd had for 2 days. He denied having any fevers, chills, night sweats, angina, or dyspnea. He said he hadn't experienced any exertional fatigue or difficulty completing the rigorous physical tasks of his occupation as an engineman on the ship. The patient had no medical or surgical history of significance, and he wasn't taking any medications or supplements.

On exam, he was not in acute distress and his vital signs were within normal limits. Auscultation revealed mild wheezing throughout the upper lung fields and loud heart sounds throughout his chest that were audible even with gentle contact of the stethoscope diaphragm. He had no discernible murmurs, rubs, or gallops.

In light of the unusually loud heart sounds heard on exam, we performed an electrocardiogram. The EKG revealed a normal sinus rhythm, slight right axis deviation indicated by tall R-waves in V1 (also suggestive of right ventricular hypertrophy), an incomplete right bundle branch block, and a crochitage sign (a notch in the R-waves of the inferior leads).¹ A chest x-ray (FIGURE 1) revealed a normal-sized heart and dilated pulmonary vasculature suggestive of pulmonary hypertension.

FIGURE 1

Chest x-ray reveals normal-sized heart, but...



IMAGES COURTESY OF: DEPARTMENT OF RADIOLOGY, NAVAL MEDICAL CENTER, SAN DIEGO

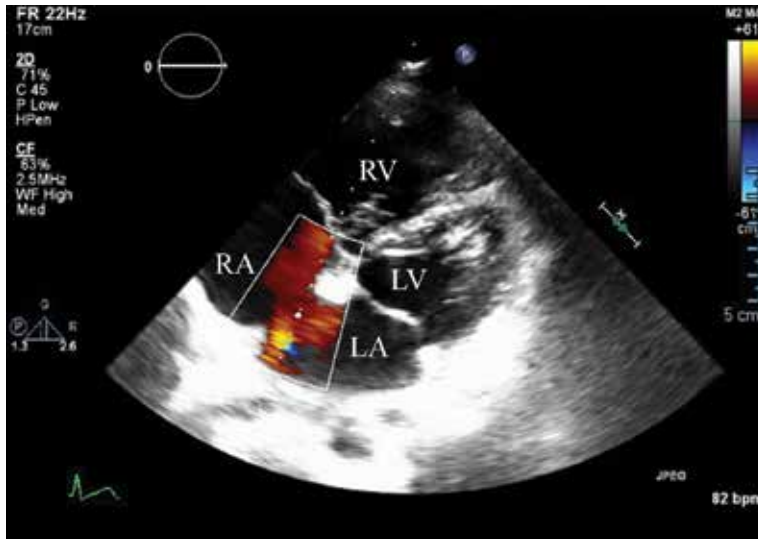
A chest x-ray showed a normal-sized heart and prominent pulmonary arterial outflow tracts (arrows) with diffusely prominent pulmonary vasculature.

THE DIAGNOSIS

To further evaluate the cardiopulmonary findings, ultrasound studies (transthoracic and transesophageal echocardiography) were performed. These demonstrated a very large secundum-type atrial septal defect (ASD), measuring at its largest point about 30 × 48 mm (FIGURE 2 and FIGURE 3C). Doppler flow analysis and a bubble study (VIDEOS 1 and 2, respectively, available at jfponline.com) demonstrated significant shunting across the ASD. Gated cardiac computed tomography (CT) was also used to characterize

FIGURE 2

Echocardiogram reveals large atrial septal defect



A transthoracic echocardiogram demonstrated a very large secundum-type atrial septal defect measuring 30 × 48 mm, with a calculated area of 10.6 cm² (white box). Color-flow Doppler (red) demonstrated significant shunting across the defect.

LA, left atrium; LV, left ventricle; RA, right atrium; RV, right ventricle.

the ASD (FIGURE 3). It revealed that the superior and posterior rims of the ASD were essentially absent and that the right atrium and ventricle were severely enlarged, while the left chambers were normal in size and function with an ejection fraction >55%. The notching of the R-waves of the inferior leads, seen in our patient's EKG, is typically seen with large ASDs.^{1,2}

DISCUSSION

ASDs are typically uncovered on exam via auscultation of heart sounds, which might reveal a split of the second heart sound (S₂) and diastolic murmurs. ASDs are typically classified by size, and their management depends on this factor, along with the patient's age and symptoms. In children with small defects (<6 mm), treatment usually consists of conservative observation, as more than half of these ASDs will spontaneously close.³ But, as children age, they are more likely to engage in exertional activity (work, recreational sports)

and an unrepaired ASD may yield symptoms (angina, dyspnea, fatigue, other cardiopulmonary strain). With such symptoms and when closure is not spontaneously achieved by adolescence or adulthood, an invasive approach is often necessary to correct the defect.

■ **ASD repair.** Traditionally, repair has involved some form of open thoracotomy. More recently, several minimally invasive techniques have been developed. Catheter-based device closure, in which a catheter is percutaneously guided to the defect and a patch is deployed to seal the ASD, is a technique that has been shown to successfully correct large ASDs of up to 40 mm in size.⁴ Robotic procedures have also been developed to correct ASDs through much smaller incisions.⁵ Both of these techniques require a significant rim of residual septal tissue around the defect.

■ **Individualized approach.** Since our patient had a rather large ASD that did not have sufficient residual septal rim tissue, percutaneous and robotic approaches were not feasible. Instead, he required more invasive cardiothoracic surgery. In cases such as this, the exact technique and type of incision (sternotomy vs access through the lateral chest wall) depend on age, gender, and the presence of other comorbidities.⁶

■ **Our patient.** Because there was concern that any approach other than a median one might not afford enough space to fix an ASD of such considerable size, our patient underwent a median sternotomy by a pediatric cardiothoracic surgeon who specialized in these repairs (in children as well as young adults). During the procedure, the ASD was accessed and confirmed to be as large as predicted by diagnostic imaging. A surgical patch was sutured in place to correct the defect. There were no intraoperative or postop complications.

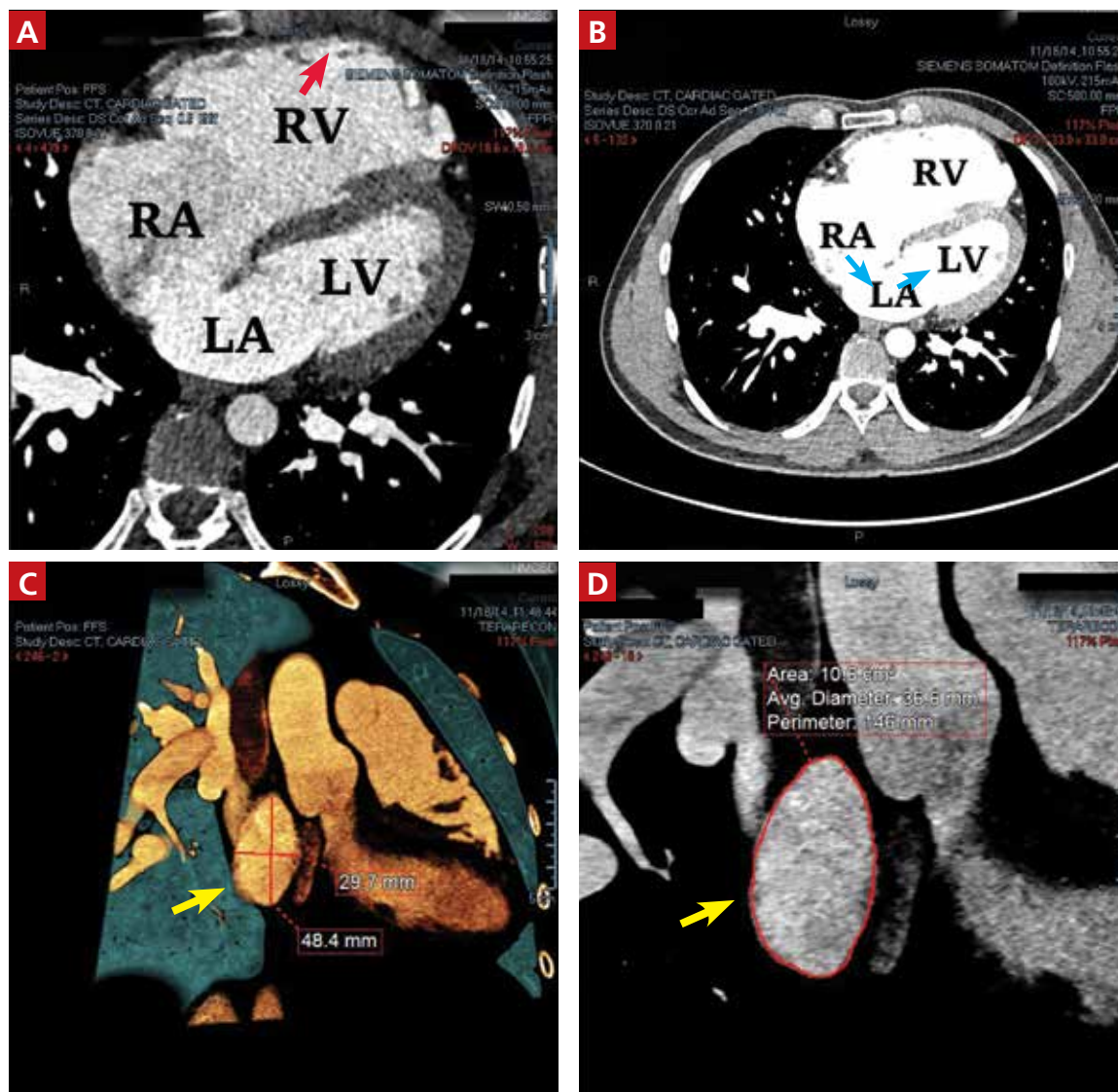
Four weeks later, the patient had a mild pericardial effusion that was managed medically with daily furosemide and aspirin. At his 8-week postop appointment, the fluid accumulation had resolved, and he was completely asymptomatic. The patient returned to full-time active duty in the US Navy.

THE TAKEAWAY

Adults with rather large ASDs can present in

FIGURE 3

Gated cardiac CT scan further elucidates the defect



This gated cardiac computed tomography scan revealed large right-sided chambers with marked contact of the right ventricle (red arrow) against the anterior chamber wall (A). A significant filling defect is demonstrated by the contrast across the atrial septal defect (blue arrows) indicating flow (B). A cross-sectional view with color enhancements (C and D) shows the large secundum-type atrial septal defect (yellow arrows).

LA, left atrium; LV, left ventricle; RA, right atrium; RV, right ventricle.

a relatively asymptomatic manner and report none of the classic complaints (angina, dyspnea, fatigue). They may even engage in heavy exertional activity with no difficulty. The underlying defect may be discovered incidentally on exam by noting a split of the S2 on auscultation. If pulmonary hyperten-


sion exists, the clinician may also note a loud S2. An exam that raises suspicion for an ASD can then be followed by tests that solidify the diagnosis. Surgery is usually necessary to correct an ASD in an adult who is symptomatic or exhibits significant cardiopulmonary strain.

JFP


CONTINUED

REFERENCES

1. Heller J, Hagège AA, Besse B, et al. "Crochetage" (notch) on R wave in inferior limb leads: a new independent electrocardiographic sign of atrial septal defect. *J Am Coll Cardiol.* 1996;27:877-882.
2. Kuijpers JM, Mulder BJM, Bouma BJ. Secundum atrial septal defect in adults: a practical review and recent developments. *Neth Heart J.* 2015;23:205-211.
3. McMahon CJ, Feltes TF, Fraley JK, et al. Natural history of growth of secundum atrial septal defects and implications for transcatheter closure. *Heart.* 2002;87:256-259.
4. Lopez K, Dalvi BV, Balzer D, et al. Transcatheter closure of large secundum atrial septal defects using the 40 mm amplatzer septal occluder: results of an international registry. *Catheter Cardiovasc Interv.* 2005;66:580-584.
5. Argenziano M, Oz MC, Kohmoto T, et al. Totally endoscopic atrial septal defect repair with robotic assistance. *Circulation.* 2003;108 Suppl 1:II191-II194.
6. Hopkins RA, Bert AA, Buchholz B, et al. Surgical patch closure of atrial septal defects. *Ann Thorac Surg.* 2004;77:2144-2149.



Join the official job board of
THE JOURNAL OF
**FAMILY
PRACTICE**

 **MEDJOBNETWORK.com**
Physician • NP/PA Career Center

Search 1000s of Jobs and Apply in 1 Click
And get FREE benefits including...

- Access to 30+ medical web sites
- Medical news and clinical advice
- E-Alert and Newsletters on your smart phone
- Online CME and MD-IQ Quizzes
- Coverage of over 200 meetings
- And much more!

Julian Knight
Digital Sales Director, Classifieds
Phone: 973-206-2317
jknight@frontlinemedcom.com
www.medjobnetwork.com