

Temporal Triangular Alopecia Acquired in Adulthood



Matthew C. Willett, MD; Leonard C. Sperling, MD

PRACTICE POINTS

- Temporal triangular alopecia (TTA) in adults often is confused with alopecia areata.
- An acquired, persistent, unchanging, circumscribed hairless spot in an adult that does not respond to intralesional corticosteroids may represent TTA.
- Hair miniaturization without peribulbar inflammation is consistent with a diagnosis of TTA.

To the Editor:

Temporal triangular alopecia (TTA), a condition first described by Sabouraud¹ in 1905, is a circumscribed non-scarring form of alopecia. Also referred to as congenital triangular alopecia, TTA presents as a triangular or lancet-shaped area of hair loss involving the frontotemporal hairline. Temporal triangular alopecia is characterized histologically by a normal number of miniaturized hair follicles without notable inflammation.² Although the majority of cases arise between birth and 9 years of age,^{3,4} rare cases of adult-onset TTA also have been reported.^{5,6} Adult-onset cases can cause notable diagnostic confusion and inappropriate treatment, as reported in our patient.

A 25-year-old woman with a history of Hashimoto thyroiditis presented with hair loss affecting the right temporal scalp of 3 years' duration that was first noticed by her husband. The lesion was an asymptomatic, 6×8-cm, roughly lancet-shaped patch of alopecia located on the right temporal scalp, bordering on the frontal hairline (Figure 1). Centrally, the patch appeared almost hairless with a few retained terminal hairs. The frontal hairline was thinned but still present. There was no scaling or erythema, and fine vellus hairs and a few isolated terminal hairs covered the area. The corresponding skin on the contralateral temporal scalp showed normal hair

density. The patient insisted that she had normal hair at the affected area until 22 years of age, and she denied a history of trauma or tight hairstyles. Initially diagnosed with alopecia areata by her primary care provider, the patient was treated with topical corticosteroids for 6 months without benefit. She was subsequently referred to a dermatologist who again offered a diagnosis of alopecia areata and treated the lesions with 2 intralesional corticosteroid injections without benefit. No biopsies of the affected area were performed, and the patient was given a trial of topical minoxidil.

The patient consulted a new primary care provider and was diagnosed with scarring alopecia. She was referred to our dermatology department for further treatment. An initial biopsy at the edge of the affected area was interpreted as normal, but after failing additional intralesional

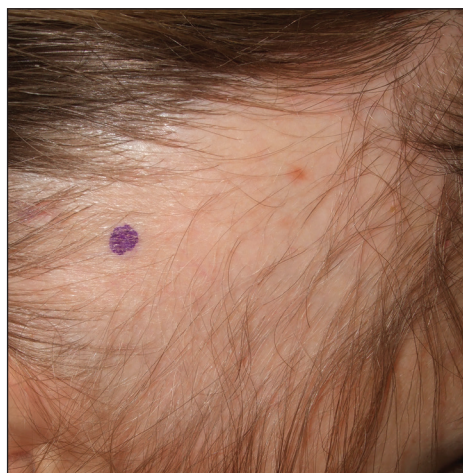

FIGURE 1. Temporal triangular alopecia with an oval to lancet-shaped zone of marked hair thinning that extended to the frontotemporal fringe.

From the School of Medicine, Uniformed Services University of the Health Sciences, Bethesda, Maryland.

The authors report no conflict of interest.

The opinions and assertions expressed herein are those of the authors and do not necessarily reflect the official policy or position of the Uniformed Services University or the Department of Defense.

Correspondence: Leonard C. Sperling, MD, Uniformed Services University of the Health Sciences, Department of Dermatology, 4301 Jones Bridge Rd, Bethesda, MD 20814 (leonard.sperling@usuhs.edu).

corticosteroid injections, she was referred to our hair clinic where another biopsy was performed in the central portion of the lesion. A 4-mm diameter punch biopsy specimen revealed a normal epidermis and dermis; however, in the lower dermis only a single terminal follicle was seen (Figure 2). Sections through the upper dermis (Figure 3) showed that the total number of hairs was normal or nearly normal with at least 22 follicles, but most were vellus and indeterminate hairs with only a single terminal hair. The dermal architecture was otherwise normal. Given the clinical and histologic findings, a diagnosis of TTA was made. Subsequent to the diagnosis, the patient did not pursue any additional treatment options and preferred to style her hair so that the area of TTA remained covered.

The differential diagnosis in adults presenting with a patch of localized alopecia includes alopecia areata, trichotillomania, pressure-induced alopecia, traction alopecia, lichen planopilaris, discoid lupus erythematosus, and rarely TTA. Temporal triangular alopecia is a fairly common, if underreported, nonscarring form of alopecia that mainly affects young children. A PubMed search of articles indexed for MEDLINE using the terms *temporal triangular alopecia* or *congenital triangular alopecia* or *triangular alopecia* documented only 76 cases of TTA including our own, with the majority of patients diagnosed before 9 years of age. Only 2 cases of adult-onset TTA have been reported,^{5,6} possibly leading to misdiagnosis of adult patients who present with similar areas of hair loss. As with some prior cases of TTA,^{5,7} our patient was misdiagnosed with alopecia areata and scarring alopecia, both treated unsuccessfully before a diagnosis of TTA was considered. Clues to the diagnosis included the location, the lack of change in size and shape, the lack of response to intralesional corticosteroids, and the presence of numerous vellus hairs on the surface. A biopsy of the visibly hairless zone was confirmatory. The normal or nearly normal number of miniaturized hairs in

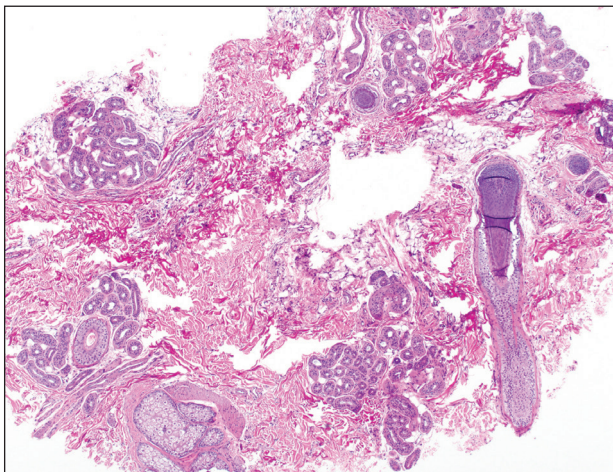


FIGURE 2. Temporal triangular alopecia. A section through the deep dermis revealed a single terminal follicle (H&E, original magnification $\times 40$).

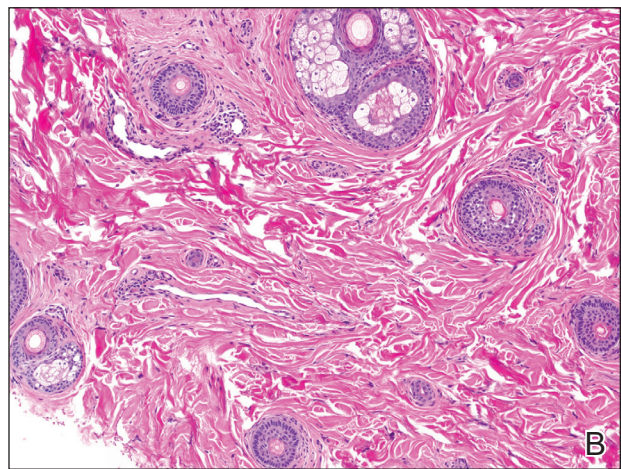
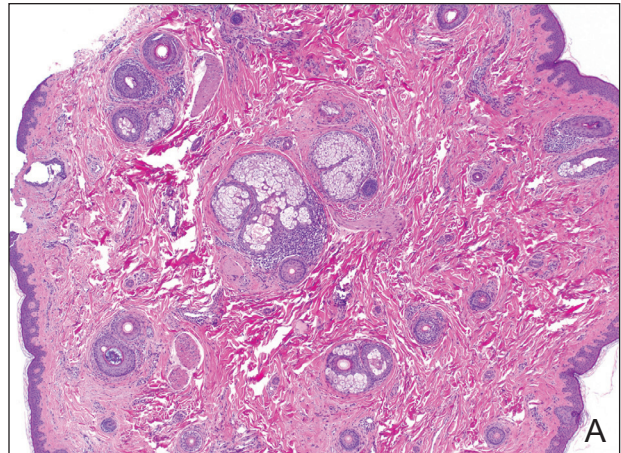


FIGURE 3. Temporal triangular alopecia. A section through the upper dermis revealed a nearly normal number of hairs but almost all were greatly miniaturized (A and B)(H&E, original magnifications $\times 40$ and $\times 100$).

specimens of TTA suggest that topical minoxidil therapy (eg, 5% solution twice daily for at least 6 months) might be useful, but the authors have tried it on a few other patients with clinically typical TTA without discernible benefit. When lesions are small, excision provides a fast and permanent solution to the problem, albeit with the usual risks of minor surgery.

REFERENCES

1. Sabouraud RJA. *Manuel Élémentaire de Dermatologie Topographique Régionale*. Paris, France: Masson & Cie; 1905:197.
2. Trakimas C, Sperling LC, Skelton HG 3rd, et al. Clinical and histologic findings in temporal triangular alopecia. *J Am Acad Dermatol*. 1994;31:205-209.
3. Yamazaki M, Irisawa R, Tsuboi R. Temporal triangular alopecia and a review of 52 past cases. *J Dermatol*. 2010;37:360-362.
4. Sarifakioglu E, Yilmaz AE, Gorpelioglu C, et al. Prevalence of scalp disorders and hair loss in children. *Cutis*. 2012;90:225-229.
5. Trakimas CA, Sperling LC. Temporal triangular alopecia acquired in adulthood. *J Am Acad Dermatol*. 1999;40:842-844.
6. Akan IM, Yildirim S, Avci G, et al. Bilateral temporal triangular alopecia acquired in adulthood. *Plast Reconstr Surg*. 2001;107:1616-1617.
7. Gupta LK, Khare AK, Garg A, et al. Congenital triangular alopecia—a close mimicker of alopecia areata. *Int J Trichology*. 2011;3:40-41.