

# Gottron Papules Mimicking Dermatomyositis: An Unusual Manifestation of Systemic Lupus Erythematosus

Ji Won Ahn, MD; Sherry Yang, MD; Katherine Johnson, DO; Tor Shwayder, MD

## PRACTICE POINTS

- Gottron-like papules can be a dermatologic presentation of lupus erythematosus.
- When present along with other findings of lupus erythematosus without any clinical manifestations of dermatomyositis, Gottron-like papules can be thought of as a manifestation of lupus erythematosus rather than dermatomyositis.

To the Editor:

An 11-year-old girl presented to the dermatology clinic with an asymptomatic rash on the bilateral forearms, dorsal hands, and ears of 1 month's duration. Recent history was notable for persistent low-grade fevers, dizziness, headaches, arthralgia, and swelling of multiple joints, as well as difficulty ambulating due to the joint pain. A thorough review of systems revealed no photosensitivity, oral sores, weight loss, pulmonary symptoms, Raynaud phenomenon, or dysphagia.

Medical history was notable for presumed viral pancreatitis and transaminitis requiring inpatient hospitalization 1 year prior to presentation. The patient underwent extensive workup at that time, which was notable for a positive antinuclear antibody level of 1:2560, an elevated erythrocyte sedimentation rate level of 75 mm/h (reference range, 0–22 mm/h), hemolytic anemia with a hemoglobin of 10.9 g/dL (14.0–17.5 g/dL), and leukopenia with a white blood cell count of 3700/ $\mu$ L (4500–11,000/ $\mu$ L). Additional laboratory tests were

performed and were found to be within reference range, including creatine kinase, aldolase, complete metabolic panel, extractable nuclear antigen, complement levels, C-reactive protein level, antiphospholipid antibodies, partial thromboplastin time, prothrombin time, anti-double-stranded DNA, rheumatoid factor,  $\beta_2$ -glycoprotein, and antineutrophil cytoplasmic antibody tests. Skin purified protein derivative (tuberculin) test and chest radiograph also were unremarkable. The patient also was evaluated and found negative for Wilson disease, hemochromatosis,  $\alpha_1$ -antitrypsin disease, and autoimmune hepatitis.

Physical examination revealed erythematous plaques with crusted hyperpigmented erosions and central hypopigmentation on the bilateral conchal bowls and antihelices, findings characteristic of discoid lupus erythematosus (Figure 1A). On the bilateral elbows, metacarpophalangeal (MCP) joints, and proximal interphalangeal (PIP) joints, there were firm, erythematous to violaceous, keratotic papules that were clinically suggestive of Gottron-like papules (Figures 1B and 1C). However, there were no lesions on the skin between the MCP, PIP, and distal interphalangeal joints. The MCP joints were associated with swelling and were tender to palpation. Examination of the fingernails showed dilated telangiectasia of the proximal nail folds and ragged hyperkeratotic cuticles of all 10 digits (Figure 1D). On the extensor aspects of the bilateral forearms, there were erythematous excoriated papules and papulovesicular lesions with central hemorrhagic crusting. The patient showed no shawl sign, heliotrope rash, calcinosis, malar rash, oral lesions, or hair loss.

Additional physical examinations performed by the neurology and rheumatology departments revealed no

Dr. Ahn was from Washington University School of Medicine, St. Louis, Missouri, and currently is from the University of Michigan, Ann Arbor.

Dr. Yang is from the Department of Dermatology, Thomas Jefferson University Hospital, Philadelphia, Pennsylvania. Dr. Johnson is from Lakeshore Dermatology, Grand Rapids, Michigan. Dr. Shwayder is from the Department of Dermatology, Henry Ford Hospital, Detroit, Michigan.

The authors report no conflict of interest.

Correspondence: Tor Shwayder, MD, Henry Ford Hospital, Department of Dermatology, 3031 W Grand Blvd, Ste 800, Detroit, MI 48202 (tshwayd1@hfhs.org).

impairment of muscle strength, soreness of muscles, and muscular atrophy. Joint examination was notable for restriction in range of motion of the hands, hips, and ankles due to swelling and pain of the joints. Radiographs and ultrasound of the feet showed fluid accumulation and synovial thickening of the metatarsal phalangeal joints and one of the PIP joints of the right hand without erosion.

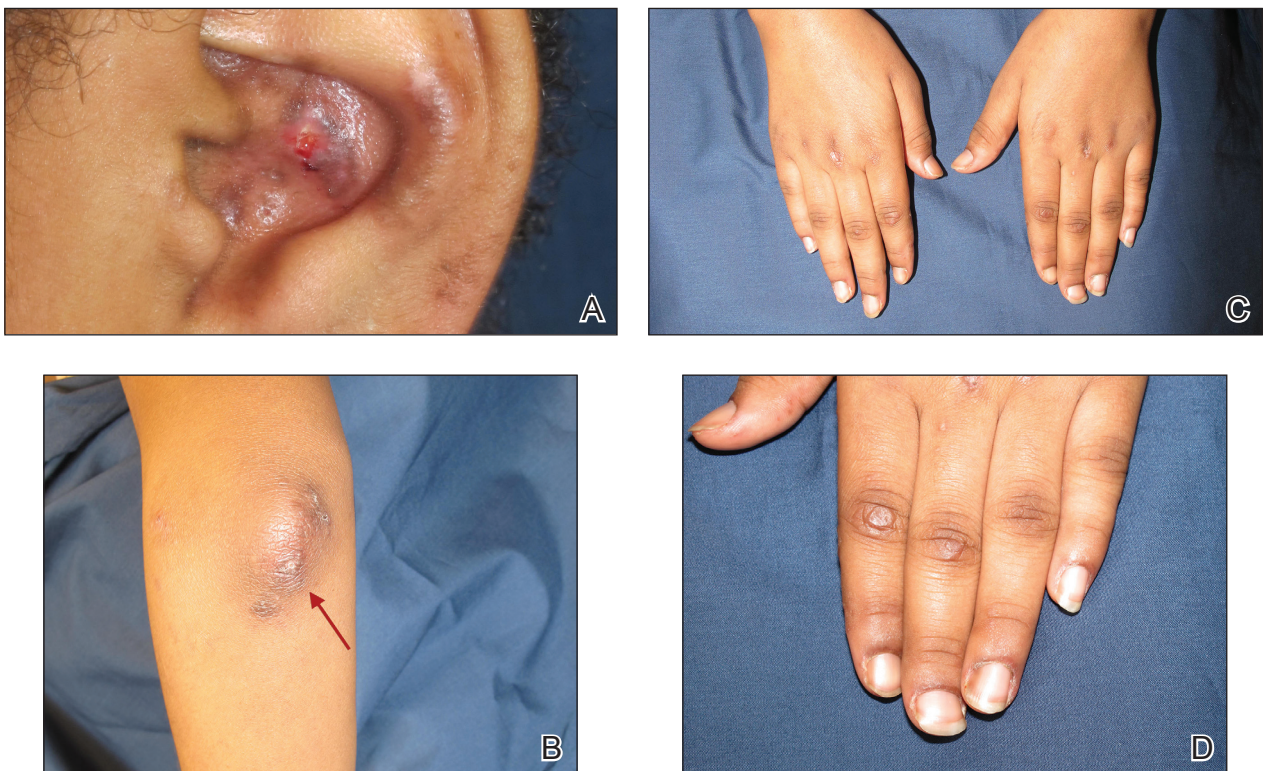
The patient did not undergo magnetic resonance imaging of muscles due to the lack of muscular symptoms and normal myositis laboratory markers. Dermatomyositis-specific antibody testing, such as anti-Jo-1 and anti-Mi-2, also was not performed.

After reviewing the biopsy results, laboratory findings, and clinical presentation, the patient was diagnosed with systemic lupus erythematosus (SLE), as she met American College of Rheumatology criteria<sup>1</sup> with the following: discoid rash, hemolytic anemia, positive anti-nuclear antibodies, and nonerosive arthritis. Due to her abnormal constellation of laboratory values and symptoms, she was evaluated by 2 pediatric rheumatologists at 2 different medical centers who agreed with a primary diagnosis of SLE rather than dermatomyositis sine myositis. The hemolytic anemia was attributed to underlying connective tissue disease, as the hemoglobin levels were found to be persistently low for 1 year prior to the

diagnosis of systemic lupus, and there was no alternative cause of the hematologic disorder.

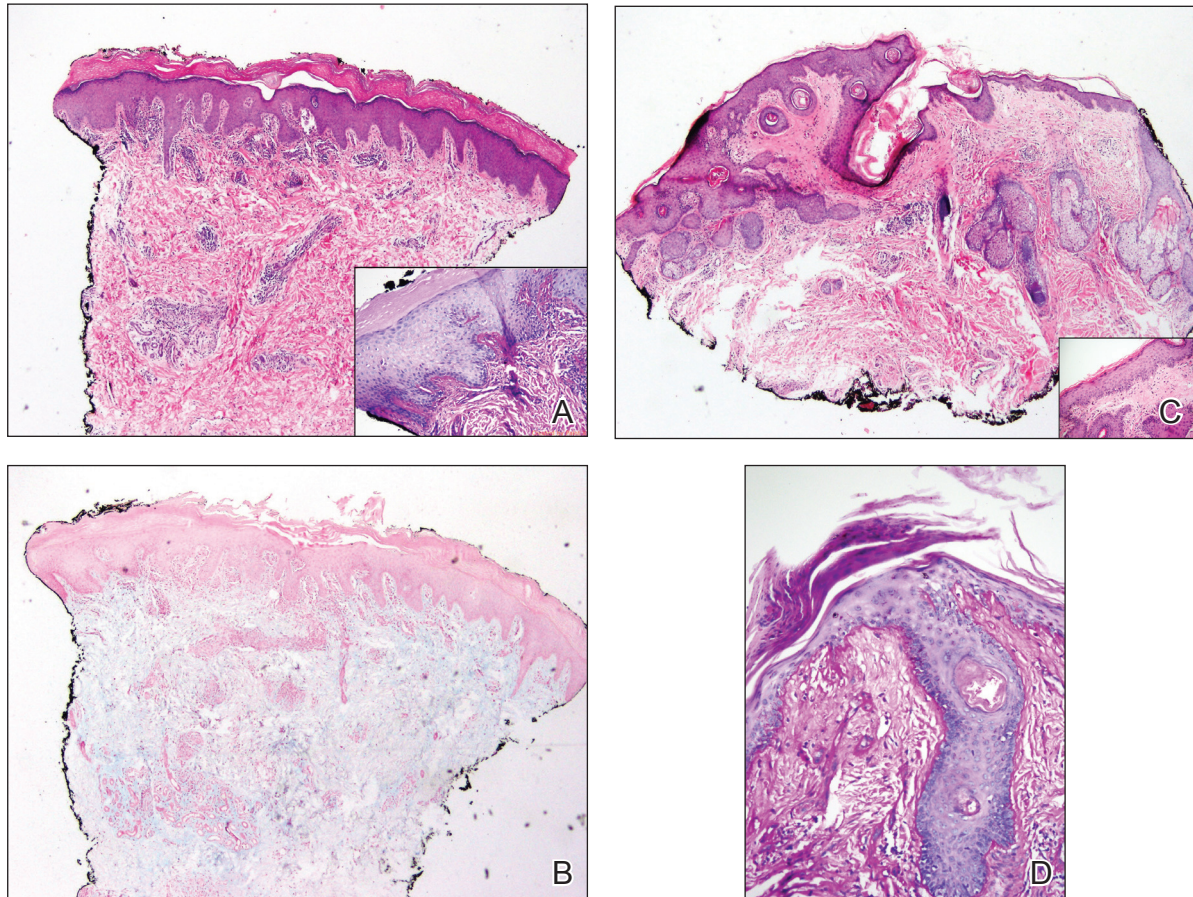
A punch biopsy obtained from a Gottron-like papule on the dorsal aspect of the left hand revealed lymphocytic interface dermatitis and slight thickening of the basement membrane zone (Figure 2A). There was a dense superficial and deep periadnexal and perivascular lymphocytic inflammation as well as increased dermal mucin, which can be seen in both lupus erythematosus and dermatomyositis (Figure 2B). Perniosis also was considered from histologic findings but was excluded based on clinical history and physical findings. A second biopsy of the left conchal bowl showed hyperkeratosis, epidermal atrophy, interface changes, follicular plugging, and basement membrane thickening. These findings can be seen in dermatomyositis, but when considered together with the clinical appearance of the patient's eruption on the ears, they were more consistent with discoid lupus erythematosus (Figures 2C and 2D).

Finally, although ragged cuticles and proximal nail fold telangiectasia typically are seen in dermatomyositis, nail fold hyperkeratosis, ragged cuticles, and nail bed telangiectasia also have been reported in lupus erythematosus.<sup>2,3</sup> Therefore, the findings overlying our patient's knuckles and elbows can be considered Gottron-like papules in the setting of SLE.



**FIGURE 1.** Erythematous plaques with crusted hyperpigmented erosions and central hypopigmentation seen on the conchal bowl and antihelix of the left external ear (A), as well as erythematous keratotic papules on the left elbow (arrow)(B) and metacarpophalangeal joints and proximal interphalangeal joints (C). Dystrophic and ragged cuticles as well as hyperkeratosis of the proximal nail folds (D).





**FIGURE 2.** Biopsy of a papule on the dorsal aspect of the left hand showed lymphocytic interface dermatitis, thickening of the basement membrane zone with periodic acid–Schiff stain (inset, original magnification  $\times 100$ ), and superficial and deep perivascular and periadnexal inflammation (A)(H&E, original magnification  $\times 40$ ). Mucin stain of a papule on the metacarpophalangeal joint on the dorsal aspect of the left hand showed abundance of dermal mucin (B)(Alcian blue, original magnification  $\times 40$ ). Biopsy of the conchal bowl erosion showed hyperkeratosis, epidermal atrophy, and follicular plugging (C)(H&E, original magnification  $\times 40$  [H&E, original magnification  $\times 200$  [inset]]). Periodic acid–Schiff stain showed thickening of the basement membrane zone and interface changes (D)(original magnification  $\times 100$ ).

Dermatomyositis has several characteristic dermatologic manifestations, including Gottron papules, shawl sign, facial heliotrope rash, periungual telangiectasia, and mechanic's hands. Of them, Gottron papules have been the most pathognomonic, while the other skin findings are less specific and can be seen in other disease entities.<sup>4,5</sup>

The pathogenesis of Gottron papules in dermatomyositis remains largely unknown. Prior molecular studies have proposed that stretch CD44 variant 7 and abnormal osteopontin levels may contribute to the pathogenesis of Gottron papules by increasing local inflammation.<sup>6</sup> Studies also have linked abnormal osteopontin levels and CD44 variant 7 expression with other diseases of autoimmunity, including lupus erythematosus.<sup>7</sup> Because lupus erythematosus can have a large variety of cutaneous findings, Gottron-like papules may be considered a rare dermatologic presentation of lupus erythematosus.

We present a case of Gottron-like papules as an unusual dermatologic manifestation of SLE, challenging

the concept of Gottron papules as a pathognomonic finding of dermatomyositis.

#### REFERENCES

- Hochberg MC. Updating the American College of Rheumatology revised criteria for the classification of systemic lupus erythematosus. *Arthritis Rheum.* 1997;40:1725.
- Singal A, Arora R. Nail as a window of systemic diseases. *Indian Dermatol Online J.* 2015;6:67-74.
- Trüeb RM. Hair and nail involvement in lupus erythematosus. *Clin Dermatol.* 2004;22:139-147.
- Koler RA, Montemarano A. Dermatomyositis. *Am Fam Physician.* 2001;64:1565-1572.
- Muro Y, Sugiura K, Akiyama M. Cutaneous manifestations in dermatomyositis: key clinical and serological features—a comprehensive review. *Clin Rev Allergy Immunol.* 2016;51:293-302.
- Kim JS, Bashir MM, Werth VP. Gottron's papules exhibit dermal accumulation of CD44 variant 7 (CD44v7) and its binding partner osteopontin: a unique molecular signature. *J Invest Dermatol.* 2012; 132:1825-1832.
- Kim JS, Werth VP. Identification of specific chondroitin sulfate species in cutaneous autoimmune disease. *J Histochem Cytochem.* 2011;59:780-790.