

# Vertebral Artery Dissection in Active-Duty Soldier Due to Mixed Martial Arts Choke Hold

Tyler Powell, MD; Timothy Fullam, MD; Jonathan Hammett, MD; Darrell Nettlow, MD; and Jason Harris, MD

In the military health system, it is important to be aware of this potential complication of combatives as instruction in close-quarters combat continues to be an important aspect of military training.

**Dr. Powell** is an Internist, **Dr. Fullam** is a Neurology Resident, **Dr. Hammett** is a Radiology Resident, **Dr. Nettlow** is an Internal Medicine Resident, and **Dr. Harris** is a Neuro-ophthalmologist, all at San Antonio Military Medical Center in Texas.  
**Correspondence:**  
Dr. Powell (tyler.a.powell.mil@mail.mil)

**K**nowledge of the potential dangers of mixed martial arts is valuable for Department of Defense (DoD) health care providers as the military continues to implement combatives training into regular military instruction. This case study presents an active-duty service member who developed a spontaneous vertebral artery dissection (sVAD) during mixed martial arts training, which led to a cerebellar stroke.

To the authors' knowledge this is the first documented case of a sVAD with associated stroke related to a mixed martial arts choke hold. Understanding the diagnosis, management, and prognosis of this condition will remain important as hand-to-hand combat instruction continues to be a part of regular military training.

## CASE PRESENTATION

A 39-year-old active-duty male without significant past medical history presented to the emergency department (ED) at the San Antonio Military Medical Center in Texas for evaluation of severe vertigo with associated nausea and vomiting. He had participated in a Jiu-Jitsu match the evening prior to his presentation and reported that he was placed in a choke hold within the last 12 seconds of the match. He denied losing consciousness during this hold.

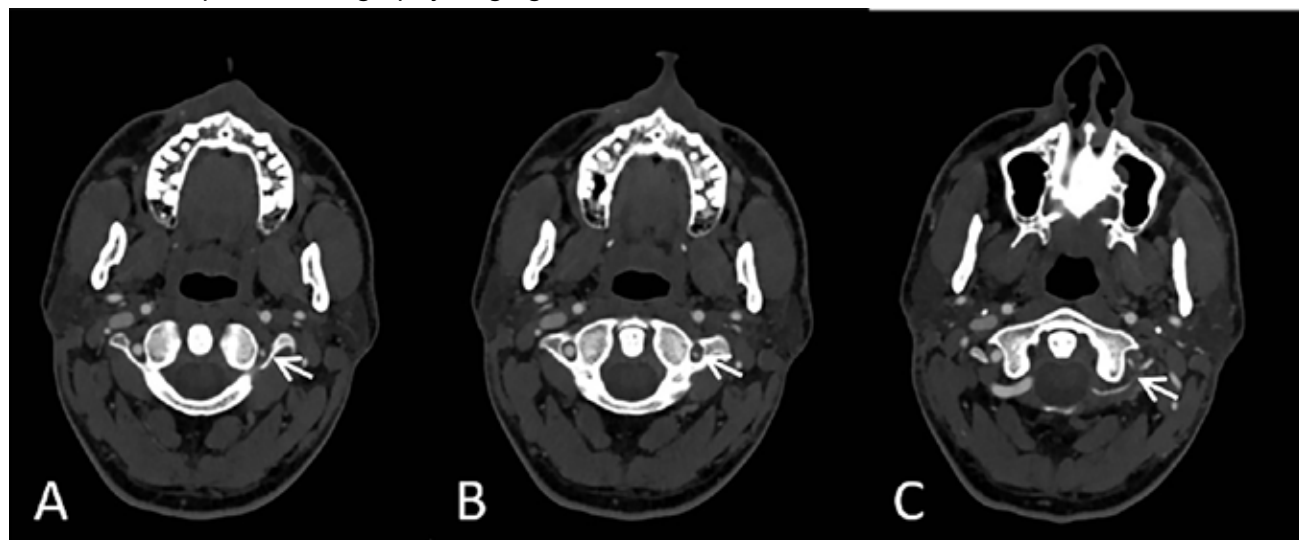
Once released, he attempted to stand and developed sudden onset vertigo with severe

nausea, leading to multiple bouts of emesis. He additionally developed a throbbing, left-sided headache radiating down the left side of his neck. While the vertigo resolved within an hour, he continued to experience bouts of nausea and emesis, prompting him to present to the ED for further evaluation. The patient's past medical history was remarkable only for multiple prior concussions, and his only medication was occasional ibuprofen. He denied the usage of recreational drugs.

Upon presentation to the ED, the patient's vital signs were 139/93 mm Hg blood pressure, 73 beats per minute heart rate, 16 breaths per minute respiration, 100% oxygen saturation on room air, and 97.7° F temperature. His general physical exam was remarkable for a well-appearing gentleman in no distress. He had no abnormal cardiopulmonary findings. On formal neurologic assessment, he was alert and oriented to person, place, time, and situation. His speech was of normal tempo and volume without dysarthria. The remainder of his cranial nerves were intact bilaterally. He had normal muscle bulk and tone as well as full strength in his upper and lower extremities. Testing of the patient's vibratory, pain, and temperature sensory functions disclosed no abnormalities. Cerebellar function testing was also within normal limits.

The patient demonstrated normal balance and exhibited no nystagmus or limb/truncal ataxia as evaluated with finger-to-nose/

**FIGURE 1** Computed Tomography Angiogram of Neck



Representative sequential axial cuts demonstrating hypoplastic but normal left vertebral artery; (A) with sequential cuts (B and C) demonstrating an abrupt decrease in caliber (white arrows indicate vascular irregularity).

heel-to-shin testing and gait exam. Complete blood count, comprehensive metabolic panel, and coagulation panel all demonstrated no abnormalities. A computed tomography (CT) angiogram of his head and neck was obtained, which demonstrated a possible left VAD vs an intraluminal thrombus. To clarify this finding, a brain and neck magnetic resonance (MR) angiogram was performed. This study was remarkable for an acute infarction within the left inferior cerebellar hemisphere in the distribution of the left posterior inferior cerebellar artery (PICA). Additionally, the MR angiogram demonstrated > 50% long segment luminal narrowing of the left V2-V4 vertebral artery segments extending from C2 to the confluence with the right vertebral artery. These findings were consistent with a left VAD, complicated by left cerebellar infarction (Figures 1, 2, and 3).

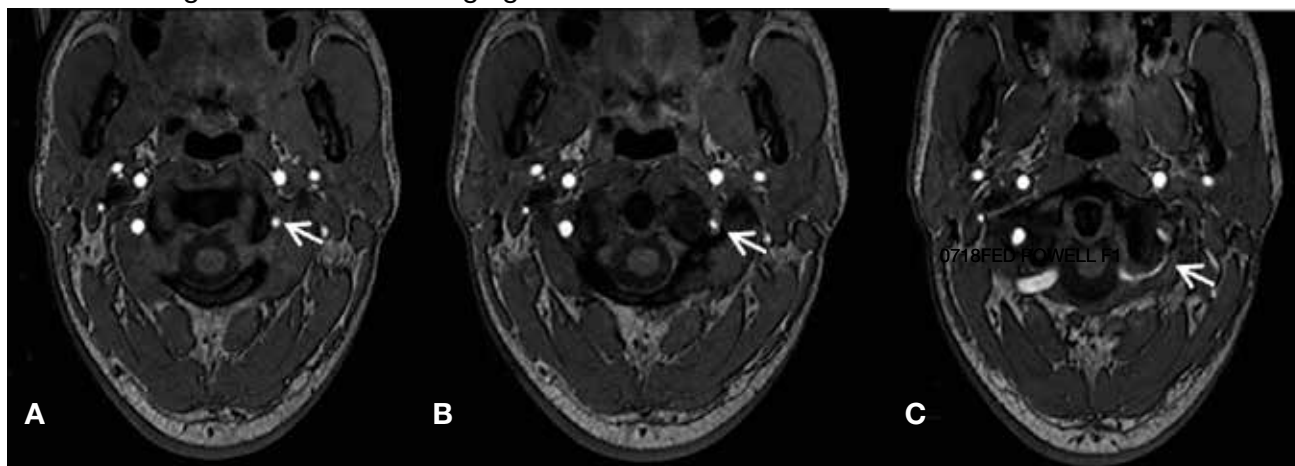
The patient was admitted to the hospital for symptom control and further monitoring. His headache and nausea were managed with medications, and he began antiplatelet therapy with aspirin 325 mg daily. Given the size of his cerebellar infarction, it was decided that he would be monitored in the hospital for 72 hours for the development of significant cerebellar edema. He remained stable throughout his hospitalization and had only a mild headache at the time of discharge.

The patient was last seen 3 months postinjury with no subjective complaints and a completely normal neurologic exam. The treatment plan for the patient is to continue aspirin for 6 months postinjury at which time a repeat CT will be performed to ensure resolution. He has been counseled to avoid heavy lifting and any activity with potential for sudden movement/force of the neck (grappling/wrestling, chiropractic manipulation, roller coasters, or sit-ups) until the repeat CT has been completed.

#### DISCUSSION

Spontaneous vertebral artery and carotid artery dissections are collectively referred to as sCADs. Spontaneous cervical artery dissections are a rare condition with a higher incidence of internal carotid dissections than are VADs (1.72 vs 0.97 per 100,000 people).<sup>1</sup> In contrast to the general stroke population, patients with sCADs are typically younger (mean age 45.3 years); and more than half of the patients are male.<sup>1,2</sup>

Spontaneous cervical artery dissections are typically characterized by subintimal tears of the vertebral artery leading to the accumulation of an intramural hematoma and creation of a “false lumen” in the arterial wall.<sup>3</sup> A sVAD is more often found in the pars transversaria (V2; 35%) or atlas loop (V3; 34%)

**FIGURE 2** Magnetic Resonance Angiogram of Neck

Sequential time of flight axial cuts of similar level to computed tomography angiogram demonstrating abrupt change from (A) hypoplastic but normal left vertebral artery to (B and C) smaller caliber and more irregular vessel in sequential cuts (white arrows consistent with dissection).

segments of the vertebral artery than in the prevertebral (V1; 20%) or intracranial (V4; 11%) segments.<sup>3-5</sup> The etiology of these injuries is thought to be minor trauma to the neck in the context of a likely underlying connective tissue disease, though no direct association with a particular disease has been shown.

Biopsy evaluation of the superficial temporal arteries of patients with sCADs have revealed pathologic changes of the media and adventitial layers, including vacuolar degeneration and capillary neoangiogenesis, which are not found in the arteries of control patients.<sup>5</sup> Although definitive association with a known connective tissue disease is rare, angiographic evidence of fibromuscular dysplasia, a nonspecific marker of connective tissue disease, is noted in as many as 15% to 20% of patients.<sup>6</sup> Consequently, routine connective tissue disease screening is not recommended in these patients. One study found that about 40% of sCAD patients can recall minor cervical trauma in the preceding month in comparison to only 10% of other patients with stroke, leading to the moniker of “bottoms-up” or “beauty-parlor strokes” for these injuries. The most common mechanisms of minor neck trauma causing sCADs include tennis and golf swings, yoga, and roller-coaster rides.<sup>7,8</sup>

Usually symptomatic at presentation, the most frequently encountered sCAD symp-

toms are head or neck pain (80%), brain ischemia (56%), and Horner syndrome (25%).<sup>1</sup> A study of 161 consecutive patients with internal carotid (n = 135) or vertebral artery (n = 26) dissections revealed that headache was reported by 69% of those with sVADs, and when present, was the initial manifestation in 33%. Headaches typically were ipsilateral to the dissection, located posteriorly in 83% of patients, and lasted an average duration of 72 hours. Neck pain, which was noted in 46% of sVAD patients, was predominantly posterior and ipsilateral in location as well.<sup>9</sup> Ischemic symptoms of sVAD may include posterior circulation symptoms, such as vertigo, ataxia, diplopia, and leg weakness as well as lateral medullary (Wallenberg) syndrome characterized by dizziness, postural instability, limb hypotonia/ataxia, blurred vision, and nystagmus.

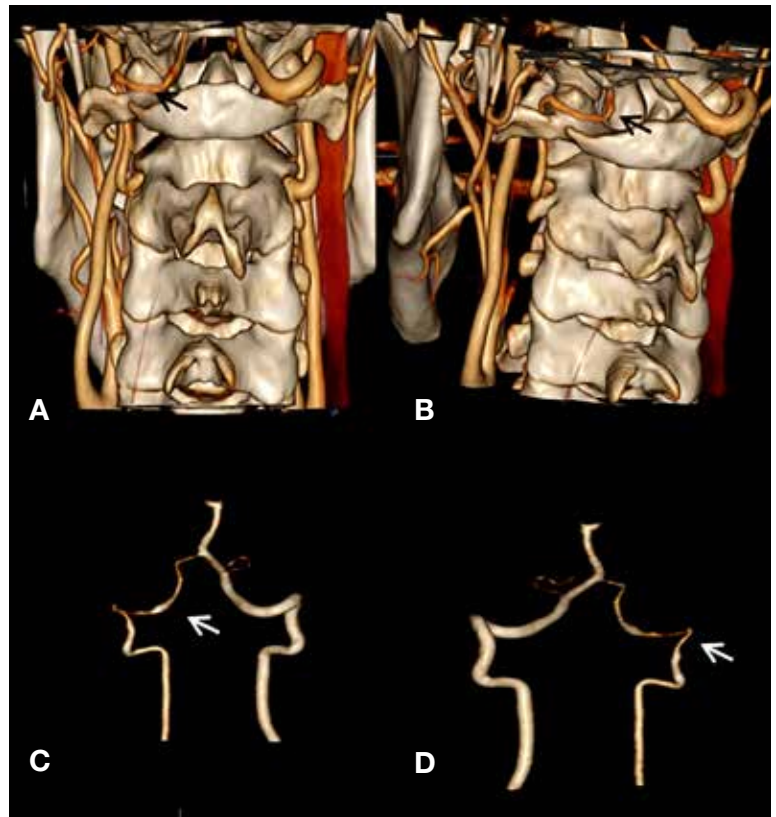
In a study of 169 patients with sCAD, brain ischemia occurred in 77% (131 patients) including 67% (n = 114) with ischemic stroke and 10% (n = 17) with transient ischemic attack. Head and/or neck pain was noted in 88% of those with brain ischemia.<sup>4</sup> Etiologies for infarction included thromboembolic (85%), hemodynamic (12%), and mixed (3%).<sup>10</sup> Isolated local symptoms are rare with one study of 245 patients with sCAD revealing only 20 (8%) presenting with pain only. Of those with pain only, 6 presented with headache, 2 with neck pain, and 12 with both.<sup>11</sup>

Diagnosis of sVAD requires a high index of suspicion and is confirmed by diagnostic testing. Previously, invasive angiography was the diagnostic gold standard, but with the improvement in quality of CT and MR angiography, these noninvasive modalities have become the tests of choice. There have been no studies to date revealing a definitive benefit of one modality over the other. A meta-analysis of 25 articles that compared the use of CT and MR angiography for the diagnosis of carotid and VAD revealed similar sensitivity and specificity.<sup>12</sup> In contrast, a study involving 10 patients with confirmed sVAD who had both CT and MR angiographies during evaluation showed more total findings consistent with dissection on CT than with MR angiography when graded by 2 neuroradiologists. Additionally, the neuroradiologists subjectively rated CT angiography as preferential to MR in showing the imaging findings of dissection in 8 of 10 cases of vertebral dissection.<sup>13</sup>

Treatment for sCAD remains heavily debated. The use of IV thrombolysis within the standard time window for acute ischemic stroke is advocated for these patients. A meta-analysis of patients with sCAD vs matched patients with stroke from other causes treated with IV thrombolysis showed no difference in mortality at 3 months (9.0% vs 8.8%) or symptomatic intracranial hemorrhage (3.3% vs 3.0%). Additionally, similar percentages of patients had excellent (30.9% vs 37.4%) and favorable (58.2% vs 52.2%) 3-month functional statuses as expressed by the Modified Rankin Score (mRS).<sup>14,15</sup>

Debate remains regarding subacute therapy for sCAD with either antiplatelet or anticoagulant therapy. A randomized study of 250 patients with cervical artery dissection (118 carotid, 132 vertebral) in which 126 patients were assigned to antiplatelet therapy and 124 patients were assigned to anticoagulant therapy showed an overall low rate of recurrent stroke (2%). There was no significant difference in efficacy between the therapy groups with stroke or death occurring in 3 antiplatelet patients and 1 anticoagulated patient. Adverse effects were very low in both groups with no deaths and only 1 major bleed in the anticoagulation group. Of note, stroke rates were lower in this study than

**FIGURE 3** Computer 3-D Reconstruction of Neck



(A and B) Computer 3-D reconstruction of the computed tomography angiogram more clearly demonstrates the left vertebral dissection from a posterior view (black arrows); computer 3-D reconstruction of the magnetic resonance angiogram, again, more clearly demonstrates the left vertebral dissection from both a posterior (C) and anterior (D) view (white arrows).

prior observational studies.<sup>16</sup>

A nonrandomized study of 88 patients with extracranial sCAD showed overall low rates of recurrent ischemic stroke at 3 months with 1/59 (1.7%) in the antiplatelet group and 1/28 (3.6%) in the anticoagulation group ( $P < .001$ ). The meta-analysis portion of this study added these findings to previous nonrandomized studies and again showed no difference in recurrent stroke with 13 of 499 (2.6%) in the antiplatelet group and 20 of 1137 (1.8%) in the anticoagulation group (odds ratio 1.49).<sup>17</sup> Given this low overall rate of recurrent stroke in prior studies, a guideline recommendation for antiplatelet or anticoagulant therapy cannot be made at this time.

The overall prognosis for this condition is fair. Functional status and recurrence risk

are favorable, with one study finding a mRS score of < 2 in 92% of patients at 1 year.<sup>1</sup> Additionally, a historic cohort study of 432 patients with first event of sCAD revealed that after a mean follow-up of 31 months, only 4 (0.9%) patients had a recurrent ischemic stroke either due to incomplete recanalization of the artery (n = 2) or recurrent sCAD (n = 2), and only 4 (0.9%) total recurrences of sCAD were reported (2 without associated ischemic strokes).<sup>18</sup> Further, a prospective study of 61 patients with confirmed sVAD revealed complete recanalization of 45.9% at 3 months, 62.3% at 6 months, and 63.9% at 12 months, suggesting that recanalization occurs mostly during the initial 6 months. There was no identified association between outcome and complete recanalization with favorable outcomes observed in 55 (90.2%) of patients and no further ischemic symptoms during follow-up.<sup>19</sup>

Neck maneuvers have been cited as a more common cause of sCAD in several previous studies. One retrospective study found chiropractic neck manipulation to be the etiology in 12 of 141 patients with CT- or MR- confirmed sCAD.<sup>20</sup> As noted previously, to the authors' knowledge this is the first reported case of a sVAD occurring after a mixed martial arts choke hold. While sports-related strokes are rare, one evaluation of 70 published cases found that 80% were due to sCAD. Commonly associated sports in this study included football, yoga, wrestling, tennis, golf, and swimming.<sup>21</sup> Grappling-related neck manipulation has been noted as an etiology in a few case reports.

Hyperextension of the neck was deemed to be the etiology in boys aged 11 years and 17 years who developed a sCAD while participating in Judo and backyard wrestling, respectively.<sup>22,23</sup> In the martial arts realm, there is a case report of a 26-year-old male who developed a sVAD after rapid head turning during a solo Kung Fu maneuver as well as a report of a 41-year-old male experiencing a right VAD complicated by a posterior infarction several days after straining his neck during a mixed martial arts competition.<sup>24,25</sup> The patient denied any choke hold or direct blow to the neck.

The present case is different in that it is the first reported case of a sVAD occurring

after a submission maneuver. Prior grappling-related sVADs were associated with hyperextension or rapid acceleration/deceleration forces on the neck. Isometric force to the neck is a rarely described mechanism for development of this injury. Although there are isolated and infrequent forensic case reports of carotid dissection with strangulation injuries, the authors believe this is the first documented case of a sVAD attributed to a combatives submission.

In the context of the military health system, it is important to be aware of this potential complication of combatives as instruction in close-quarters combat continues to be an important part of military training.

### Author disclosures

The authors report no actual or potential conflicts of interest with regard to this article.

### Disclaimer

The opinions expressed herein are those of the authors and do not necessarily reflect those of *Federal Practitioner*, Frontline Medical Communications Inc., the US Government, or any of its agencies. This article may discuss unlabeled or investigational use of certain drugs. Please review the complete prescribing information for specific drugs or drug combinations—including indications, contraindications, warnings, and adverse effects—before administering pharmacologic therapy to patients.

### References

1. Lee VH, Brown RD Jr, Mandrekar J, Mokri B. Incidence and outcome of cervical artery dissection: a population-based study. *Neurology*. 2006;67(10):1809-1812.
2. Arnold M, Kappeler L, Georgiadis D, et al. Gender differences in spontaneous cervical artery dissection. *Neurology*. 2006;67(6):1050-1052.
3. Schvink W. Spontaneous dissection of the carotid and vertebral arteries. *N Engl J Med*. 2001;344(12):898-906.
4. Arnold M, Bousser MG, Fahrni G, et al. Vertebral artery dissection: presenting findings and predictors of outcome. *Stroke*. 2006;37(10):2499-2503.
5. Völker W, Dittrich R, Grewe S, et al. The outer arterial wall layers are primarily affected in spontaneous cervical artery dissection. *Neurology*. 2011;76(17):1463-1471.
6. Debette S, Markus HS. The genetics of cervical artery dissection: a systematic review. *Stroke*. 2009;40(6):459-466.
7. DeBehnke D, Brady W. Vertebral artery dissection due to minor neck trauma. *J Emerg Med*. 1994;12(1):27-31.
8. Engelter ST, Grond-Ginsbach C, Metso TM, et al; Cervical Artery Dissection and Ischemic Stroke Patients Study Group. Cervical artery dissection: trauma and other potential mechanical trigger events. *Neurology*. 2013;80(21):1950-1957.
9. Silbert PL, Mokri B, Schvink WI. Headache and neck pain in spontaneous internal carotid and vertebral artery dissections. *Neurology*. 1995;45(8):1517-1522.
10. Morel A, Naggara O, Touzé E, et al. Mechanism of ischemic infarct in spontaneous cervical artery dissection. *Stroke*. 2012;43(5):1354-1361.
11. Arnold M, Cumurciuc R, Stapf C, Favrole P, Berthet K, Bousser MG. Pain as the only symptom of cervical artery dissection. *J Neurol Neurosurg Psychiatry*.

- 2006;77(9):1021-1024.
12. Provenzale J, Sarikaya B. Comparison of test performance characteristics of MRI, MR angiography, and CT angiography in the diagnosis of carotid and vertebral artery dissection: a review of the medical literature. *AJR Am J Roentgenol*. 2009;193(4):1167-1174.
  13. Vertinsky AT, Schwartz NE, Fishbein NJ, Rosenberg J, Albers GW, Zaharchuk G. Comparison of multidetector CT angiography and MR imaging of cervical artery dissection. *AJNR Am J Neuroradiol*. 2008;29(9):1753-1760.
  14. Zinkstok SM, Vergouwen MD, Engelter ST, et al. Safety and functional outcome of thrombolysis in dissection-related ischemic stroke: a meta-analysis of individual patient data. *Stroke*. 2011;42(9):2515-2520.
  15. Engelter S, Rutgers M, Hatz F, et al. Intravenous thrombolysis in stroke attributable to cervical artery dissection. *Stroke*. 2009;40(12):3772-3776.
  16. CADISS trial investigators, Markus HS, Hayter E, et al. Antiplatelet treatment compared with anticoagulation treatment for cervical artery dissection (CADISS): a randomized trial. *Lancet Neurol*. 2015;14(4):361-367.
  17. Kennedy F, Lanfranconi S, Hicks C, et al; CADISS Investigators. Antiplatelets vs. anticoagulation for dissection: CADISS nonrandomized arm and meta-analysis. *Neurology*. 2012;79(7):686-689.
  18. Touze E, Gauvrit JY, Moulin T, Meder JF, Bracard S, Mas JL; Multicenter Survey on Natural History of Cervical Artery Dissection. Risk of stroke and recurrent dissection after a cervical artery dissection: a multicenter study. *Neurology*. 2003;61(10):1347-1351.
  19. Arauz A, Marquez J, Artigas C, Balderrama J, Orrego H. Recanalization of vertebral artery dissection. *Stroke*. 2010;41(4):717-721.
  20. Kennell KA, Daghfal MM, Patel SG, et DeSanto JR, Waterman GS, Bertino RE. Cervical artery dissection related to chiropractic manipulation: one institution's experience. *J Fam Pract*. 2017;66(9):556-562.
  21. McCrory P. Vertebral artery dissection causing stroke in sport. *J Clin Neurosci*. 2000;7(4):298-300.
  22. Lannuzel A, Moulin T, Amsallem D, Galmiche J, Rumbach L. Vertebral artery dissection following a judo session: a case report. *Neuropediatrics*. 1994;25(2):106-108.
  23. Gupta V, Dhawan N, Bahl J. Minor trauma causing stroke in a young athlete. *Case Rep Neurol Med*. 2015;2015:182875.
  24. Pacey F, Valvasorri L, Bet L. Vertebral artery dissection during Kung-Fu training. *Neurol Sci*. 2014;35(2):331-332.
  25. Slowey M, Maw G, Furyk J. Case report on vertebral artery dissection in mixed martial arts. *Emerg Med Australas*. 2012;24(2):203-206.