

Carcinoma Erysipeloides of Papillary Serous Ovarian Cancer Mimicking Cellulitis of the Abdominal Wall

Vivian Wong, MD, PhD; Carol E. Cheng, MD; Steven R. Tahan, MD; Caroline C. Kim, MD

PRACTICE POINTS

- Carcinoma erysipeloïdes is a rare cutaneous marker of metastatic ovarian cancer.
- Clinicians should be aware of carcinoma erysipeloïdes in ovarian cancer and maintain a low threshold for biopsy for accurate diagnosis and management planning.

To the Editor:

A 40-year-old woman with a history of stage IIIC ovarian cancer presented with progressing abdominal erythema and pain of 1 month's duration. She had been diagnosed 4 years prior with grade 3, poorly differentiated papillary serous carcinoma involving the bilateral ovaries, uterine tubes, uterus, and omentum with lymphovascular invasion. She underwent tumor resection and debulking followed by paclitaxel plus platinum-based chemotherapy. The cancer recurred 2 years later with carcinomatous ascites. She declined chemotherapy but underwent therapeutic paracentesis.

One month prior to presentation, the patient developed a small, tender, erythematous patch on the abdomen. Her primary physician started her on cephalexin for presumed cellulitis without improvement. The erythema continued to spread on the abdomen with worsening pain, which prompted her presentation to the emergency department. She was admitted and started on intravenous vancomycin.

On admission to the hospital, the patient was cachexic and afebrile with a white blood cell count of 10,400/ μ L

(reference range, 4500–11,000/ μ L). Physical examination revealed a well-demarcated, 15×20-cm, erythematous, blanchable, indurated plaque in the periumbilical region (Figure 1). The plaque was tender to palpation with guarding but no increased warmth. Punch biopsies of the abdominal skin revealed carcinoma within the lymphatic channels in the deep dermis and dilated lymphatics throughout the overlying dermis (Figure 2). These findings were diagnostic for carcinoma erysipeloïdes. Tissue and blood cultures were negative for bacterial, fungal, or mycobacterial growth. Vancomycin was discontinued,

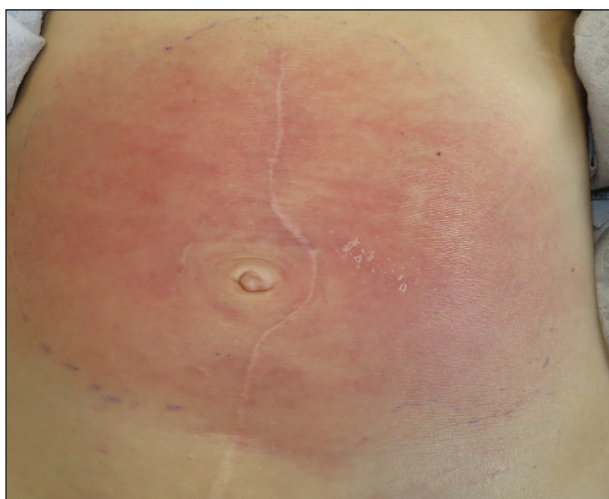

FIGURE 1. A well-demarcated, 15×20-cm, erythematous, blanching, indurated plaque on the periumbilical area that was diagnosed as carcinoma erysipeloïdes.

Dr. Wong is from the Department of Dermatology, Brown University, Providence, Rhode Island. Dr. Cheng is from the Department of Medicine, Division of Dermatology, David Geffen School of Medicine, University of California Los Angeles. Drs. Tahan and Kim are from Harvard Medical School, Beth Israel Deaconess Medical Center, Boston, Massachusetts. Dr. Tahan is from the Department of Pathology and Dr. Kim is from the Department of Dermatology.

The authors report no conflict of interest.

Correspondence: Caroline C. Kim, MD, Beth Israel Deaconess Medical Center, Department of Dermatology, 330 Brookline Ave, Shapiro 2, Boston, MA 02215 (ckim3@bidmc.harvard.edu).

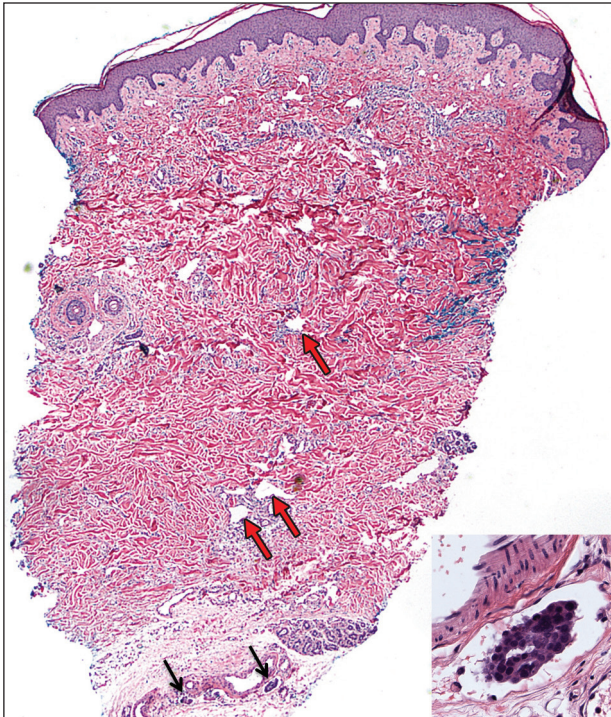


FIGURE 2. A punch biopsy of a carcinoma erysipeloïdes revealed carcinoma cells morphologically consistent with papillary serous carcinoma of the ovaries present within the lymphatic channels in the deep dermis, as seen in the inset (single arrows). Lymphatic channels in the overlying dermis were dilated (red arrows), suggesting lymphatic obstruction (H&E, original magnification $\times 20$; inset, original magnification $\times 200$).

and she was discharged with pain medication. She declined chemotherapy due to the potential side effects and elected to continue symptomatic management with palliative paracentesis. After she was discharged, she underwent a tunneled pleural catheterization for recurrent malignant pleural effusions.

Carcinoma erysipeloïdes is a rare cutaneous metastasis secondary to internal malignancy that presents as well-demarcated areas of erythema and is sometimes misdiagnosed as cellulitis or erysipelas. Histology is notable for lymphovascular congestion without inflammation. Carcinoma erysipeloïdes most commonly is associated with breast cancer, but it also has been described in cancers of the prostate, larynx, stomach, lungs, thyroid, parotid gland, fallopian tubes, cervix, pancreas, and metastatic melanoma.¹⁻⁵ While the pathogenesis of carcinoma erysipeloïdes is poorly understood, it is thought to

occur by direct spread of tumor cells from the lymph nodes to the cutaneous lymphatics, causing obstruction and edema.

Ovarian cancer has the highest mortality of all gynecologic cancers and often is associated with delayed diagnosis. Cutaneous metastasis is a late manifestation often presenting as subcutaneous nodules.^{6,7} Carcinoma erysipeloïdes is an even rarer presentation of ovarian cancer, with a poor prognosis and a median survival of 18 months.⁸ A PubMed search of articles indexed for MEDLINE using the term *carcinoma erysipeloïdes* revealed 9 cases of carcinoma erysipeloïdes from ovarian cancer: 1 describing erythematous papules, plaques, and zosteriform vesicles on the upper thighs to the lower abdomen,⁹ and 8 describing erythematous plaques on the breasts.^{8,10} We report a case of carcinoma erysipeloïdes associated with stage IIIc ovarian cancer localized to the abdominal wall mimicking cellulitis. Our report reminds clinicians of this important diagnosis in ovarian cancer and of the importance of a skin biopsy to expedite a definitive diagnosis. Immunohistochemistry using ovarian tumor markers (eg, paired-box gene 8, cancer antigen 125) is an additional tool to accurately identify malignant cells in skin biopsy.^{8,10} Once diagnosed, primary treatment for carcinoma erysipeloïdes is treatment of the underlying malignancy.

REFERENCES

1. Cormio G, Capotorto M, Di Vagno G, et al. Skin metastases in ovarian carcinoma: a report of nine cases and a review of the literature. *Gynecol Oncol.* 2003;90:682-685.
2. Kim MK, Kim SH, Lee YY, et al. Metastatic skin lesions on lower extremities in a patient with recurrent serous papillary ovarian carcinoma: a case report and literature review. *Cancer Res Treat.* 2012;44:142-145.
3. Karmali S, Rudmik L, Temple W, et al. Melanoma erysipeloïdes. *Can J Surg.* 2005;48:159-160.
4. Godinez-Puig V, Frangos J, Hollmann TJ, et al. Carcinoma erysipeloïdes of the breast in a patient with advanced ovarian carcinoma. *Clin Infect Dis.* 2012;54:575-576.
5. Hazelrigg DE, Rudolph AH. Inflammatory metastatic carcinoma. carcinoma erysipeloïdes. *Arch Dermatol.* 1977;113:69-70.
6. Cowan LJ, Roller JJ, Connelly PJ, et al. Extraovarian stage IV peritoneal serous papillary carcinoma presenting as an asymptomatic skin lesion—a case report and literature review. *Gynecol Oncol.* 1995;57:433-435.
7. Schonmann R, Altaras M, Biron T, et al. Inflammatory skin metastases from ovarian carcinoma—a case report and review of the literature. *Gynecol Oncol.* 2003;90:670-672.
8. Klein RL, Brown AR, Gomez-Castro CM, et al. Ovarian cancer metastatic to the breast presenting as inflammatory breast cancer: a case report and literature review. *J Cancer.* 2010;1:27-31.
9. Lee HC, Chu CY, Hsiao CH. Carcinoma erysipeloïdes from ovarian clear-cell carcinoma. *J Clin Oncol.* 2007;25:5828-5830.
10. Godinez-Puig V, Frangos J, Hollmann TJ, et al. Photo quiz. rash in a patient with ovarian cancer. *Clin Infect Dis.* 2012;54:538, 575-576.