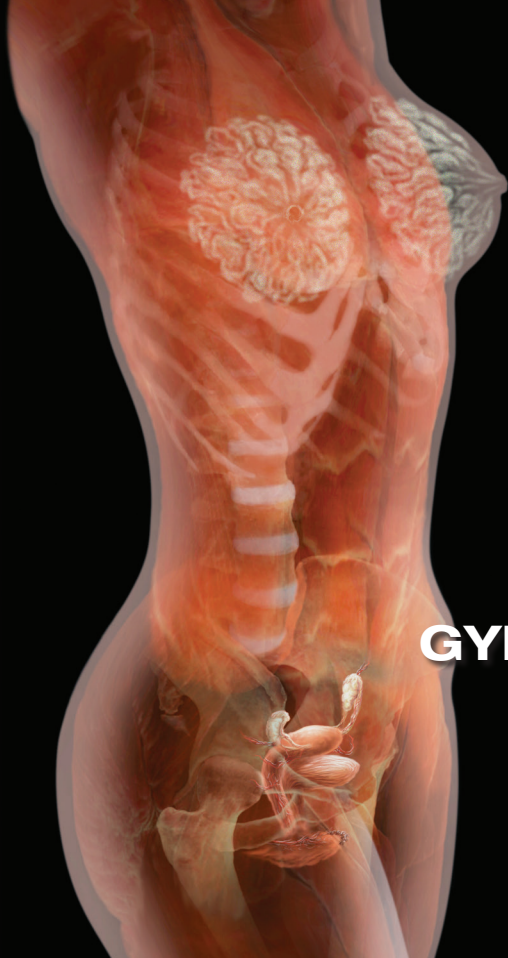



**HIGHLIGHTS FROM
THE 2018 SOCIETY OF
GYNECOLOGIC SURGEONS
SCIENTIFIC MEETING
PART 1**

Andrew P. Cassidenti, MD

Chief, Female Pelvic Medicine
and Reconstructive Surgery
Kern Medical
Bakersfield, California

Amanda White, MD

Associate Professor, Department of Women's Health
Female Pelvic Medicine and Reconstructive Surgery
Dell Medical School, University of Texas
Austin, Texas

Vivian Aguilar, MD

Associate Professor, Obstetrics and Gynecology
Female Pelvic Medicine and Reconstructive Surgery
Dell Medical School, University of Texas
Austin, Texas

Rebecca G. Rogers, MD

Professor, Department of Women's Health
Female Pelvic Medicine and Reconstructive Surgery
Associate Chair, Clinical Integrations and Operations
Dell Medical School, University of Texas
Austin, Texas

Sarah Huber, MD

Fellow, Female Pelvic Medicine
and Reconstructive Surgery
Department of Urology
Weill Cornell Medical College
New York Presbyterian/Weill Cornell Medical Center
New York, New York

Patrick Culligan, MD

Professor, Gynecology and Urology
Director, Urogynecology and
The Center for Female Pelvic Health
Department of Urology
Weill Cornell Medical College
New York Presbyterian/Weill Cornell Medical Center
New York, New York

Vincent R. Lucente, MD, MBA

Chief, Gynecology
St. Luke's University Health Network
Medical Director, The Institute for Female Pelvic
Medicine and Reconstructive Surgery
Allentown, Pennsylvania

Jessica B. Ton, MD

AAGL Fellow, Minimally Invasive Gynecologic Surgery
St. Luke's University Health Network
Bethlehem, Pennsylvania

James I. Merlino, MD

President and Chief Medical Officer
of Advisory and Strategic Consulting
Press Ganey Associates
Cleveland, Ohio

Amy A. Merlino, MD

Maternal Fetal Medicine Specialist
Department of Obstetrics and Gynecology
Enterprise Chief Medical Information Officer
Cleveland Clinic
Cleveland, Ohio

Leading best gynecologic surgical care into the next decade

Leadership was the theme at the annual meeting of the Society of Gynecologic Surgeons (SGS). We begin this special section with leading features on managing pelvic organ prolapse and patient experience.

Andrew P. Cassidenti, MD

With today's rapid health care transformation from fee for service to fee for value, it is imperative that gynecologic surgeons understand, engage in, and lead this transformation. The value equation is defined as patient experience times clinical outcome divided by cost. This 2-part special issue highlights some of the key content shared at the 2018 SGS annual meeting, held in Orlando, Florida, to help you engage and lead.

The keynote address was "Patient Experience: It is not about making people happy" and was presented by James Merlino, MD (author of *Service Fanatics: How to Build Superior Patient Experience the Cleveland Clinic Way*), who is former Chief Experience Officer and colorectal surgeon at the Cleveland Clinic and currently President and Chief Medical Officer, Strategic Consulting at Press Ganey. Dr. Merlino clearly defines that the patient experience is really about patient safety and quality. He shares practical tips to help physicians improve communication with patients, which not only increases patient satisfaction but also physician satisfaction. His wife Amy Merlino, MD, an ObGyn, coauthored the piece with him and shares their journey to implement programs that were impactful and designed to create greater personal appreciation and mindfulness of physicians' clinical work.

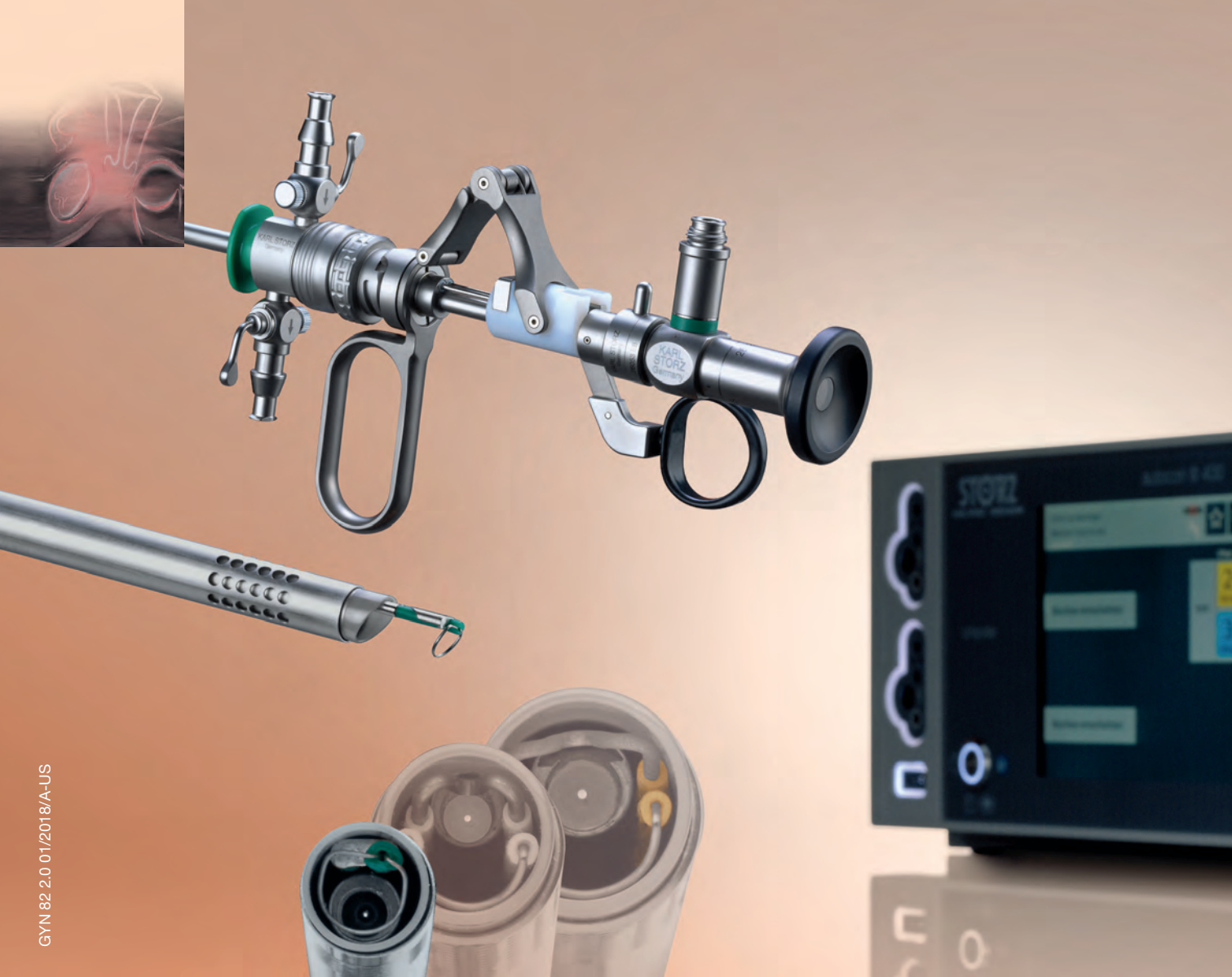Optimal surgical outcomes delivered at lowest

The author reports that he has served as a consultant and proctor for Astora Women's Health and as an expert witness for Boston Scientific in the mesh litigation.

cost are the other key components of value health care. Endometriosis and the management of stage 3 and 4 pelvic organ prolapse remain challenging clinical scenarios that we face often. Rosanne Kho, MD, and colleagues taught a postgraduate course on contemporary management of deep infiltrating endometriosis and, in part 2 of this special section, share key highlights and pearls from that course. A highpoint of the meeting was a debate on the optimal management of stage 3 and 4 pelvic organ prolapse. Peter Rosenblatt, MD, moderated a lively discussion involving Rebecca Rogers, MD, who advocated for native tissue repair; Patrick Culligan, MD, who promoted abdominal sacrocolpopexy; and Vincent Lucente, MD, backing transvaginal mesh. They summarize their arguments beginning on page SS4 for you to decide.

Lastly, with increasing demand for minimally invasive hysterectomy, many surgeons could benefit from simulation training to enhance their practice, hone up on skills, and provide warm-up to sharpen technical skills prior to the day in the operating room. Simulation training improves patient safety and outcomes and lowers cost. Simulation training is also key in training residents and fellows. Christine Vaccaro, MD, and colleagues taught a postgraduate course on what is new in simulation training for hysterectomy and summarize important technologies in part 2 of this special section.

I hope you enjoy the content of this special section and find it impactful to your practice and future. ■



GYN 82.2.0.01/2018/A-US

Perfection in Resection –

NEW 15 Fr. – clinical outpatient setting and office resectoscope, extending the set together with 22 Fr., and 26 Fr.

Visit us at ACOG, Booth #10032, or for more information call 1-800-421-0837

STORZ
KARL STORZ – ENDOSKOPE

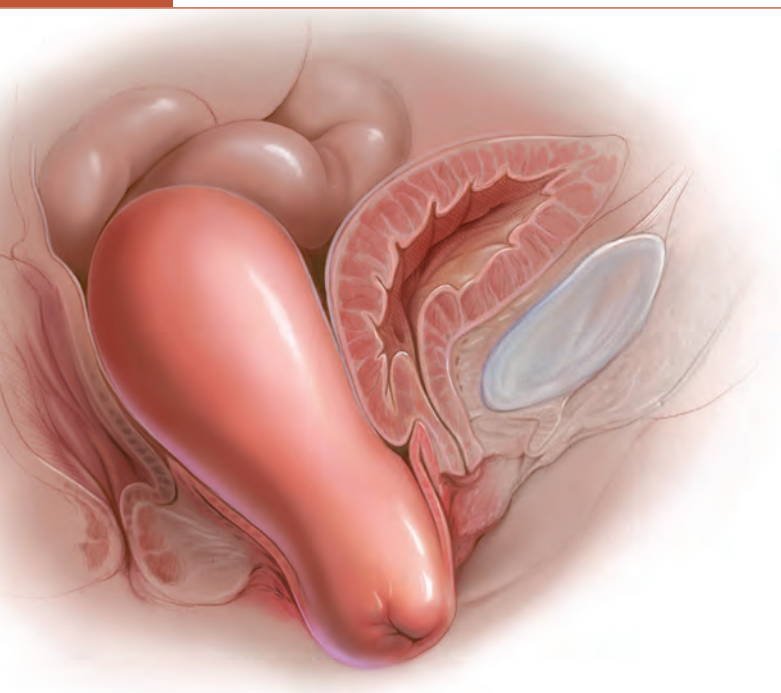
THE DIAMOND STANDARD

KARL STORZ SE & Co. KG, Dr.-Karl-Storz-Straße 34, 78532 Tuttlingen/Germany
KARL STORZ Endoscopy-America, Inc. 2151 East Grand Avenue El Segundo, CA 90245-5017/USA
www.karlstorz.com

DEBATE

Optimal surgical management of stage 3 and 4 pelvic organ prolapse

What the evidence and the experts say about the various approaches for prolapse repair



Effective surgical management of advanced pelvic organ prolapse (POP) depends on prolapse location and stage, presence of urinary incontinence, need for hysterectomy, the patient's desire to maintain sexual function, type of surgery, and the surgeon's skill and experience, among other factors. For these reasons, POP repair is not a one-size-fits all procedure.

In this article, experts in minimally invasive prolapse repair offer their perspectives on 3 surgical approaches: use of native tissue (Drs. White, Aguilar, and Rogers), abdominal sacrocolpopexy (Drs. Huber and Culligan), and transvaginal mesh (Drs. Lucente and Ton). They evaluate the evidence on these procedures and provide recommendations based on their experience of best practices for achieving surgical success and minimizing adverse events.

Bonus: See instructive videos of several surgical techniques described in the article online at www.mdedge.com/obgmanagement.

Using native tissue for vaginal anatomy repair

Amanda White, MD; Vivian Aguilar, MD; and Rebecca G. Rogers, MD

Surgical therapy is the mainstay of treatment for POP, and 20% of US women will undergo prolapse and/or stress incontinence surgery by age 80.¹ Prolapse surgery either restores the vaginal anatomy (reconstructive surgery) or obliterates the vaginal canal (obliterative surgery). Vaginal reconstruction can be performed

Dr. Rogers reports that she receives royalties from UpToDate. Drs. White and Aguilar report no financial relationships relevant to this article.

using the patient's native tissue or mesh. Because of concerns associated with mesh use, native tissue repairs continue to be commonly performed.

Unfortunately, not all prolapse surgeries result in prolapse cure, and recurrent prolapse that necessitates repeat operation is not rare, regardless of whether or not mesh is used.^{2,3} Native tissue repairs are most commonly performed through the vaginal route, the first minimally invasive approach to

prolapse surgery. Restoration of the vaginal apex has been identified as critically important in these surgeries. Apical native tissue repairs include reconstructive procedures, such as sacrospinous ligament suspension (SSLS) or uterosacral ligament suspension (USLS), and obliterative procedures, such as colpocleisis.

In this discussion, we present 2 case vignettes that highlight surgical decision making for repair of stage 3 or 4 pelvic organ prolapse utilizing these techniques.

CASE 1 Active woman with prolapse

A 65-year-old woman (G2P2) presents with stage 3 prolapse, with the anterior compartment at +3 and the cervix at the hymen with straining. She is sexually active and desires to retain coital function. A trial of pessary has failed.

What surgical options can be considered for this patient?

Reconstruction procedures for prolapse

This patient presents with a typical configuration of prolapse; the anterior and apical compartments are the most likely to prolapse.⁴ Importantly, conservative management of her prolapse has failed. While it is not required that women have a trial with pessary prior to undergoing surgery, all women should be offered conservative management of prolapse, according to the American Urogynecologic Society (AUGS) and the American College of Obstetricians and Gynecologists (ACOG).^{4,5}

Apical suspension

Since this patient desires to retain coital function, her gynecologist recommends a reconstructive procedure. The combination of apical and anterior vaginal wall prolapse will require an apical suspension procedure (**FIGURES 1** and **2**, page SS6). If suspension of the apex does not correct the anterior wall prolapse, the patient also may require anterior compartment reconstruction.

The 2 most commonly performed native tissue apical suspension procedures, SSLS and USLS, have equivalent outcomes at 2 years, according to a multicenter randomized trial.⁶ Therefore, the choice of procedure is at the surgeon's discretion. USLS is most commonly performed at the time of hysterectomy via an intraperitoneal approach,

Take-home points

- Native tissue repair offers a minimally invasive approach to prolapse repair.
- Sacrospinous and uterosacral ligament suspensions have equivalent success rates.
- Prophylactic midurethral slings reduce postoperative incontinence at the time of transvaginal native tissue repair.
- Hysterectomy at the time of colpocleisis should not be performed routinely.

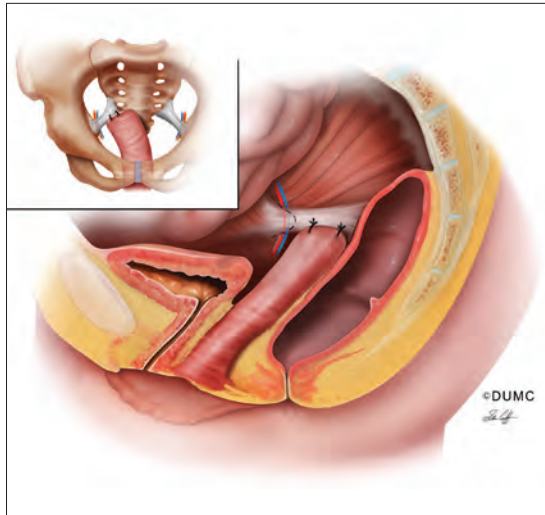
while SSLS is often selected for posthysterectomy vault prolapse, given its extraperitoneal location.

Suture type. Whether to use permanent suture at the time of SSLS or USLS is controversial. Some data suggest that permanent suture provides greater long-term success compared with delayed absorbable suture.⁷ However, permanent suture has been reported to be associated with higher rates of suture complications—up to 44% in USLS and 36% in SSLS—compared with a 3.5% complication rate in a USLS cohort treated with absorbable suture.⁸⁻¹⁰

Hysterectomy versus hysteropexy. Considerable debate exists regarding whether a patient requires hysterectomy at the time of prolapse repair. In a randomized trial at 12 months' follow-up, uterine preservation by sacrospinous hysteropexy was noninferior to vaginal hysterectomy with suspension of the uterosacral ligaments for surgical failure of the apical compartment.¹¹ A recent meta-analysis found that apical failure rates after sacrospinous hysteropexy versus vaginal hysterectomy were not different.¹² Repeat surgery rates for prolapse also were not different between groups. The most significant disadvantage of uterine-preservation prolapse surgery, when compared with hysterectomy, is the lack of prevention and diagnosis of uterine malignancy.¹² From 2002 to 2012, rates of hysteropexy significantly increased in the United States, although rates remain low.¹³

Sling procedure pros and cons. This case patient did not report urinary incontinence, but she may develop incontinence with reduction of the anterior wall prolapse. A large randomized controlled trial that included 337 women compared sling with no sling procedures among women with prolapse undergoing transvaginal prolapse

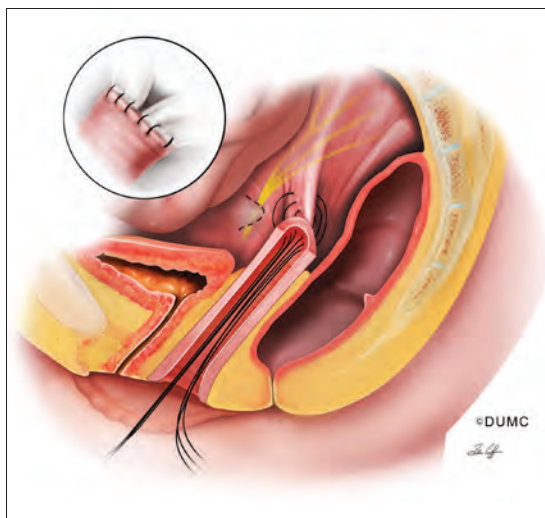
FIGURE 1 Prolapse repair with sacrospinous ligament fixation



Sacrospinous ligament fixation attaches the vaginal apex to the unilateral or bilateral sacrospinous ligament(s) using absorbable or nonabsorbable suture. Care must be taken to avoid the pudendal nerve, artery, and vein.

SOURCE: Siddiqui NY, Edenfield AL. Clinical challenges in the management of vaginal prolapse. *Int J Womens Health*. 2014;6:83–94. Used with permission.

FIGURE 2 Prolapse repair with uterosacral ligament suspension



Uterosacral ligament suspension attaches the vaginal apex to the bilateral uterosacral ligaments above the level of the ischial spine using absorbable or nonabsorbable suture.

SOURCE: Siddiqui NY, Edenfield AL. Clinical challenges in the management of vaginal prolapse. *Int J Womens Health*. 2014;6:83–94. Used with permission.

repair.¹⁴ Management with a prophylactic sling resulted in less incontinence (27.3% and 43.0%, respectively, at 12 months postoperatively) but higher rates of urinary tract infection (31.0% vs 18.3%), major bleeding complications (3.1% vs 0%), and incomplete bladder emptying 6 weeks after surgery (3.7% vs 0%) ($P \leq .05$ for all).¹⁴

CASE 1 Recommendations for this patient

For this case, we would offer the patient a transvaginal hysterectomy and USLS. At the time of repair, we would assess whether she needed an anterior repair as well. We would offer a prophylactic sling procedure and also would discuss the risks and benefits of concomitant versus interval incontinence procedures.

CASE 2 Elderly woman with severe prolapse

An 85-year-old woman (G3P3) presents with procidentia, or complete eversion of the vagina, with the cervix 10 cm outside of the hymen. She has difficulty voiding, and the prolapse is uncomfortable when walking. A trial of pessary has failed. The patient denies vaginal bleeding. She is not sexually active and does not desire to retain coital function.

What treatment options would be appropriate for this patient?

Obliterative surgery

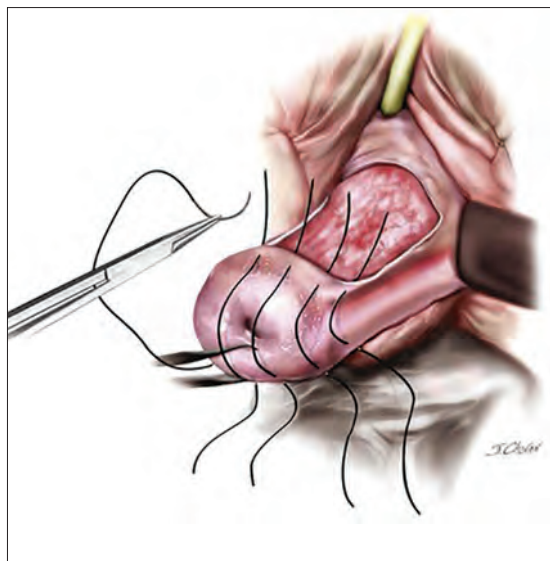
This elderly patient presents with advanced pelvic organ prolapse, and conservative management has failed. She is not sexually active and does not desire coital function in the future, so an obliterative procedure is indicated. Colpocleisis is a minimally invasive procedure that has cure rates ranging from 91% to 100%.¹⁵ It is likely that this patient's voiding dysfunction will improve after surgery and that she will be highly satisfied with the surgery.¹⁶

The question of hysterectomy with colpocleisis

The role of hysterectomy at the time of colpocleisis is controversial. LeFort colpocleisis preserves the uterus, with the anterior and posterior vaginal walls sutured together (**FIGURE 3**). Hysterectomy at the time of vaginal closure increases the operative time and blood loss.¹⁵ On the other hand, closure without hysterectomy prohibits future endometrial or cervical cancer screening.

In a recent review using the American College of Surgeons National Surgical Quality Improvement Program database, investigators compared

FIGURE 3 LeFort colpocleisis for prolapse repair



Rectangular shaped areas of prolapsed vaginal epithelium are removed prior to imbrication and perineorrhaphy in the obliterative procedure LeFort colpocleisis.

SOURCE: Baggish MS, Karram MM. Atlas of pelvic anatomy and gynecologic surgery. 3rd ed. St Louis, MO: Elsevier Saunders; 2011. Used with permission.

women who underwent colpocleisis alone with those who underwent colpocleisis with hysterectomy.¹⁷ They found that the incidence of major complications was greater among women who underwent concomitant hysterectomy, and they concluded that hysterectomy should not be performed routinely at the time of colpocleisis.¹⁷

Among 322 urogynecologists who responded to a web-based survey, only 18% routinely performed hysterectomy at the time of colpocleisis.¹⁸ Further, in a decision analysis model, the utility for colpocleisis without hysterectomy was higher in women older than age 40, suggesting that hysterectomy should be performed only in special circumstances.¹⁹

Evaluating the endometrium. If the uterus remains in situ, should endometrial evaluation be performed? If so, should ultrasonography or endometrial biopsy be used? Authors of a decision analysis model found that among women at low risk for cancer and without abnormal uterine bleeding, endometrial biopsy was not favored until the probability of cancer reached 64%.²⁰ Specifically,

no evaluation or evaluation by transvaginal ultrasonography is adequate in the majority of cases.²⁰ When screened by transvaginal ultrasonography, the high, 99% negative predictive value for endometrial disease, using a cutoff value of 5 mm for endometrial stripe width, will allow most patients to avoid unnecessary tissue sampling.

Stress incontinence. It is likely that this patient's voiding dysfunction will resolve with reduction of the prolapse, and she may develop stress incontinence symptoms. In up to 68% of women, occult stress incontinence will be revealed with reduction of stage 3 or stage 4 prolapse.²¹ If the patient demonstrates stress incontinence, a midurethral sling is likely to treat her incontinence effectively, with little added risk from the procedure.²² Even among women who have an elevated postvoid residual urine volume, the incidence of sling revision is low.¹⁵

CASE 2 Procedure recommendation for this patient

For this case, we would perform a LeFort colpocleisis and discuss whether or not the patient would prefer a midurethral sling if stress incontinence was demonstrated on examination. We would not perform endometrial evaluation in this patient, as she has not been bleeding and her risk for endometrial cancer is low.

Weighing the benefits of native tissue repair

Native tissue repair when performed transvaginally is a minimally invasive approach to prolapse repair. In a multicenter randomized trial, anatomic success was reported to be 64.5% at 2 years.⁶ Long-term follow up of patients undergoing mesh sacrocolpopexy shows a similar anatomic failure rate, with up to one-third of patients meeting the definition of composite failure.³ Unlike mesh-augmented repairs, however, adverse events, including bowel obstruction, mesh exposure, and thromboembolism, are more likely to occur in the mesh sacrocolpopexy group.²³

Obliterative procedures have the highest success rates of all prolapse repairs and carry with them low morbidity. However, women must forego the ability for coitus in the future. For all native tissue vaginal repairs, the surgeon and patient must weigh the risks and benefits of concomitant anti-incontinence procedures.

CONTINUED ON PAGE S58

Abdominal sacrocolpopexy: A tried-and-true approach for apical prolapse repair

Sarah Huber, MD, and Patrick Culligan, MD

CASE Woman with advanced prolapse desires surgical repair

A 55-year-old woman (G2P2) presents to her gynecologist's office reporting a vaginal bulge and pressure that has been worsening for the past year. She describes a nontender ball of tissue the size of an orange protruding past the introitus that worsens with ambulating and lifting heavy objects. She reports some urinary urgency and increased frequency and at times feels as though her bladder does not empty completely with voiding. She denies any urinary incontinence. The patient has regular bowel movements but does report some difficulty with stool evacuation. She has a history of 2 vaginal deliveries and is sexually active. She is postmenopausal, with the last menses about 4 years ago. She is active and exercises regularly.

The patient's Pap smears, mammograms, and colonoscopy are up to date and test results have been normal. She has no significant medical or surgical history and no significant family history of cancer. On examination, her body mass index is normal, as is the cardiopulmonary exam. Her pelvic organ prolapse quantification system (POP-Q) score is Aa +3, Ba +3, C +4, GH 3, PB 3, TVL 10, Ap +2, Bp +2, and D +2. The patient is interested in surgical management.

What urodynamic tests would be appropriate for this patient, and what treatment options would you recommend?

Additional tests needed

Patients with advanced-stage pelvic organ prolapse are at an increased risk for stress urinary incontinence that may be masked by urethral "kinking" due to anatomic distortion of the periurethral support mechanism. Based on recommendations from the American Urological Association (AUA) and Society of Urodynamics, Female Pelvic Medicine and Urogenital Reconstruction (SUFU), we routinely perform a postvoid residual urine volume measurement, urinalysis,

Dr. Culligan reports that he is a shareholder in Oragami Surgical LLC and a consultant and speaker for Coloplast and Intuitive Surgical Inc. Dr. Huber reports no financial relationships relevant to this article.

Take-home points

- Robot-assisted laparoscopic sacrocolpopexy is a safe, effective, and durable treatment for advanced-stage pelvic organ prolapse.
- This procedure can completely correct stage 3 or 4 prolapse when the dissection of the anterior vaginal wall extends to the bladder neck and the dissection of the posterior vaginal wall extends to the perineal body.
- One can avoid the need for concomitant vaginal prolapse repair by gathering up stretched out vaginal epithelium while suturing to the mesh arms.
- Sacral attachment sutures should be placed in the anterior longitudinal ligament distal to the sacral promontory to avoid the L5-S1 disc.
- Unless contraindicated, lightweight macroporous polypropylene mesh is the current implant of choice.

urine culture, and a prolapse reduction stress test.²⁴ If the urinalysis is positive for blood, then a preoperative cystoscopy would be indicated.

If stress incontinence is confirmed by reduction stress testing, the patient should be offered an anti-incontinence procedure, such as a mesh midurethral sling.

This patient's overactive bladder symptoms warrant investigation via complex urodynamic testing to allow for comprehensive counseling about her postoperative expectations.

Counseling the patient on the sacrocolpopexy option

Abdominal sacrocolpopexy initially was described in 1962 by Lane as a technique to affix the vaginal apex to the sacral promontory using a graft. Although the procedure has been modified over the years, the principles of using an implanted strengthening material to permanently attach the apex to the anterior longitudinal ligament at the sacrum has proven to be a highly effective and safe treatment, establishing it as the gold standard for apical prolapse repair.^{25,26}

Compared with other methods of apical prolapse repair, sacrocolpopexy via any approach is superior to vaginal surgery in terms of subjective and objective outcomes. In a recent systematic review comparing apical prolapse repairs, patients who underwent a vaginal approach were more likely to report awareness of their prolapse after surgery, undergo repeat surgery, have objective recurrent prolapse, and were at increased risk for postoperative stress urinary incontinence and dyspareunia.²⁶ Prospective studies within our practice have shown 1-year composite subjective and objective cure rates of 94% to 95%.^{27,28}

Selecting a route for sacrocolpopexy

Although sacrocolpopexy can be approached via laparotomy or conventional laparoscopy, we routinely use a robot-assisted approach, as it has been shown to be especially beneficial for complex situations, such as in patients with prior pelvic surgery, a foreshortened vagina, or obesity.^{29,30}

Potential complications

Sacrocolpopexy complications are rare, especially when a minimally invasive approach is used.³¹ Reported complications of minimally invasive sacrocolpopexy include gastrointestinal or genitourinary injury, bowel obstruction or ileus, incisional hernia, vascular injury, discitis or osteomyelitis, conversion to open procedure, and mesh exposure.

Vaginal mesh exposure is rare following sacrocolpopexy, but it can occur at any time following surgery.³¹ Some risk factors include mesh material selection (specifically polytetrafluoroethylene [PTFE] mesh), concurrent total hysterectomy, vaginal atrophy, and smoking.^{32,33} As a result, recent recommendations have advised the use of polypropylene mesh with uterine preservation or supracervical hysterectomy at the time of sacrocolpopexy.³⁴ In fact, supracervical hysterectomy alone appears to cut down or eliminate the risk of mesh exposure in laparoscopic sacrocolpopexy.³⁵

In our practice, avoiding split-thickness vaginal dissection, employing supracervical hysterectomy techniques, and using ultralightweight mesh has resulted in mesh exposure rates approaching zero.²⁸

For atrophic vaginal tissue, one can consider

prescribing preoperative vaginal estrogen for 4 to 6 weeks, but this is not essential and should not routinely delay pelvic reconstructive surgery.

What type of implant material is best?

While various materials have been used as the fixation media in sacrocolpopexy, loosely knitted synthetic type I macroporous polypropylene mesh is the best choice due to its efficacy, availability, and low adverse effect profile. We recommend a lightweight mesh with a maximum weight of 25 g/m². Two such products currently available are the UPsylon Y-Mesh (Boston Scientific, Marlborough, Massachusetts) and Restorelle Y mesh (Coloplast, Minneapolis, Minnesota). Lightweight mesh has been proven to maintain integrity, guaranteeing a successful outcome, while reducing the “mesh load” on the attached tissue.^{27,28}

Comparative studies with fascia lata or cross-linked porcine dermal grafts demonstrated inferior outcomes versus synthetic mesh, and currently the only biologic material on the market indicated for prolapse repair augmentation, ACell Pelvic Floor Matrix (ACell, Columbia, Maryland), has not been extensively tested in sacrocolpopexy.³⁶⁻³⁸

Vaginal anatomy restored by sacrocolpopexy

Abdominal sacrocolpopexy, specifically via a minimally invasive approach, is an effective and long-lasting treatment that should be offered to women with advanced-stage prolapse.

Using the surgical techniques described below, including attachment of the mesh along the lengths of the anterior and posterior vaginal walls and gathering up excess tissue with mesh attachment, can provide women with adequate support for the entire vagina with restoration of normal vaginal anatomy and caliber.

ON THE WEB: Ten surgical videos from Drs. Huber and Culligan at mdedge.com/obgmanagement

Step-by-step tips for surgical efficiency

Robotic port placement

- Place the trocars in a “W” layout for the da Vinci Si Surgical System (**FIGURE 4**, page SS10; **VIDEO 1**)

FIGURE 4 Standard trocar placement for urogynecologic procedures using the da Vinci Si Surgical System

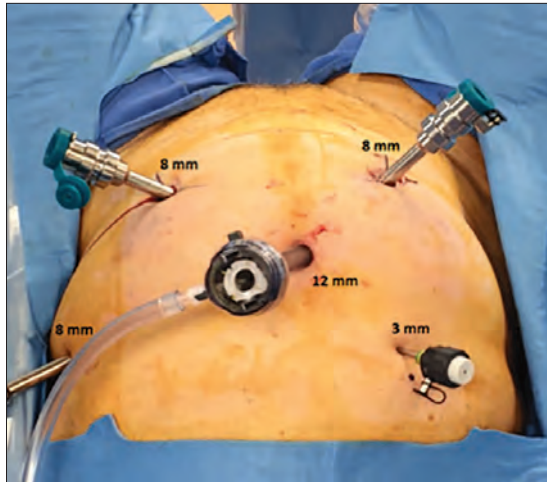
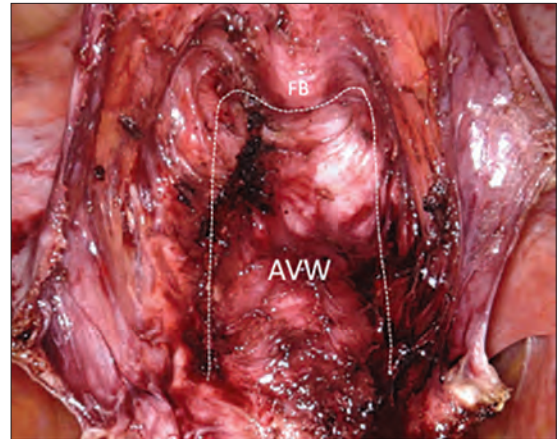


FIGURE 5 Completion of anterior vaginal wall dissection in robot-assisted laparoscopic sacrocolpopexy



Abbreviations: FB, outline of Foley bulb; AVW, anterior vaginal wall.

or in a linear layout for the da Vinci Xi Surgical System (Intuitive Surgical, Sunnyvale, California). Both Si and Xi port placement includes a 3- to 5-mm assistant port in the right upper quadrant of the abdomen.

Supracervical hysterectomy, if indicated

- Maneuver the uterus with the robotic tenaculum, which obviates the need for a uterine manipulator during the hysterectomy (VIDEO 2).
- Create the bladder flap just above the upper edge of the bladder to facilitate the upcoming anterior wall dissection. This helps to prevent the development of a split-thickness dissection plane.
- 1.5 to 2 cm of cervix should be left in place, and conization should be avoided.

Anterior vaginal wall dissection

- The key to a good full-thickness dissection is sustained tissue traction and countertraction. The bedside assistant pulls the anterior peritoneal cut edge anteriorly for “gross” traction, and further “fine” traction can be created by pulling the areolar tissue with robotic forceps. The cervix is grasped with the tenaculum, which applies a constant midline cephalad countertraction (VIDEO 3).
- Sharp dissection with cold scissors allows for

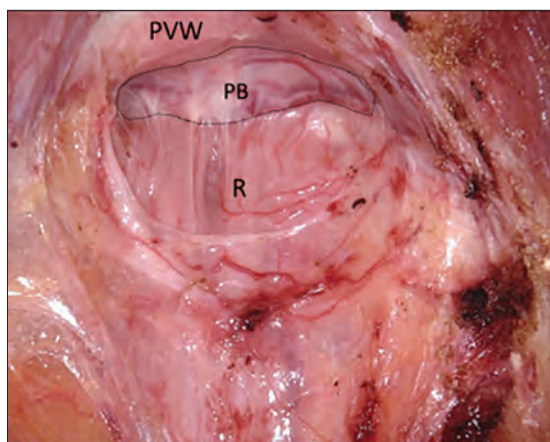
creation of the dissection plane, while cautery is judiciously applied only for hemostasis. If bleeding is encountered, this usually indicates that a split thickness of the vaginal wall has been created, and the surgeon should correct to the proper dissection plane.

- Dissection is made easier by taking down the bladder pillars before advancing down toward the bladder neck.
- The anterior dissection is always carried down to level of the trigone, confirmed by visualization of the Foley bulb (FIGURE 5).

Posterior vaginal wall dissection

- Begin dissection just above the rectal reflection, leaving peritoneum on the posterior cervix (VIDEO 4).
- Extend the incision bilaterally to the uterosacral ligaments only after the correct dissection plane is confirmed by visualization of the areolar tissue.
- Apply cervical traction using the tenaculum in a cephalad midline direction, and place traction on the cut edge of the posterior peritoneum using the bipolar forceps. The tenaculum wrist must be turned away from the working instruments to avoid internal clashing.
- Completely transect the right uterosacral ligament to better facilitate the creation of a

FIGURE 6 Completion of posterior vaginal wall dissection in robot-assisted laparoscopic sacrocolpopexy



Abbreviations: PB, perineal body; PVW, posterior vaginal wall; R, rectum.

contiguous peritoneal opening for burying the mesh. The remainder of the opening will be created later.

- While it is important to avoid split-thickness dissection, the vaginal plane must be “clean” (that is, without fat or adventitia) to allow for robust suturing.
- Dissection at least halfway down the posterior vaginal wall is recommended but proceeding down to the perineal body provides the most optimal support (FIGURE 6).

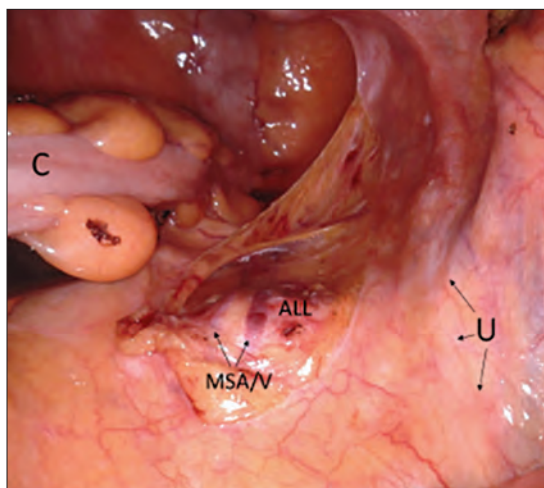
Sacral dissection

- Use a noncrushing instrument to laterally sweep the bowel to the left side, effectively “plastering” the peritoneum over the sacral promontory (FIGURE 7; VIDEO 5).
- Extend the superficial peritoneal incision down the right paracolic gutter halfway between the ureter and colon until it communicates with the incised posterior peritoneal edge created during the posterior dissection.
- Identify the middle sacral artery to avoid vascular injury, but there is no need to prophylactically coagulate it.

Vaginal mesh attachment

- Cut a lightweight Y-mesh to a length of 6 to 8 cm anteriorly and 8 to 11 cm posteriorly and place

FIGURE 7 Dissection of the anterior longitudinal ligament

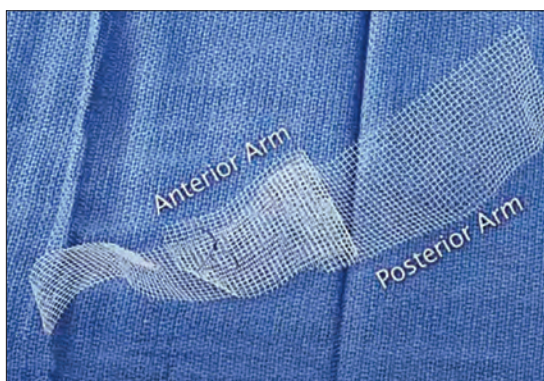

Abbreviations: ALL, anterior longitudinal ligament; C, colon swept medially; MSA/V, middle sacral artery and vein; U, right ureter.

it into the surgical field (FIGURE 8; VIDEO 6). The length is determined based on the preoperative office examination and examination under anesthesia prior to starting the procedure.

- Attach the mesh securely and evenly to the anterior and posterior vaginal walls using multiple interrupted monofilament sutures. We aim to place sutures that provide mesh stability without excess vaginal wall incorporation to avoid “through-and-through” suturing.

FIGURE 8 Ultralightweight Y-mesh with the anterior arm cut to 6 cm and the posterior arm cut to 10 cm. A loose knot is placed through the anterior arm and sacral arm



CONTINUED ON PAGE SS12

- The posterior wall suturing is performed first, starting at the perineal body and continuing cephalad (VIDEO 7). We find it easiest to tie the knots between the mesh and the vagina in this space.
- Suture the crotch of the Y-mesh to the cervix so that no gap exists between tissue and mesh.
- For advanced-stage prolapse with significant anterior prolapse, the stretched out vaginal epithelium can be systematically gathered up to reconfigure the tissue to conform to the desired mesh dimensions (VIDEO 8). This tissue remodeling is evident even at the 2- to 4-week postoperative visit.

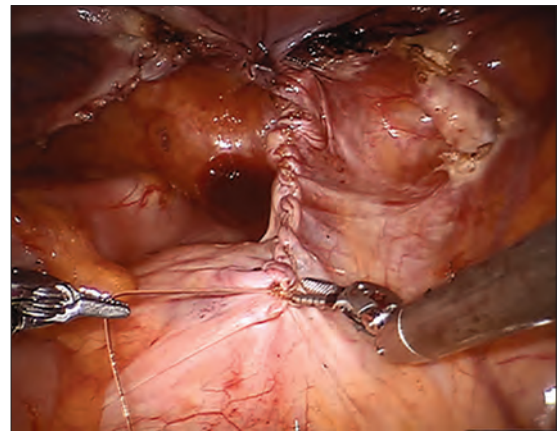
Peritoneal closure: Step 1

- Reapproximate the cut edges of peritoneum surrounding the vagina and cervix using a continuous purse-string suture of 0 Monocryl (poliglecaprone 25) on an SH needle (Ethicon, Somerville, New Jersey) with a fisherman's knot tied at the end (VIDEO 9). The needle passes are placed close together and close to the incised edge of the cut peritoneum.
- We typically start our peritoneal suture at the 5 o'clock position of the posterior peritoneum, extending in a clockwise direction and ultimately jumping anteriorly around the sacral arm of the mesh.
- Place the mesh within the paracolic peritoneal canal, and secure the needle for later use.

Sacral mesh attachment

- The mesh is tensioned so that a vaginal examination confirms adequate support of all the walls without excess tension or tissue banding. Some laxity of the anterior vaginal wall consistent with a mild cystocele is appropriate.
- Place 2 permanent PTFE sutures along the slope of the sacral promontory into the anterior longitudinal ligament (VIDEO 10). This avoids injury to the disc space that sits at the edge of the promontory. We do not advise the use of bone

FIGURE 9 Completed robot-assisted laparoscopic sacrocolpopexy with peritoneal closure



anchors as they increase the risk for discitis and osteomyelitis.

- Secure the mesh to the anterior longitudinal ligament without any tension. This is facilitated by creating mesh slack via cephalad pressure from a vaginal probe.

Peritoneal closure: Step 2

- Close the remaining paracolic peritoneal incision, completely burying the mesh within the created canal (FIGURE 9).
- At the end of the procedure, perform a repeat vaginal exam, rectal exam, and cystoscopy.

Technique with prior total hysterectomy

- In patients with a prior total hysterectomy, place a 13 x 3.5 cm Breisky vaginal retractor and/or coated nonconductive stent (Marina Medical, Sunrise, Florida) into the vagina to delineate the anterior and posterior walls at the vaginal apex during dissection.
- Some surgeons may opt to retrograde fill the bladder to better identify its location.
- We routinely leave a segment of peritoneum attached to the dome of the vaginal apex for added tissue integrity to prevent erosion.

Transvaginal mesh: An effective, durable option for POP repair

Vincent R. Lucente, MD, MBA, and Jessica B. Ton, MD

As baseline health in the elderly population continues to improve, the number of women in the United States with symptomatic POP will increase by approximately 50% by 2050.³⁹ Unfortunately, after native tissue repair (NTR) the rate of prolapse recurrence is extremely high: approximately 40% regardless of approach, as demonstrated in the OPTIMAL (Operations and Pelvic Muscle Training in the Management of Apical Support Loss) trial by Barber and colleagues.⁶ The authors of that clinical trial recently revealed that at the 5-year follow-up, these failure rates progressed to 70% for sacrospinous ligament fixation and 61% for uterosacral ligament suspension (data presented at the Society of Gynecologic Surgeons Annual Scientific Meeting 2018, Orlando, Florida). This establishes that NTR is not durable enough to meet the increasing physical demands of this age group and that mesh augmentation must be considered.

For patients at increased risk of prolapse recurrence, using transvaginal mesh (TVM) is the most minimally invasive approach and is an excellent option for mesh augmentation. Avoiding adverse events during placement of TVM depends largely on optimal surgical technique.⁴⁰

The evidence on TVM versus NTR

Several studies have examined whether TVM has a measurable benefit over NTR.

A 2016 Cochrane review by Maher and colleagues included 37 randomized trials (4,023 women) that compared TVM and biologic grafts with NTR.⁴¹ Three primary outcomes were defined: awareness of prolapse, recurrence, and repeat surgery. Compared with women treated with NTR, those treated with synthetic nonabsorbable TVM exhibited a greater reduction in

ON THE WEB: Surgical video from Drs. Lucente and Ton at mdedge.com/obgmanagement

awareness of prolapse (risk ratio [RR], 0.66; 95% confidence interval [CI], 0.54–0.81), decreased recurrence in the anterior compartment (RR, 0.33; 95% CI, 0.26–0.40), and decreased reoperation for prolapse (RR, 0.53; 95% CI, 0.31–0.88). The overall calculated exposure rate was 12%, with a range of 3.2% to 20.8%.⁴¹ As we will discuss, this wide range most likely is attributed to a sub-optimal, split-thickness dissection. There were no differences in other key secondary outcomes, including dyspareunia, operating time, and estimated blood loss.⁴¹

Longitudinal studies are emerging as almost 2 decades have passed since TVM was introduced. In a study of 5-year follow-up after TVM placement, Meyer and colleagues reported that patients had continued significant improvements in both subjective and objective outcomes.⁴² The mesh exposure rate was 6%, attributed to severe vaginal atrophy.⁴² A 10-year observational study by Weintraub and colleagues demonstrated a recurrence rate of only 2.6% in the anterior compartment, 7.6% in the posterior (nonaugmented) compartment, and no exposures or extrusions after anterior TVM placement.⁴³

Take-home points

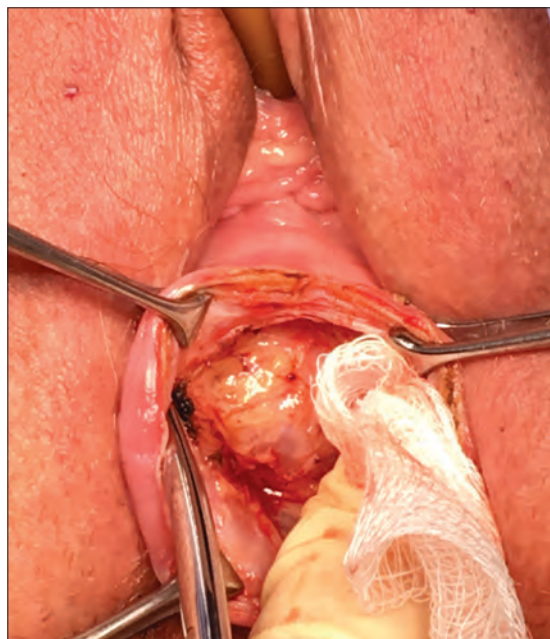
- Active advanced age requires a durable reconstructive pelvic surgery for pelvic organ prolapse, and native tissue repair does not meet that demand.
- Mesh augmentation reduces the risk of prolapse recurrence, and vaginal placement of mesh is the most minimally invasive approach.
- Rates of exposure with transvaginal mesh would be minimized with use of a full-thickness vaginal wall dissection.
- Optimal surgical technique could be highly reproducible with better surgical training.

Dr. Lucente reports that he has received grant or research support from Advanced Tactile Imaging, Boston Scientific, Coloplast, and Valencia; is a consultant to Coloplast; is a speaker for Allergan, Boston Scientific, Coloplast, and Shionogi; and serves as an expert witness for American Medical Systems and C.R. Bard.

Dr. Ton reports no financial relationships relevant to this article.

CONTINUED ON PAGE SS14

FIGURE 10 Demonstration of a full-thickness anterior vaginal wall dissection. The presence of fat denotes the true vesicovaginal space



In contrast to the Cochrane review, in the 2017 multicenter PROSPECT (Prolapse surgery: Pragmatic evaluation and randomized controlled trials) trial, Glazener and colleagues found no difference in desired outcomes with TVM compared with NTR.⁴⁴ There was an overall 6% to 7% exposure rate over 2 years.⁴⁴ To reflect “real-world” practice, however, this study was intentionally designed without rigorous standardization of surgical technique. The authors reported that “appropriately experienced surgeons” performed the procedure, but it is unclear how experience was determined given that 20% of the cases were performed by “registrars,” the equivalent of US residents or fellows.⁴⁵

The PROSPECT study protocol described the TVM procedure as “a standard repair with a non-absorbable mesh inlay to support the stitches,” implying that there was no apical attachment of the mesh to the sacrospinous ligament.⁴⁵ This is a suboptimal use of TVM because it does not address a detachment-type defect common in advanced prolapse. The PROSPECT study reinforces the need for better surgical training and standardization of the TVM procedure.⁴⁴

How TVM compares with sacrocolpopexy

When comparing the use of TVM with sacrocolpopexy, our experience has been that TVM yields similar outcomes to sacrocolpopexy with additional benefits. We completed a 1-year retrospective cohort study comparing robot-assisted laparoscopic sacrocolpopexy (RALS) with TVM in a total of 86 patients, with both approaches performed by the same surgeon. Both treatment groups showed statistically significant improvements in nearly all functional and quality-of-life measures, including urinary symptoms, sexual function, and POP-Q scores.⁴⁰ In particular, points Aa and Ba on the POP-Q score were significantly improved with TVM as compared to RALS. This suggests that TVM can achieve both lateral and apical support, where sacrocolpopexy addresses only the apex.⁴⁰ This has clinical significance when considering DeLancey and colleagues’ dynamic magnetic resonance imaging study, which demonstrated advanced prolapse results from both lateral and apical detachment.⁴⁶ In addition, TVM placement also was considerably faster than RALS by approximately 96 minutes and could be performed using regional anesthesia. Only 1 mesh exposure in each study arm was reported.⁴⁰

Finally, as with other vaginal procedures, patients who undergo TVM placement require minimal to no pain medication postoperatively and report faster return to daily activities. Almost none of our patients require narcotics, which is a significant benefit in the face of the ongoing national opioid crisis.

Gutman and colleagues compared laparoscopic mesh hysteropexy with TVM; they demonstrated comparable cure rates and, again, significantly longer operative times for the laparoscopic approach (174 vs 64 minutes; $P < .0001$).⁴⁷ This multicenter study reported mesh exposure rates of 2.7% for laparoscopy and 6.6% for TVM,⁴⁷ again likely due to a split-thickness dissection.

Safety of TVM depends on the surgeon factor

Because of the reported complications associated with TVM, in 2011 the US Food and Drug Administration (FDA) issued an update on the safety and efficacy of TVM augmentation and mandated

postmarket studies.⁴⁸ While we do not dispute that the mesh exposure rates were accurate at the time the FDA document was issued, we recognize that exposure has been erroneously attributed to inherent properties of the mesh.

Mesh exposure rates reported in the literature vary widely, ranging from 0% to 30%, even when surgeons used identical mesh products.⁴⁹ This clearly establishes that the main contributing variable is surgical technique. It is critically important to recognize the “surgeon factor” as a confounder in trials that compare surgical procedures.⁵⁰ Studies on TVM have shown that low-volume surgeons had significantly higher reoperation rates, while high-volume surgeons achieved a 41% reduction in reoperations.^{51,52} When TVM is performed by expert surgeons, the reported mesh exposure rates for TVM are noticeably lower.^{40,42,43,53,54}

Decreasing mesh exposure rates would reduce the most common adverse event associated with TVM, thus improving its safety. The critical step to successful TVM placement is the initial dissection. Gynecologists traditionally have performed a split-thickness, colporrhaphy-style dissection to place the mesh

within the layers of the vaginal wall.⁵⁵ Placement within these planes, however, is too superficial and increases the risk of exposure. By contrast, by consistently performing a full-thickness vaginal wall dissection (**FIGURE 10**) and placing the mesh in the true vesicovaginal space,⁵⁶ we have achieved a TVM exposure rate as low as 0% to 3%.^{40,54} If we can standardize the dissection component across our subspecialty, the rate of mesh exposure undoubtedly will decrease.

The PROSPECT investigators readily admitted what the study was not: a trial conducted “exclusively by the most experienced surgeons in the highest volume centres...with a highly protocolised technique.”⁴⁴ In reality, that is the kind of rigorous study on TVM that our subspecialty demands. We must hold ourselves accountable and ensure that only the most qualified surgeons are placing TVM.

Keep the mesh option available

We support the position of the American Urogynecologic Society in opposing an outright ban of TVM because such a restriction would deny our patients access to an effective, durable, and minimally invasive approach for prolapse repair.⁵⁷ ■

References

1. Wu JM, Matthews CA, Conover MM, Pate V, Jonsson Funk M. Lifetime risk of stress urinary incontinence or pelvic organ prolapse surgery. *Obstet Gynecol.* 2014;123(6):1201–1206.
2. Olsen AL, Smith VJ, Bergstrom JO, Colling JC, Clark AL. Epidemiology of surgically managed pelvic organ prolapse and urinary incontinence. *Obstet Gynecol.* 1997;89(4):501–506.
3. Nygaard I, Brubaker L, Zyczynski HM, et al. Long-term outcomes following abdominal sacrocolpopexy for pelvic organ prolapse. *JAMA.* 2013;309(19):2016–2024.
4. American College of Obstetricians and Gynecologists, American Urogynecologic Society. Practice Bulletin No. 185 Summary: Pelvic organ prolapse. *Obstet Gynecol.* 2017;130(5):1170–1172.
5. American Urogynecologic Society Best Practice Statement: Evaluation and counseling of patients with pelvic organ prolapse. *Female Pelvic Med Reconstr Surg.* 2017;23(5):281–287.
6. Barber MD, Brubaker L, Burgio KL, et al; Eunice Kennedy Shriver National Institute of Child Health and Human Development Pelvic Floor Disorders Network. Comparison of 2 transvaginal surgical approaches and perioperative behavioral therapy for apical vaginal prolapse: the OPTIMAL randomized trial. *JAMA.* 2014;311(10):1023–1034.
7. Chung CP, Miskimins R, Kuehl TJ, Yandell PM, Shull BL. Permanent suture used in uterosacral ligament suspension offers better anatomical support than delayed absorbable suture. *Int Urogynecol J.* 2012;23(2):223–227.
8. Yazdany T, Yip S, Bhatia NN, Nguyen JN. Suture complications in a teaching institution among patients undergoing uterosacral ligament suspension with permanent braided suture. *Int Urogynecol J.* 2010;21(7):813–818.
9. Togliola MR, Fagan MJ. Suture erosion rates and long-term surgical outcomes in patients undergoing sacrospinous ligament suspension with braided polyester suture. *Am J Obstet Gynecol.* 2008;198(5):600.e1–e4.
10. Wong MJ, Rezvan A, Bhatia NN, Yazdany T. Uterosacral ligament vaginal vault suspension using delayed absorbable monofilament suture. *Int Urogynecol J.* 2011;22(11):1389–1394.
11. Detollenaere RJ, den Boon J, Stekelenburg J, Int’Hout J, et al. Sacrospinous hysteropexy versus vaginal hysterectomy with suspension of the uterosacral ligaments in women with uterine prolapse stage 2 or higher: multicentre randomised non-inferiority trial. *BMJ.* 2015;351:h3717.
12. Kapoor S, Sivanesan K, Robertson JA, Veerasingham M, Kapoor V. Sacrospinous hysteropexy: review and meta-analysis of outcomes. *Int Urogynecol J.* 2017;28(9):1285–1294.
13. Madsen AM, Raker C, Sung VW. Trends in hysteropexy and apical support for uterovaginal prolapse in the United States from 2002 to 2012. *Female Pelvic Med Reconstr Surg.* 2017;23(6):365–371.
14. Wei JT, Nygaard I, Richter HE, et al; Pelvic Floor Disorders Network. A midurethral sling to reduce incontinence after vaginal prolapse repair. *N Engl J Med.* 2012;366(25):2358–2367.
15. Buchsbaum GM, Lee TG. Vaginal obliterative procedures for pelvic organ prolapse: a systematic review. *Obstet Gynecol Surv.* 2017;72(3):175–183.
16. Zebede S, Smith AL, Plowright LN, Hegde A, Aguilar VC, Davila GW. Obliterative LeFort colpocleisis in a large group of elderly women. *Obstet Gynecol.* 2013;121(2 pt 1):279–284.
17. Bochenska K, Leader-Cramer A, Mueller M, Dave B, Alverdy A, Kenton K. Perioperative complications following colpocleisis with and without concomitant vaginal hysterectomy. *Int Urogynecol J.* 2017;28(11):1671–1675.
18. Jones K, Wang G, Romano R, St Marie P, Harmanli O. Colpocleisis: a survey of current practice patterns. *Female Pelvic Med Reconstr Surg.* 2017;23(4):276–280.
19. Jones KA, Zhuo Y, Solak S, Harmanli O. Hysterectomy at the time of colpocleisis: a decision analysis. *Int Urogynecol J.* 2016;27(5):805–810.

SPECIAL SECTION Optimal surgical management of stage 3 and 4 pelvic organ prolapse

20. Kandadai P, Flynn M, Zweigig S, Patterson D. Cost-utility of routine endometrial evaluation before le fort colpocleisis. *Female Pelvic Med Reconstr Surg*. 2014;20(3):168-173.
21. Reena C, Kekre AN, Kekre N. Occult stress incontinence in women with pelvic organ prolapse. *Int J Gynaecol Obstet*. 2007;97(1):31-34.
22. Oliphant SS, Shepherd JP, Lowder JL. Midurethral sling for treatment of occult stress urinary incontinence at the time of colpocleisis: a decision analysis. *Female Pelvic Med Reconstr Surg*. 2012;18(4):216-220.
23. Siddiqui NY, Grimes CL, Casiano ER, et al; Society of Gynecologic Surgeons Systematic Review Group. Mesh sacrocolpopexy compared with native tissue vaginal repair: a systematic review and meta-analysis. *Obstet Gynecol*. 2015;125(1):44-55.
24. Winters JC, Dmochowski RR, Goldman HB, et al; American Urological Association; Society of Urodynamics, Female Pelvic Medicine and Urogenital Reconstruction. Urodynamic studies in adults: AUA/SUFU guideline. *J Urol*. 2012;188(6 suppl):2464-2472.
25. Barber MD, Maher C. Apical prolapse. *Int Urogynecol J*. 2013;24(11):1815-1833.
26. Maher C, Feiner B, Baessler K, Christmann-Schmid C, Haya N, Brown J. Surgery for women with apical vaginal prolapse. *Cochrane Database Syst Rev*. 2016;10:CD012376.
27. Salamon CG, Lewis C, Priestley J, Gurshumov E, Culligan PJ. Prospective study of an ultra-lightweight polypropylene Y mesh for robotic sacrocolpopexy. *Int Urogynecol J*. 2013;24(8):1371-1375.
28. Culligan PJ, Gurshumov E, Lewis C, et al. Subjective and objective results 1 year after robotic sacrocolpopexy using a lightweight Y-mesh. *Int Urogynecol J*. 2014;25(6):731-735.
29. Eddib A, Danakas A, Hughes S, et al. Influence of morbid obesity on surgical outcomes in robotic-assisted gynecologic surgery. *J Gynecol Surg*. 2014;30(2):81-86.
30. Gallo T, Kashani S, Patel DA, Elshahi K, Silasi D-A, Azodi M. Robotic-assisted laparoscopic hysterectomy: outcomes in obese and morbidly obese patients. *JSL*. 2012;16(3):421-427.
31. Serati M, Bogani G, Sorice P, et al. Robot-assisted sacrocolpopexy for pelvic organ prolapse: a systematic review and meta-analysis of comparative studies. *Eur Urol*. 2014;66(2):303-318.
32. Cundiff GW, Varner E, Visco AG, et al; Pelvic Floor Disorders Network. Risk factors for mesh/suture erosion following sacral colpopexy. *Am J Obstet Gynecol*. 2008;199(6):688.e1-e5.
33. Wu JM, Wells EC, Hundley AF, Connolly A, Williams KS, Visco AG. Mesh erosion in abdominal sacral colpopexy with and without concomitant hysterectomy. *Am J Obstet Gynecol*. 2006;194(5):1418-1422.
34. Costantini E, Brubaker L, Cervigni M, et al. Sacrocolpopexy for pelvic organ prolapse: evidence-based review and recommendations. *Eur J Obstet Gynecol Reprod Biol*. 2016;205:60-65.
35. Tan-Kim J, Menefee SA, Luber KM, Nager CW, Lukacz ES. Prevalence and risk factors for mesh erosion after laparoscopic-assisted sacrocolpopexy. *Int Urogynecol J*. 2011;22:205-212.
36. Culligan PJ, Salamon C, Priestley JL, Shariati A. Porcine dermis compared with polypropylene mesh for laparoscopic sacrocolpopexy: a randomized controlled trial. *Obstet Gynecol*. 2013;121(1):143-151.
37. Tate SB, Blackwell L, Lorenz DJ, Steptoe MM, Culligan PJ. Randomized trial of fascia lata and polypropylene mesh for abdominal sacrocolpopexy: 5-year follow-up. *Int Urogynecol J*. 2011;22(2):137-143.
38. Culligan PJ, Blackwell L, Goldsmith LJ, Graham CA, Rogers A, Heit MH. A randomized controlled trial comparing fascia lata and synthetic mesh for sacral colpopexy. *Obstet Gynecol*. 2005;106(1):29-37.
39. ACOG Committee on Practice Bulletins-Gynecology, American Urogynecologic Society. ACOG Practice Bulletin No. 185: Pelvic organ prolapse. *Obstet Gynecol*. 2017;130(5):e234-e250.
40. Jambusaria LH, Murphy M, Lucente VR. One-year functional and anatomic outcomes of robotic sacrocolpopexy versus vaginal extraperitoneal colpopexy with mesh. *Female Pelvic Med Reconstr Surg*. 2015;21(2):87-92.
41. Maher C, Feiner B, Baessler K, Christmann-Schmid C, Haya N, Marjoribanks J. Transvaginal mesh or grafts compared with native tissue repair for vaginal prolapse. *Cochrane Database System Rev*. 2016:CD012079.
42. Meyer I, McGwin G, Swain T, Alvarez MD, Ellington DR, Richter HE. Synthetic graft augmentation in vaginal prolapse surgery: long-term objective and subjective outcomes. *J Minim Invasive Gynecol*. 2016;23(4):614-621.
43. Weintraub AY, Friedman T, Baumfeld Y, Neymeyer J, Neuman M, Krissi H. Long-term functional outcomes following mesh-augmented posterior vaginal prolapse repair. *Int J Gynecol Obstet*. 2016;135(1):107-111.
44. Glazener CM, Breeman S, Elders A, et al; PROSPECT Study Group. Mesh, graft, or standard repair for women having primary transvaginal anterior or posterior compartment prolapse surgery: two parallel-group, multicentre, randomised, controlled trials (PROSPECT). *Lancet*. 2017;389(10067):381-392.
45. Clinical and cost-effectiveness of surgical options for the management of anterior and/or posterior vaginal wall prolapse: two randomized controlled trials within Comprehensive Cohort Study. PROSPECT study protocol. The National Institute for Health Research. <https://www.journalslibrary.nihr.ac.uk/programmes/hta/076018>, Accessed January 17, 2018.
46. Chen L, Lisse S, Larson K, Berger MB, Ashton-Miller JA, DeLancey JO. Structural failure sites in anterior vaginal wall prolapse: identification of a collinear triad. *Obstet Gynecol*. 2016;128(4):853-862.
47. Gutman RE, Rardin CR, Sokol ER, et al. Vaginal and laparoscopic mesh hysterectomy for uterovaginal prolapse: a parallel cohort study. *Am J Obstet Gynecol*. 2017;216(1):38.e1-e11.
48. US Food and Drug Administration. Urogynecologic surgical mesh: update on the safety and effectiveness of transvaginal placement for pelvic organ prolapse. <https://www.fda.gov/downloads/medicaldevices/safety/alertsandnotices/ucm262760.pdf>. Published July 2011. Accessed January 9, 2017.
49. Murphy M, Holzberg A, van Raalte H, et al; Pelvic Surgeons Network. Time to rethink: an evidence-based response from pelvic surgeons to the FDA Safety Communication: "Update on serious complications associated with transvaginal placement of surgical mesh for pelvic organ prolapse." *Int Urogynecol J*. 2012;23(1):5-9.
50. Roman H, Marpeau L, Hulsey TC. Surgeons' experience and interaction effect in randomized controlled trials regarding new surgical procedures. *Am J Obstet Gynecol*. 2008;199(2):108.e1-e6.
51. Eilber KS, Alperin M, Khan A, et al. The role of the surgeon on outcomes of vaginal prolapse surgery with mesh. *Female Pelvic Med Reconstr Surg*. 2017;23(5):293-296.
52. Kelly EC, Winick-Ng J, Welk B. Surgeon experience and complications of transvaginal prolapse mesh. *Obstet Gynecol*. 2016;128(1):65-72.
53. Altman D, Vayrynen T, Eng ME, Axelsen S, Falconer C; Nordic Transvaginal Mesh Group. Anterior colporrhaphy versus transvaginal mesh for pelvic-organ prolapse. *N Engl J Med*. 2011;364(19):1826-1836.
54. van Raalte HM, Lucente VR, Molden SM, Haff R, Murphy M. One-year anatomic and quality-of-life outcomes after the Prolift procedure for treatment of posthysterectomy prolapse. *Am J Obstet Gynecol*. 2008;199(6):694.e1-e6.
55. Iyer S, Botros SM. Transvaginal mesh: a historical review and update of the current state of affairs in the United States. *Int Urogynecol J*. 2017;28(4):527-535.
56. Ting M, Gonzalez A, Ephraim S, Murphy M, Lucente V. The importance of a full thickness vaginal wall dissection. Comment on "Transvaginal mesh: a historical review and update of the current state of affairs in the United States." *Int Urogynecol J*. 2017;28(10):1609-1610.
57. American Urogynecologic Society. Position statement on restriction of surgical options for pelvic floor disorders. https://www.augs.org/assets/1/6/Position_Statement_Surgical_Options_for_PFDs.pdf. Published March 26, 2013. Accessed January 9, 2017.

Patient experience: It's not about satisfaction

What happens when an ObGyn is married to the chief experience officer?

James I. Merlino, MD, and Amy A. Merlino, MD

My pager went off 20 minutes into my case. The circulating nurse announced that it was the chief of staff's office, and as I migrated over to the phone, everyone was wondering what I had done to warrant a call from the boss. The nurse held the phone to my ear and Dr. Joe Hahn, a neurosurgeon and second-in-command at Cleveland Clinic, congratulated me: "You're it," he said. I thanked him and went back to work. My scrub tech wanted to know what happened. I told him I was just appointed chief experience officer at Cleveland Clinic. With a befuddled look, he asked what that meant. I said I wasn't sure.

Jim gets a fast lesson on how to lead patient experience

Patient experience was a signature issue for Dr. Toby Cosgrove, our then president and chief executive officer. Although the Clinic was revered for its high-quality care, patients did not always like going there. Dr. Cosgrove passionately believed that providing a high-quality experience was as important as the best medical care, and that the experience at the Clinic needed to be improved. Another physician had held the role of chief experience officer before me, but she came from outside the system and was not practicing, which proved to be a challenge in the Clinic's physician-dominated culture. Dr. Cosgrove wanted a physician who "grew up" in the organization to lead this initiative.

When I left my initial interview with Dr. Cosgrove, I could not define patient experience, did not know what HCAHPS (Hospital Consumer Assessment of Healthcare Providers and Systems) was—at the time were in the 10th percentile—and frankly had no idea how I would move a culture of 45,000 people,

including 3,000 employed physicians, to embrace patient-centricity. By the time I left the Clinic in 2015, however, we had pushed our experience scores to the top quartile, realigned our culture, and had become world renown for patient experience.¹

I knew intuitively that improving the patient experience was the right thing to do. In 2004, my father had died at the Clinic from surgical complications; his experience had been terrible. At that time, we did not use the term *experience*, but based on the items that hospitals are graded on today, my father would have failed us on all of them.

What *is* patient experience?

Patient experience is not about making people happy. Fundamentally, it is about delivering safe, high-quality, patient-centric care. A 2017 Press Ganey analysis of publicly reported data from the Centers for Medicaid and Medicare demonstrated that when performance on experience measures is high, safety and quality also are high.² Similarly, in 2015, *JAMA* published an article using data from the National Surgical Quality Improvement Project demonstrating a significant association between patient experience scores and several objective measures of surgical quality, including mortality and complications.³

In my new role, I mercilessly told my father's story, changed the narrative to include safety and quality, and asked my physician colleagues for their help to improve patient experience. People in health care pay very close attention to what physicians do and say, and I needed the doctors to "own it" if we were going to implement the desired change.

I also had to convince them to see themselves on the "other side." It was not just a matter of "treating patients the way you would want to be treated." It was about putting yourself in your patients' shoes—having empathy for what they are

The authors report no financial relationships relevant to this article.

experiencing and recognizing that you or a family member could be sitting in that bed. Before my father was ill, I had never been on the other side so intimately, and it was an eye-opening experience.

Retooling communication competency

For the physicians, we zeroed in on helping them improve how they communicate with patients. Communication is a high-value target for experience improvement, and it directly influences safety and quality. We produced a physician-centric communication guide that provided useful tips (see “Practical tips to help physicians improve communication with patients”). We made communication scores transparent. In addition, working with the American Academy on Communication in Healthcare (AACH), we developed a program specifically designed to help physicians improve their communication skills and practice management.⁴ The outcome was not only better scores but also higher physician engagement and lower burnout.⁵

Keeping it real

Being married to another member of the medical staff—a strong-willed and opinionated one at that—ensured that my strategic approach to improving patient experience was grounded. It gave me a safe place to test ideas and concepts, which in turn allowed me to keep my instincts framed and relevant to the needs of key stakeholders, particularly the physicians.

The ObGyn wife tells her side

When my husband was appointed chief experience officer, I naturally was happy for his accomplishment but admitted that I was not sure exactly what it meant. What was he going to be doing? Would he give up surgery, which he loved?

The experience “thing” always had been fuzzy to me. I equated experience with satisfaction, and I saw my primary role as taking care of patients, not making them happy. I believed that I had great patient relationships, so what else did I need to know to contribute to this work? The connection to safety and quality did resonate with me, though, and it made talking about patient experience more tangible.

When Jim started teasing apart what steps needed to be taken, improving the culture seemed

Practical tips to help physicians improve communication with patients

- Introduce yourself and your role
 - Address the patient by name and use common courtesy
 - Make nursing your partner
 - Ensure that the patient knows and understands the plan of care
 - Explain what the patient can expect (tests, procedures, consultations)
 - Address questions
 - Understand that house staff, care partners, and consultants impact your communication scores
 - Respect the patient’s privacy
 - Be aware of what you do and say in front of patients
 - Include the patient’s family when appropriate
 - Ask patients and visitors how they are being treated and if they need anything
 - Discuss pain management and set expectations
 - When necessary, apologize—try to right a wrong
 - Role model good behavior and address bad behavior
-

like an obvious focus. One thing was clear: He would need to get the physicians on board by helping them to see the practical importance of this work. It could not be gimmicky or too touchy-feely. The work had to be relevant and tangible to their everyday practice. One thing he said struck a chord: “Everyone comes to health care to help people, and we all believe we are the best we can be, but clearly there are opportunities to improve, and evolve our skills.” I started to consider specific circumstances in which that made sense.

Practice to be a better communicator

Improving physician communication was a top priority. I believed that I was a very good communicator, so I was not sure I would learn much from participating in a required day-long session designed by the AACH.

For this program we convened in small groups of 8 to 10 physicians, and each person paired with a partner. The course provided an important framework that would help us to better organize the patient encounter, an approach that no one had ever taught me. It showed me how to leverage the patient’s chief

complaint to empower her to set the agenda. This would avoid unnecessary and inefficient conversational tangents, such as the doorknob question—when the patient brings up the real reason for the visit as you are leaving the exam room.

The course also taught me that while I was a good communicator, I was not efficient. I learned how to listen more effectively. Notably, how we manage patients and how we communicate are learned skills, just like mastering a new surgical procedure. High performance requires thoughtful review and practice.

Work on relationship skills

I had professional colleagues who were difficult to work with or, as I knew from covering for them, had terrible relationships with patients. These interactions made my job harder and directly influenced patient care. I always found it distasteful to hear, “Dr. X treats people very poorly, but he or she is such a great doctor.” Should not doctors be both excellent at their work and excel at the human relationship side of the business? Maybe we did need to work on certain things.

An early Cleveland Clinic initiative was to immerse every employee, including physicians, in a half-day appreciative-inquiry exercise. This entailed sitting around a table with other randomly selected caregivers—a nurse, valet, environmental service worker, administrator—and discussing various topics, such as our role in the organization, teamwork, and the servant-leader philosophy. Going into this exercise, I was skeptical. But going through it fostered a deeper understanding of how we all need to work better together to drive safe, high-quality patient care. It made me reflect on what patients go through every day and the critical contribution each team member makes. The program made me think about what we do and created greater appreciation and mindfulness of our work.

Think empathy

One of the most impactful efforts was getting people to understand and appreciate being on the other side of health care. The patient experience team crafted an empathy video that showcased people—patients, families, caregivers, physicians—and their thoughts as they experienced the other side of health care. The video frames what they are thinking about in the moment and is a powerful reminder that each person has something happening in their life that affects their daily experiences. The empathy video has been viewed by millions around the world. (See “Empathy: The human connection to patient care,” at https://www.youtube.com/watch?v=cDDWvj_q-o8.)

Together we embraced the work

Amy and I shared a unique perspective on this work as the leader of the experience improvement initiative, married to a person experiencing it. We both came to realize that we did not know all there is to know about how to deliver high-quality patient care. Improving experience is both complex and highly nuanced, and it is a vital component of what we do as physicians. The Clinic’s efforts moved the organization to high performance, and everyone played a role. However, we would not have succeeded without the engagement of physician leaders.

Making patients and families happy was never part of the equation. It is about reducing patient suffering and delivering safe, high-quality care in an environment where people feel cared for. That is what the people we serve desire, and it is what we want for ourselves. Although there will always be doubters, especially among physicians, of the importance of patient experience, we must never lose sight that this is the right thing to do for our patients, our families, and ourselves. ■

References

1. Merlino JI, Raman A. Health care’s service fanatics: How the Cleveland Clinic leaped to the top of patient-satisfaction surveys. *Harvard Business Review*. 2013;91(5):108–116.
2. Press Ganey 2016 Strategic Insights. Performance redefined: As healthcare moves from volume to value, the streams of quality are coming together. <http://www.pressganey.com/resources/whitepapers/2016-strategic-insights-performance-redefined>. Published March 22, 2016. Accessed March 20, 2018.
3. Sacks GD, Lawson EH, Dawes AJ, et al. Relationship between hospital performance on a patient satisfaction survey and surgical quality. *JAMA Surg*. 2015;150(9):858–864.
4. Merlino JI, Coulton RW. Enhancing physician communication with patients at Cleveland Clinic. *Group Practice J*. 2012;61(2):24–32.
5. Boissy A, Windover AK, Bokar D, et al. Communication skills training for physicians improves patient satisfaction. *J Gen Intern Med*. 2016;31(7):755–761.

**HIGHLIGHTS FROM
THE 2018 SOCIETY OF
GYNECOLOGIC SURGEONS
SCIENTIFIC MEETING
PART 2**

Rosanne M. Kho, MD

Head, Section of Benign Gynecology
Women's Health Institute
Department of Obstetrics and Gynecology
Cleveland Clinic
Cleveland, Ohio

Maurício S. Abrão, MD

Associate Professor and
Director, Endometriosis Division
Department of Obstetrics and Gynecology
São Paulo University Medical School
São Paulo, Brazil

Alicia Scribner, MD, MPH

Director, Ob/Gyn Simulation Curriculum
Madigan Army Medical Center
Tacoma, Washington
Clinical Instructor
Department of Obstetrics and Gynecology
University of Washington, Seattle

Christine Vaccaro, DO

Medical Director, Andersen Simulation Center
Madigan Army Medical Center
Tacoma, Washington
Clinical Assistant Professor
Department of Obstetrics and Gynecology
University of Washington, Seattle
Uniformed Services University of Health Sciences
Bethesda, Maryland

Deep infiltrating endometriosis: Evaluation and management

Deep endometriosis is successfully diagnosed with clinical signs and symptoms and specific MRI or TVUS protocols, and treatment options are available to relieve pain and optimize outcomes

Rosanne M. Kho, MD, and Mauricio S. Abrão, MD

Endometriosis affects up to 10% of women of reproductive age or, conservatively, about 6.5 million women in the United States.^{1,2}

There are 3 types of endometriosis—superficial, ovarian, and deep—and in the past each of these was assumed to have a distinct pathogenesis.³ Deep infiltrating endometriosis (DIE) is the presence of one or more endometriotic nodules deeper than 5 mm. In a study at a large tertiary-care center, 40% of patients with endometriosis had deep disease.⁴ DIE is associated with more severe pain and infertility.⁵ In patients with endometriosis, diagnosis is commonly made 7 to 9 years after the initial pelvic pain presentation.⁶ For these reasons, well-directed history taking and proper evaluation and treatment should be pursued to relieve pain and optimize outcomes.

CASE Young woman with intensifying pelvic pain

Mary is a 26-year-old social worker who presents to her ObGyn with symptoms of worsening pain during as well as outside her periods. What additional information would you want to obtain from Mary, given her chief symptom of pain?

Investigate the type of pain

It is important to ask the patient about her menstrual and sexual history, her thoughts regarding near- and long-term fertility, and the type and severity of her pain symptoms. The 5 pain symptoms specific to pelvic pain are dysmenorrhea, dyspareunia, dysuria, dyschezia, and noncyclic pelvic pain. A visual analog scale (VAS) for pain as well as pelvic pain questionnaires can be used to guide evaluation options and monitor treatment outcomes. In

Dr. Kho and Dr. Abrão report that they are consultants to AbbVie.

Take-home points

- Specific MRI or TVUS protocols are highly accurate in making a nonsurgical diagnosis of deep infiltrating endometriosis (DIE).
- The combination of compelling clinical signs and symptoms and absence of imaging findings for DIE can be used to make a presumptive nonsurgical diagnosis of endometriosis.
- Empiric medical therapy may provide pain relief.
- Conservative treatment, including observation alone, may be considered in asymptomatic patients with DIE and in those with minimal pain.
- Before surgery, it is imperative to know lesion size, depth, circumferential bowel involvement, and location (or distance from the anal verge in cases of rectosigmoid lesion) to optimize surgical outcomes.

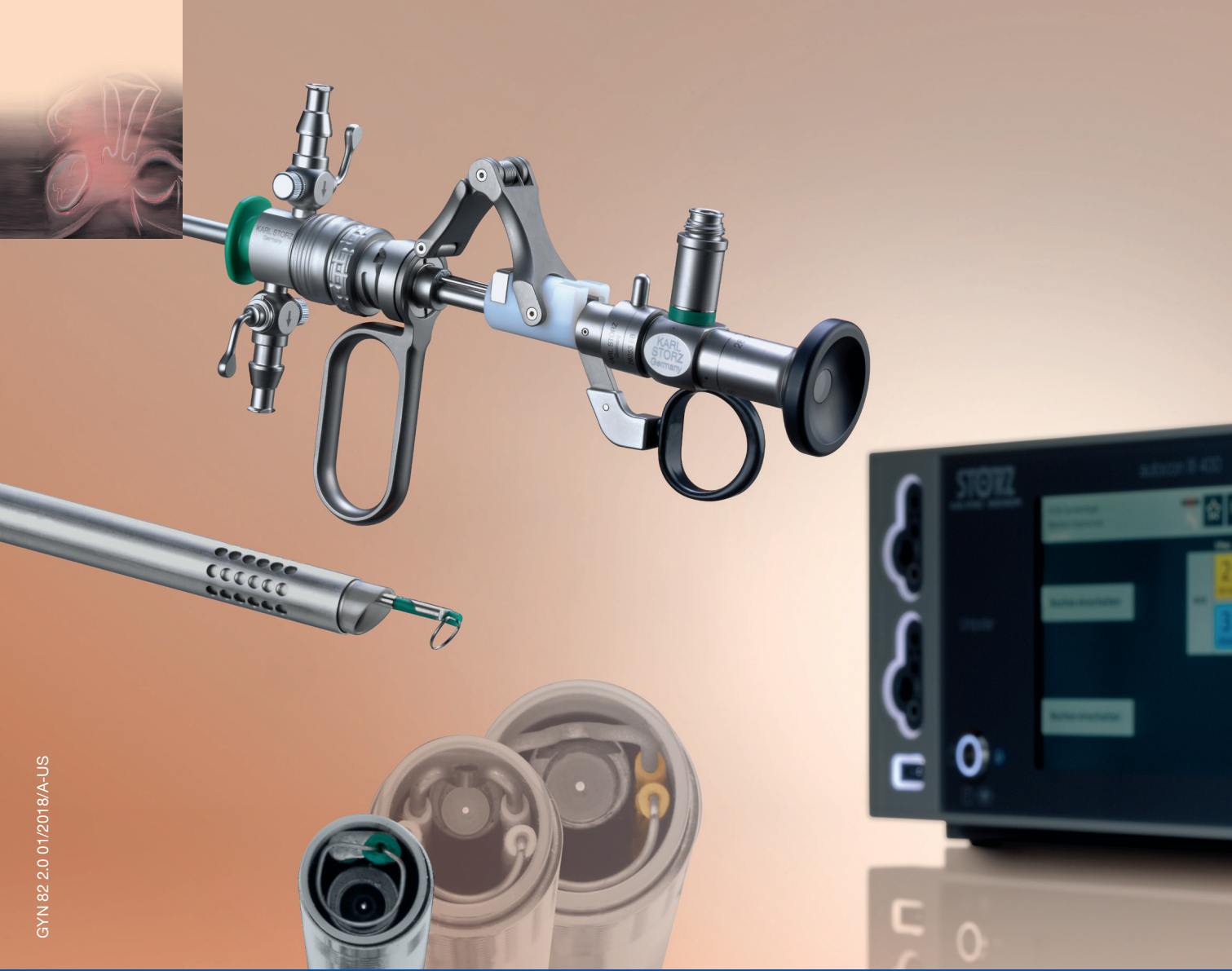addition, it is of paramount importance to understand the differential diagnoses that can present as pelvic pain (TABLE, page SS4).

CASE Continued: Mary's history

Mary reports that she always has had painful periods and that she was started on oral contraceptive pills for pain control and regulation of her periods soon after the onset of menses, when she was 12 years old. In college, she was prescribed oral contraceptive pills for contraception. Recently engaged, she is interested in becoming pregnant in 3 years.

A year ago, Mary discontinued the pills because of their adverse effects. Now she has severe pain during (VAS score, 8/10) and outside (VAS score, 7) her monthly periods. Because of this pain, she has taken time off from work twice within the past 6 months. She has pain during intercourse (VAS score, 7) and some pain with bowel movements during her menses (VAS

CONTINUED ON PAGE SS4



GYN 82 2.0 01/2018/A-US

Perfection in Resection – NEW 15 Fr. – clinical outpatient setting and office resectoscope, extending the set together with 22 Fr., and 26 Fr.

STORZ
KARL STORZ – ENDOSKOPE
THE DIAMOND STANDARD

KARL STORZ SE & Co. KG, Dr.-Karl-Storz-Straße 34, 78532 Tuttlingen/Germany
KARL STORZ Endoscopy-America, Inc. 2151 East Grand Avenue El Segundo, CA 90245-5017/USA
www.karlstorz.com

TABLE Differential diagnosis for pelvic pain

Organ system	Differential diagnosis
Musculoskeletal	<ul style="list-style-type: none"> • Abdominal wall pain • Myofascial pain • Fibromyalgia • Coccydynia • Pelvic floor tension myalgia • Osteitis pubis • Levator ani syndrome • Abdominal wall hernia
Urologic	<ul style="list-style-type: none"> • Interstitial cystitis • Nephrolithiasis
Gastrointestinal	<ul style="list-style-type: none"> • Inflammatory bowel disease • Irritable bowel disease • Chronic constipation • Chronic pseudo-obstruction
Psychologic	<ul style="list-style-type: none"> • Sexual abuse history • Opiate dependency • Depression • Somatization
Gynecologic (excluding endometriosis)	<ul style="list-style-type: none"> • Fibroid uterus • Ovarian remnant syndrome • Pelvic inflammatory disease • Adenomyosis • Pelvic adhesion

score, 4). Pelvic examination reveals a normal-sized uterus and adnexa as well as a tender nodule in the rectovaginal septum.

What diagnostic tests and imaging would you obtain?

Imaging's role in diagnosis

At many advanced centers for endometriosis, DIE is successfully diagnosed with specific magnetic resonance imaging (MRI) or transvaginal ultrasound (TVUS) protocols. In a recent review, MRI's pooled sensitivity and specificity for rectosigmoid endometriosis were 92% and 96%, respectively.⁷ Choice of imaging for DIE depends on the skills and experience of the clinicians at each center. At a large referral center in São Paulo, Brazil, TVUS with bowel preparation had better sensitivity and specificity for deep retrocervical and rectosigmoid disease compared with MRI and digital pelvic examination.⁸ In addition, at a center in the United States, we found that proficiency in performing TVUS for DIE was achieved after 70 to 75 cases, and the exam took an average of only 20 minutes.⁹

Despite recent advances in imaging, most gynecologic societies still hold that endometriosis is to be definitively diagnosed with histologic confirmation from tissue biopsies during surgery. Although surgery remains the diagnostic gold standard, it does not mean that all patients with

pelvic pain should undergo diagnostic laparoscopy with tissue biopsies.

The combination of compelling clinical signs, symptoms, and imaging findings (such as absence of findings for ovarian and deep endometriosis) can be used to make a presumptive nonsurgical (that is, clinical) diagnosis of endometriosis. Major societies recommend empiric medical therapy (for example, combination oral contraceptives) for the pain associated with superficial endometriosis.^{10,11} When there is no response to treatment, or when a patient declines or has contraindications to medical therapy, diagnostic laparoscopy with excision of endometriosis should be considered.

CASE Continued: Diagnosis

Mary undergoes TVUS with bowel preparation, which reveals a normal uterus and adnexa and the presence of 2 lesions, a 2×1.5-cm retrocervical lesion and a 1.8×2-cm rectosigmoid lesion 9 cm above the anal verge. The rectosigmoid lesion involves the external muscularis and compromises 30% of the bowel circumference.

How would you manage the bowel DIE?

Management options: Factor in the variables

DIE can involve the ureters and bladder, the retrocervical and rectovaginal spaces, the appendix, and the bowel. Lesions can be single or multifocal.

Although our institutions' imaging with MRI and TVUS is highly accurate, we additionally recommend the use of colonoscopy (with directed biopsies if appropriate) to evaluate patients who present with rectal bleeding, large endometriotic rectal nodules, or have a family history of bowel cancer.

While many studies have found that surgical resection of DIE improves pain and quality of life, surgery can have significant complications.¹² Observation is adequate for asymptomatic patients with DIE. Medical treatment may be offered to patients with mild pain (there is no evidence of a reduction in lesion size with medical therapy). In cases of surgical treatment, we encourage the involvement of a multidisciplinary surgical team to reduce complications and optimize outcomes.

Patients with DIE, significant pain (VAS score, >7), and multiple failed in vitro fertilization treatments are candidates for surgery. When bowel endometriosis is noted on imaging, factors such as size, depth, number of lesions, circumferential involvement, and distance from the anal verge are all used to determine the surgical approach. Rectosigmoid lesions smaller than 3 cm can be treated more conservatively—for example, with shaving or anterior resection with manual repair using disk staplers. Segmental resection generally is indicated for rectosigmoid lesions larger than 3 cm, involvement deeper than the submucosal layer, multiple lesions, circumferential involvement of more than 40%, and the presence of obstructed bowel symptoms.^{13,14}

In patients with DIE who present with both infertility and pain, antimüllerian hormone level and TVUS follicular count are used to evaluate ovarian reserve. As surgical treatment may further reduce

ovarian reserve in patients with DIE and infertility, we counsel them regarding assisted reproductive technology options before surgery.

CASE Resolved

After thorough discussion, Mary opts to try a different combination oral contraceptive pill formulation. The pills improve her pain symptoms significantly (VAS score, 4), and she decides to forgo surgery. She will be followed up closely on an outpatient basis with serial TVUS imaging.

Individualize management based on patient parameters

Imaging has been used for the nonsurgical diagnosis of DIE for many years, and this practice increasingly is being accepted and adopted. A presumptive nonsurgical diagnosis of endometriosis can be made based on the clinical signs and symptoms obtained from a thorough history and physical examination, in addition to the absence of imaging findings for ovarian and deep endometriosis.

According to guidelines from major ObGyn societies, such as the American College of Obstetricians and Gynecologists and the European Society of Human Reproduction and Embryology, empiric medical therapy (including combination oral contraceptives, progesterone-containing formulations, and gonadotropin-releasing hormone agonists) can be considered for patients with presumed endometriosis presenting with pain.¹⁵

When surgery is chosen, the surgeon must obtain crucial information on the characteristics of the lesion(s) and involve a multidisciplinary team to achieve the best outcomes for the patient. ■

References

1. Giudice LC, Kao LC. Endometriosis. *Lancet*. 2004;364(9447):1789–1799.
2. Buck Louis GM, Hediger ML, Peterson CM, et al; ENDO Study Working Group. Incidence of endometriosis by study population and diagnostic method: the ENDO study. *Fertil Steril*. 2011;96(2):360–365.
3. Nisolle M, Donnez J. Peritoneal endometriosis, ovarian endometriosis, and adenomyotic nodules of the rectovaginal septum are three different entities. *Fertil Steril*. 1997;68(4):585–596.
4. Bellelis P, Dias JA Jr, Podgaec S, Gonzales M, Baracat EC, Abrao MS. Epidemiological and clinical aspects of pelvic endometriosis—a case series. *Rev Assoc Med Bras* (1992). 2010;56(4):467–471.
5. Fauconnier A, Chapron C. Endometriosis and pelvic pain: epidemiological evidence of the relationship and implications. *Hum Reprod Update*. 2005;11(6):595–606.
6. Greene R, Stratton P, Cleary SD, Ballweg ML, Sinai N. Diagnostic experience among 4,334 women reporting surgically diagnosed endometriosis. *Fertil Steril*. 2009;91(1):32–39.
7. Bazot M, Darai E. Diagnosis of deep endometriosis: clinical examination, ultrasonography, magnetic resonance imaging, and other techniques. *Fertil Steril*. 2017;108(6):886–894.
8. Abrão MS, Gonçalves MO, Dias JA Jr, Podgaec S, Chamie LP, Blasbalg R. Comparison between clinical examination, transvaginal sonography and magnetic resonance imaging for the diagnosis of deep endometriosis. *Hum Reprod*. 2007;22(12):3092–3097.
9. Young SW, Dahiya N, Patel MD, et al. Initial accuracy of and learning curve for transvaginal ultrasound with bowel preparation for deep endometriosis in a US tertiary care center. *J Minim Invasive Gynecol*. 2017;24(7):1170–1176.
10. Dunselman GA, Vermeulen N, Becker C, et al; European Society of Human Reproduction and Embryology. ESHRE guideline: management of women with endometriosis. *Hum Reprod*. 2014;29(3):400–412.
11. American College of Obstetricians and Gynecologists Committee on Practice Bulletins–Gynecology. ACOG Practice Bulletin No. 114:

CONTINUED ON PAGE S55.e1

SPECIAL SECTION **Deep infiltrating endometriosis: Evaluation and management**

CONTINUED FROM PAGE SS5

- Management of endometriosis. *Obstet Gynecol.* 2010;116(1):223–236.
12. de Paula Andres M, Borrelli GM, Kho RM, Abrão MS. The current management of deep endometriosis: a systematic review. *Minerva Ginecol.* 2017;69(6):587–596.
 13. Abrão MS, Podgaec S, Dias JA Jr, Averbach M, Silva LF, Marino de Carvalho F. Endometriosis lesions that compromise the rectum deeper than the inner muscularis layer have more than 40% of the circumference of the rectum affected by the disease. *J Minim Invasive Gynecol.* 2008;15(3):280–285.
 14. Abrão MS, Petraglia F, Falcone T, Keckstein J, Osuga Y, Chapron C. Deep endometriosis infiltrating the recto-sigmoid: critical factors to consider before management. *Hum Reprod Update.* 2015;21(3):329–339.
 15. Kho RM, Andres MP, Borrelli GM, Neto JS, Zanluchi A, Abrao MS. Surgical treatment of different types of endometriosis: comparison of major society guidelines and preferred clinical algorithms [published online ahead of print]. *Best Pract Res Clin Obstet Gynaecol.* 2018. doi:10.1016/j.bpobgyn.2018.01.020.

What's new in simulation training for hysterectomy

Here's a rundown on hysterectomy simulation trainers that can be helpful for polishing skills and teaching (and evaluating) residents

Alicia Scribner, MD, MPH, and Christine Vaccaro, DO

Due to an increase in minimally invasive approaches to hysterectomy, including vaginal and laparoscopic approaches, gynecologic surgeons may need to turn to simulation training to augment practice and hone skills. Simulation is useful for all surgeons, especially for low-volume surgeons, as a warm-up to sharpen technical skills prior to starting the day's cases. Additionally, educators are uniquely poised to use simulation to teach residents and to evaluate their procedural competency.

In this article, we provide an overview of the 3 approaches to hysterectomy—vaginal, laparoscopic, abdominal—through medical modeling and simulation techniques. We focus on practical issues, including current resources available online, cost, setup time, fidelity, and limitations of some commonly available vaginal, laparoscopic, and open hysterectomy models.

Simulation directly influences patient safety. Thus, the value of simulation cannot be overstated, as it can increase the quality of health care by improving patient outcomes and lowering overall costs. In 2008, the American College of Obstetricians and Gynecologists (ACOG) founded the Simulations Working Group to establish simulation as a pillar in education for women's health through collaboration, advocacy, research, and the development and implementation of multidisciplinary simulations-based educational resources and opportunities.

Refer to the ACOG Simulations Working Group Toolkit online to see the objectives, simulation, and videos related to each module. Under the "Hysterectomy" section, you will find how to construct the "flower pot" model for abdominal and

vaginal hysterectomy, as well as the AAGL vaginal and laparoscopic hysterectomy webinars. All content is reaffirmed frequently to keep it up to date. You can access the toolkit, with your ACOG login and passcode, at <https://www.acog.org/About-ACOG/ACOG-Departments/Simulations-Consortium/Simulations-Consortium-Tool-Kit>.

For a comprehensive gynecology curriculum to include vaginal, laparoscopic, and abdominal approaches to hysterectomy, refer to ACOG's Surgical Curriculum in Obstetrics and Gynecology page at <https://cfweb.acog.org/scog/>. This page lists the standardized surgical skills curriculum for use in training residents in obstetrics and gynecology by procedure. It includes:

- the objective, description, and assessment of the module
- a description of the simulation
- a description of the surgical procedure
- a quiz that must be passed to proceed to evaluation by a faculty member
- an evaluation form to be downloaded and printed by the learner.

Takeaway. Value of Simulation = Quality (Improved Patient Outcomes) ÷ Direct and Indirect Costs.

Simulation models for training in vaginal hysterectomy

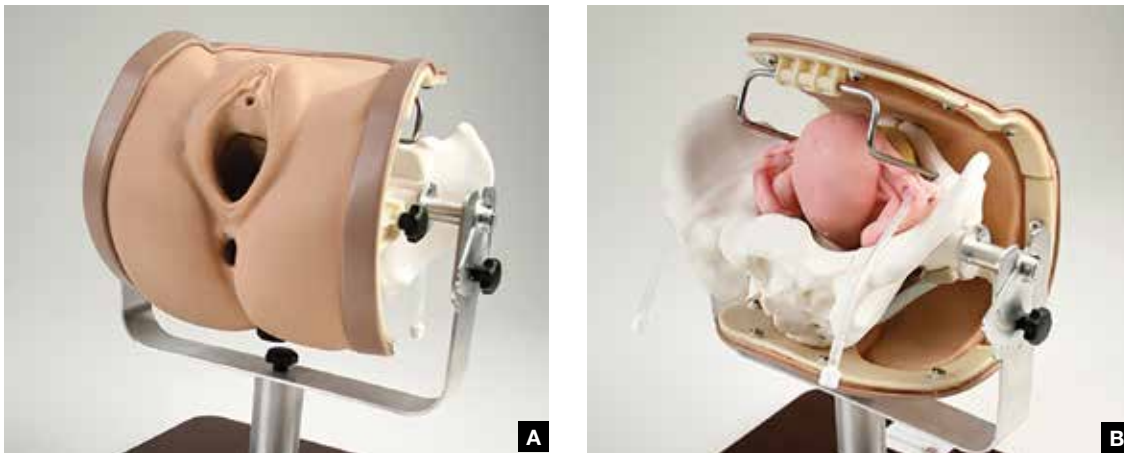
According to the Accreditation Council for Graduate Medical Education (ACGME), the minimum number of vaginal hysterectomies is 15; this number represents the minimum accepted exposure, however, and does not imply competency. Exposure to vaginal hysterectomy in residency training has significantly declined over the years, with a mean of only 19 vaginal hysterectomies performed by the time of graduation in 2014.¹

A wide range of simulation models are available

The authors report no financial relationships relevant to this article.

DISCLAIMER: The views expressed in this article are those of the authors and do not reflect the official policy or position of the US Government, the Department of Defense, or the US Army.

FIGURE 1 Front view (A) and back view (B) of the Miya Model Pelvic Surgery Training Model



Used with permission from Miyazaki Enterprises, Winston-Salem, North Carolina.

that you either can construct or purchase, based on your budget. We discuss 3 such models below.

The Miya model

The Miya Model Pelvic Surgery Training Model (Miyazaki Enterprises) consists of a bony pelvic frame and multiple replaceable and realistic anatomic structures, including the uterus, cervix, and adnexa (1 structure), vagina, bladder, and a few selected muscles and ligaments for pelvic floor disorders (FIGURE 1). The model incorporates features to simulate actual surgical experiences, such as realistic cutting and puncturing tensions, palpable surgical landmarks, a pressurized vascular system with bleeding for inadequate technique, and an inflatable bladder that can leak water if damaged.

Mounted on a rotating stand with the top of the pelvis open, the Miya model is designed to provide access and visibility, enabling supervising physicians the ability to give immediate guidance and feedback. The interchangeable parts allow the learner to be challenged at the appropriate skill level with the use of a large uterus versus a smaller uterus.

New in 2018 is an “intern” uterus and vagina that have no vascular supply and a single-layer vagina; this model is one-third of the cost of the larger, high-fidelity uterus (which has a vascular supply and additional tissue layers).

The Miya model reusable bony pelvic frame has a one-time cost of a few thousand dollars.

Advantages include its high fidelity, low technology, light weight, portability, and quick setup. To view a video of the Miya model, go to https://www.youtube.com/watch?time_continue=49&v=A2RjOgVRclo. To see a simulated vaginal hysterectomy, visit https://www.youtube.com/watch?time_continue=13&v=dwiQz4DTyy8.

The gynecologic surgeon and inventor, Dr. Douglas Miyazaki, has improved the vesicouterine peritoneal fold (usually the most challenging for the surgeon) to have a more realistic, slippery feel when palpated.

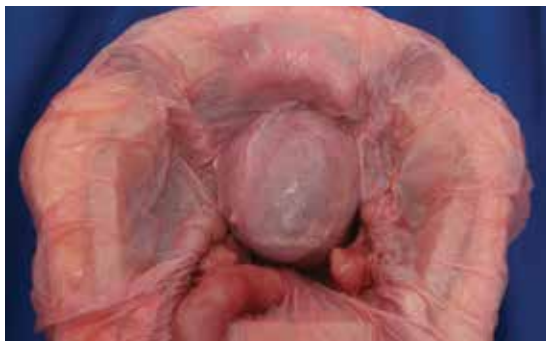This model’s weaknesses are its cost (relative to low-fidelity models) and the inability to use energy devices.

Takeaway. The Miya model is a high-fidelity, portable vaginal hysterectomy model with a reusable base and consumable replacement parts. It can be tailored to the learner’s desired level of difficulty.

The Gynesim model

The Gynesim Vaginal Hysterectomy Model, developed by Dr. Malcolm “Kip” Mackenzie (Gynesim), is a high-fidelity surgical simulation model constructed from animal tissue to provide realistic training in pelvic surgery (FIGURE 2, page SS8).

These “real tissue models” are hand-constructed from animal tissue harvested from US Department of Agriculture inspected meat processing centers. The models mimic normal and abnormal abdominal and pelvic anatomy,

FIGURE 2 Abdominal view of the Gynesim Vaginal Hysterectomy Model

Used with permission from Gynesim, Boston, Massachusetts.

providing realistic feel (haptics) and response to all surgical energy modalities. The “cassette” tissues are placed within a vaginal approach platform, which is portable.

Each model (including a 120- to 240-g uterus, bladder, ureter, uterine artery, cardinal and uterosacral ligaments, and rectum) supports critical gaps in surgical techniques such as peritoneal entry and cuff closure. Gynesim staff set up the entire laboratory, including the simulation models, instruments, and/or cameras; however, surgical energy systems are secured from the host institution.

The advantages of this model are its excellent tissue haptics and the minimal preparation time required from the busy gynecologic teaching faculty, as the company performs the setup and breakdown. Disadvantages include the model's cost (relative to low-fidelity models), that it does not bleed, its one-time use, and the need for technical assistance from the company for setup.

This model can be used for laparoscopic and open hysterectomy approaches, as well as for vaginal hysterectomy. For more information, visit the Gynesim website at <https://www.gynesim.com/vaginal-hysterectomy/>.

Takeaway. The high-fidelity Gynesim model can be used to practice vaginal, laparoscopic, or open hysterectomy approaches. It offers excellent tissue haptics, one-time use “cassettes” made from animal tissue, and compatibility with energy devices.

The milk jug model

The milk jug and fabric uterus model, developed by Dr. Dee Fenner, is a low-cost simulation model

and an alternative to the flower pot model (described later in this article). The bony pelvis is simulated by a 1-gallon milk carton that is taped to a foam ring. Other materials used to make the uterus are fabric, stuffing, and a needle and thread (or a sewing machine). Each model costs approximately \$5 and takes approximately 15 minutes to create. For instructions on how to construct this model, see the Society for Gynecologic Surgeons (SGS) award-winning video from 2012 at <https://vimeo.com/123804677>.

The advantages of this model are that it is inexpensive and is a good tool with which novice gynecologic surgeons can learn the basic steps of the procedure. The disadvantages are that it does not bleed, is not compatible with energy devices, and must be constructed by hand (adding considerable time) or with a sewing machine.

Takeaway. The milk jug model is a low-cost, low-fidelity model for the novice surgeon that can be quickly constructed with the use of a sewing machine.

Simulation models for training in laparoscopic hysterectomy

While overall hysterectomy numbers have remained relatively stable during the last 10 years, the proportion of laparoscopic hysterectomy procedures is increasing in residency training.¹ Many toolkits and models are available for practicing skills, from low-fidelity models on which to rehearse laparoscopic techniques (suturing, instrument handling) to high-fidelity models that provide augmented reality views of the abdominal cavity as well as the operating room itself. We offer a sampling of 4 such models below.

The FLS trainer system

The Fundamentals of Laparoscopic Surgery (FLS) Trainer Box (Limbs & Things Ltd) provides hands-on manual skills practice and training for laparoscopic surgery (**FIGURE 3**). The FLS trainer box uses 5 skills to challenge a surgeon's dexterity and psychomotor skills. The set includes the trainer box with a camera and light source as well as the equipment needed to perform the 5 FLS tasks (peg transfer, pattern cutting, ligating loop, and intracorporeal and extracorporeal knot tying). The kit does not include laparoscopic instruments or a monitor.

FIGURE 3 FLS Trainer system (A) components (minus the monitor and instruments) and (B) the unit in use



Used with permission from Limbs & Things Ltd, Savannah, Georgia.

The FLS trainer box with camera costs \$1,164. The advantages are that it is portable and can be used to warm-up prior to surgery or for practice to improve technical skills. It is a great tool for junior residents who are learning the basics of laparoscopic surgery. This trainer's disadvantages are that it is a low-fidelity unit that is procedure agnostic. For more information, visit the Limbs & Things website at <https://www.fls-products.com>.

Notably, ObGyn residents who graduate after May 31, 2020, will be required to successfully complete the FLS program as a prerequisite for specialty board certification.² The FLS program is endorsed by the American College of Surgeons and is run through the Society of American Gastrointestinal and Endoscopic Surgeons. The FLS test is proctored and must be taken at a testing center. **Takeaway.** The FLS trainer box is readily available, portable, relatively inexpensive, low-tech, and has valid benchmarks for proficiency. The FLS test will be required for ObGyn residents by 2020.

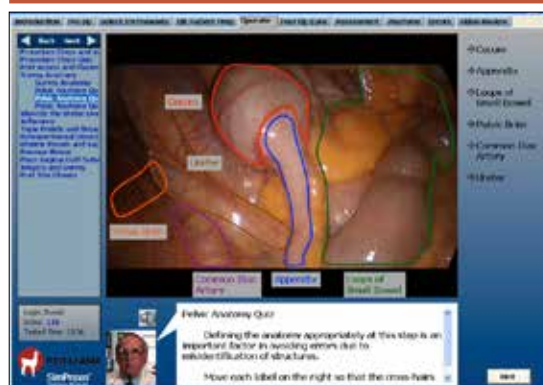The SimPraxis software trainer

The SimPraxis Laparoscopic Hysterectomy Trainer (Red Llama, Inc) is an interactive simulation software platform that is available in DVD or USB format (FIGURE 4). The software is designed to review anatomy, surgical instrumentation, and specific steps of the procedure. It provides formative assessments and offers summative feedback for users.

The SimPraxis training software would make a useful tool to familiarize medical students and interns with the basics of the procedure before advancing to other simulation trainers. The software costs \$100. For more information, visit <https://www.3-dmed.com/product/simpraxis%C3%82%C2%AE-laparoscopic-hysterectomy-trainer>.

Takeaway. The SimPraxis software is ideal for

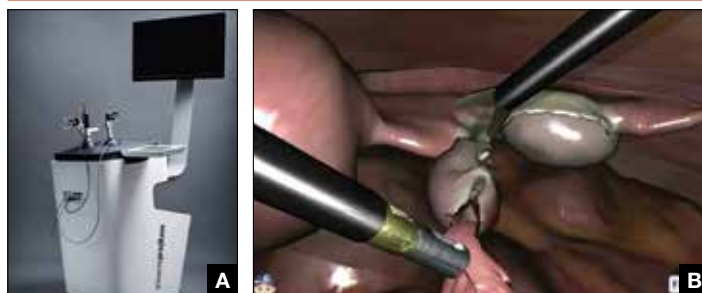FIGURE 4 Screenshot of the SimPraxis Laparoscopic Hysterectomy Trainer software program demonstrating pelvic structures



Used with permission from Red Llama, Inc, Seattle, Washington.

CONTINUED ON PAGE SS10

CONTINUED FROM PAGE SS9

FIGURE 5 The LapSim simulator (A) and the LapSim hysterectomy module (B) in action

Used with permission from Surgical Science, Göteborg, Sweden.

novice learners and can be used on a home or office computer.

The LapSim virtual reality trainer

The LapSim Haptic System (Surgical Science) is a virtual reality skills trainer. The hysterectomy module includes right and left uterine artery dissection, vaginal cuff opening, and cuff closure (FIGURE 5). One advantage of this simulator is its haptic feedback system, which enhances the fidelity of the training.

The LapSim simulator includes a training module for students and early learners and modules to improve camera handling. The virtual reality base system costs \$70,720, and the hysterectomy software module is an additional \$15,600.

For more information, visit the company's website at <https://surgiscience.com/systems/lapsim/>. For an informational video, go to <https://surgiscience.com/systems/lapsim/video/>.

Takeaway. The LapSim is an expensive, high-fidelity, virtual reality simulator with enhanced haptics and software for practicing laparoscopic hysterectomy.

The LAP Mentor virtual reality simulator

The LAP Mentor VR (3D Systems) is another virtual reality simulator that has modules for laparoscopic hysterectomy and cuff closure (FIGURE 6). The trainee uses a virtual reality headset and becomes fully immersed in the operating room environment with audio and visual cues that mimic a real surgical experience.

The hysterectomy module allows the user to manipulate the uterus, identify the ureters, divide

the superior pedicles, mobilize the bladder, expose and divide the uterine artery, and perform the colpotomy. The cuff closure module allows the user to suture the vaginal cuff using barbed suture. The module also can expose the learner to complications, such as bladder, ureteral, colon, or vascular injury.

The LAP Mentor VR base system costs \$84,000 and the modules cost about \$15,000. For additional information, visit the company's website at <http://symbionix.com/simulators/lap-mentor/lap-mentor-vr-or/>.

Takeaway. The LAP Mentor is an expensive, high-fidelity simulation platform with a virtual reality headset that simulates a laparoscopic hysterectomy (with complications) in the operating room.

Simulation models for training in robot-assisted laparoscopic hysterectomy

All robot-assisted simulation platforms have highly realistic graphics, and they are expensive (TABLE). However, the da Vinci Skills Simulator (backpack) platform is included with the da Vinci Si and Xi Systems. Note, though, that it can be challenging to access the surgeon console and backpack at institutions with high volumes of robot-assisted surgery.

Other options that generally reside outside of the operating room include Mimic's FlexVR and dV-Trainer and the Robotix Mentor by 3D Systems (FIGURES 7-11, page SS11.e1). Mimic's new technology, called MaestroAR (augmented reality), allows trainees to manipulate virtual robotic instruments to interact with anatomic regions within augmented 3D surgical video footage, with narration and instruction by Dr. Arnold Advincula.

Newer software by Symbionix allows augmented reality to assist the simulation of robot-assisted hysterectomy with the da Vinci Xi backpack and RobotiX platforms.

Models for training in abdominal hysterectomy

In the last 10 years, there has been a 30% decrease in the number of abdominal hysterectomies

FIGURE 6 The LAP Mentor VR simulation unit (A) and the Lap Mentor VR operating room (B) experienced via a headset



Used with permission from 3D Systems, Airport City, Israel.

There are not many simulation models available for teaching abdominal hysterectomy, but here we discuss 2 that we utilize in our residency program.

Adaptable task trainer

The Surgical Female Pelvic Trainer (SFPT) (Limbs & Things Ltd), a pelvic task trainer primarily used for simulation of laparoscopic hysterectomy, can be adapted for abdominal hysterectomy by removing the abdominal cover (FIGURE 12, page SS11.e2). This trainer can be used with simulated blood to increase the realism of training. The SFPT trainer costs \$2,190. For more information, go to [https://www.limbsandthings.com/us/our-products/details/surgical](https://www.limbsandthings.com/us/our-products/details/surgical-female-pelvic-trainer-sfpt-mk-2)

-female-pelvic-trainer-sfpt-mk-2.

Takeaway. The SFPT is a medium-fidelity task trainer with a reusable base and consumable replacement parts.

performed by residents.¹ Because of this decline in operating room experience, simulation training can be an important tool to bolster residency experience.

TABLE Simulation platforms for robot-assisted laparoscopic hysterectomy

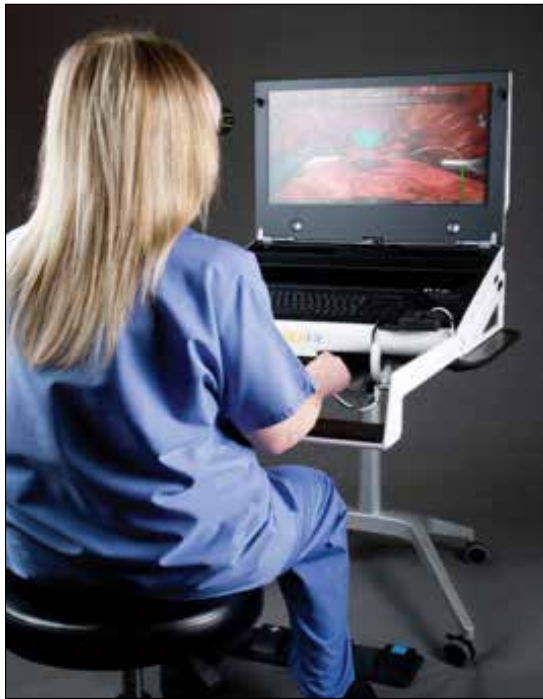Simulator	Company, website	Evaluation tools and software capabilities	Video demonstration
FlexVR	Mimic http://www.mimic-simulation.com/flexvr2/	MScore, ^a MaestroAR	https://www.youtube.com/watch?time_continue=37&v=5Va47qVmQNo
dV-Trainer	Mimic http://mimicsimulation.com/dv-trainer/	MScore, ^a MaestroAR	https://www.youtube.com/watch?v=qTsX1jOs3jl
da Vinci Skills Simulator (backpack) for Si and Xi platforms	Intuitive Surgical; Mimic https://www.intuitive-surgical.com/products/skills_simulator/index.php	MScore ^a for Si platform with procedure-agnostic software by Mimic Xi platform with procedure-specific modules with software by Symbionix	https://www.youtube.com/watch?v=utb-8YCvCHY
RobotiX Mentor	3D Systems http://symbionix.com/simulators/robotix-mentor/robotix-platform/	Augmented reality with software by Symbionix	https://vimeo.com/216811228 (hysterectomy demo plays up to the 1:10 minute mark)

^aMimic's MScore is a proficiency-based skills assessment that tracks metrics over time.

CONTINUED ON PAGE SS11.e1

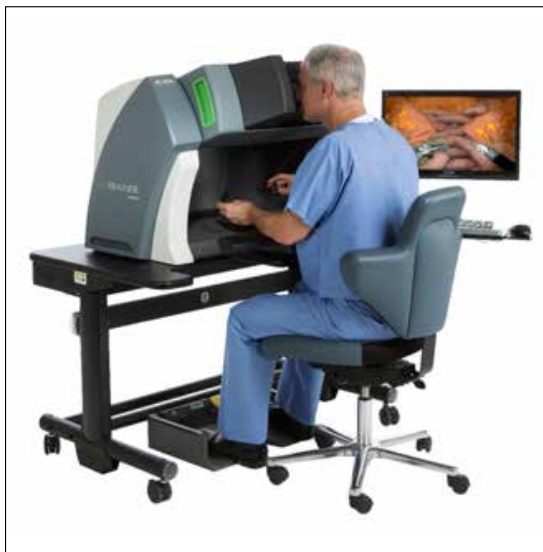CONTINUED FROM PAGE SS11

FIGURE 7 FlexVR simulator with 3D glasses



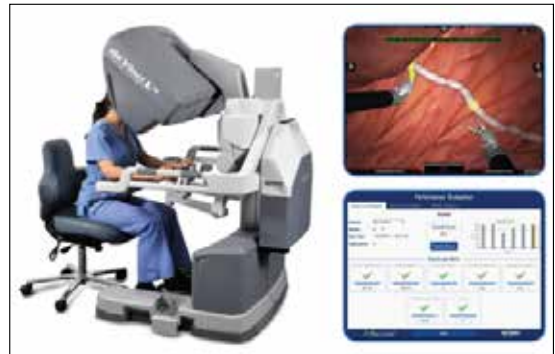Used with permission from Mimic Technologies, Inc, Seattle, Washington.

FIGURE 8 dV-Trainer simulator with MaestroAR (augmented reality)



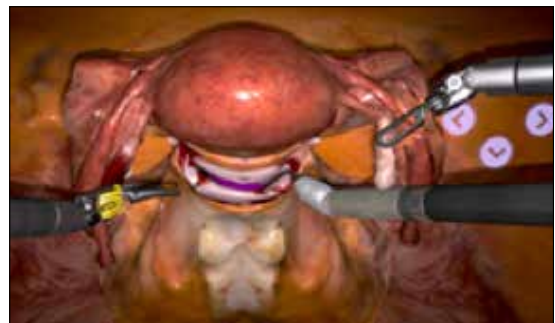
Used with permission from Mimic Technologies, Inc, Seattle, Washington.

FIGURE 9 The da Vinci Skills Simulator with MScore



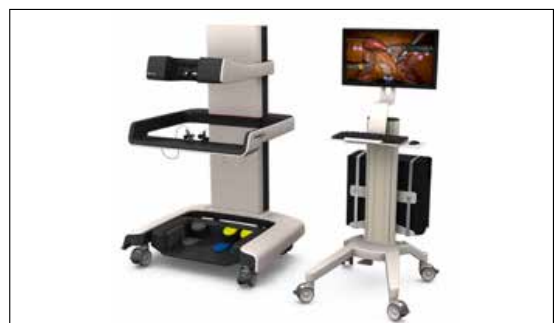Used with permission from Intuitive Surgical, Sunnyvale, California.

FIGURE 10 Symbionix software for hysterectomy available for use on the da Vinci Xi System




Used with permission from 3D Systems, Airport City, Israel.

FIGURE 11 RobotiX Mentor surgeon console and monitor with Symbionix software for hysterectomy



Used with permission from 3D Systems, Airport City, Israel.

FIGURE 12 Surgical Female Pelvic Trainer model (A) and model (B) with abdominal cover removed



Used with permission from Limbs & Things Ltd, Savannah, Georgia.

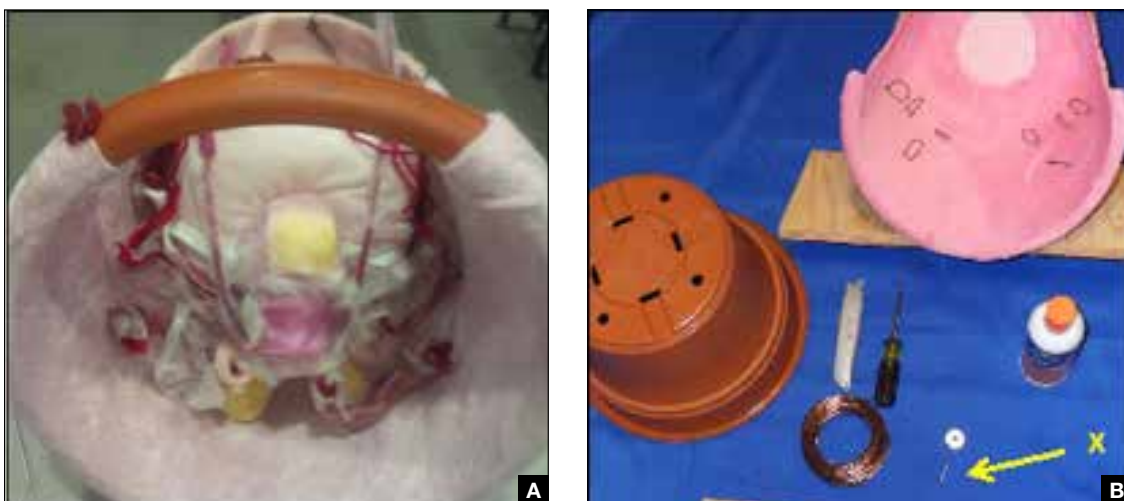ACOG's do-it-yourself flower pot model

The flower pot model (developed by the ACOG Simulation Working Group, Washington, DC) is a comprehensive educational package that includes learning objectives, simulation construction instructions, content review of the abdominal hysterectomy, quiz, and evaluation form.³ ACOG has endorsed this low-cost model for residency education.

Each model costs approximately \$20, and the base (flower pot) is reusable (FIGURE 13). Construction time for each model is 30 to 60 minutes, and learners can participate in the construction. This can aid in anatomy review and familiarization with the model prior to training in the surgical procedure.

The learning objectives, content review, quiz, and evaluation form can be used for the flower pot model or for high-fidelity models.

FIGURE 13 ACOG's flower pot model (A) assembled and (B) model materials



Images courtesy of Kristiina Altman, MD; Dayna Burrell, MD; Grace Chen, MD; Betty Chou, MD; and Tola Fashokun, MD; Johns Hopkins University School of Medicine, Department of Obstetrics and Gynecology, Baltimore, Maryland.

Used with permission from the American College of Obstetricians and Gynecologists.

CONTINUED ON PAGE SS11.e3

CONTINUED FROM PAGE SS11.e2

The advantages of this model are the low cost and that it provides enough fidelity to teach each of the critical steps of the procedure. The disadvantages include that it is a lower-fidelity model, requires a considerable amount of time for construction, does not bleed, and is not compatible with energy devices. This model also can be used for training in laparoscopic and vaginal hysterectomy. For more information, visit ACOG's Surgical Curriculum website at <https://cfweb.acog.org/scog/>.

Takeaway. ACOG's flower pot model for hysterectomy training is a comprehensive, low-cost, low-fidelity simulation model that requires significant setup time.

Simulation's offerings

Simulation training is the present and future of medicine that bridges the gap between textbook learning and technical proficiency. Although in this article we describe only a handful of the simulation resources available, we hope that you will

incorporate such tools into your practice for continuing education and skill development. Utilize peer-reviewed resources, such as the ACOG curriculum module and evaluation tools for abdominal, laparoscopic, and vaginal hysterectomy, which can be used with any simulation model to provide a comprehensive and complimentary learning experience.

The future of health care depends on the commitment and ingenuity of educators who embrace medical simulation's purpose: improved patient safety, effectiveness, and efficiency. Join the movement! ■

References

1. Washburn EE, Cohen SL, Manoucheri E, Zurawin RK, Einarsson JJ. Trends in reported resident surgical experience in hysterectomy. *J Minim Invasive Gynecol.* 2014;21(6):1067-1070.
2. American Board of Obstetrics and Gynecology. ABOG announces new eligibility requirement for board certification. https://www.abog.org/new/ABOG_FLS.aspx. Published January 22, 2018. Accessed April 10, 2018.
3. Altman K, Burrell D, Chen G, Chou B, Fashokun T. Surgical curriculum in obstetrics and gynecology: vaginal hysterectomy simulation. <https://cfweb.acog.org/scog/scog008/Simulation.cfm>. Published December 2014. Accessed April 10, 2018.