

Treatment Options for Pilonidal Sinus

Mary-Margaret Kober, MD; Usha Alapati, MD; Amor Khachemoune, MD

PRACTICE POINTS

- Mild pilonidal disease can be treated with conservative measures, including phenol injection and simple excision and drainage. Recurrent disease or the presence of extensive scarring or suppurative disease typically necessitates excision with flap closure.
- Off-midline procedures have been shown to be statistically superior to midline closure with regard to healing time, infection at the surgical site, and rate of recurrence.
- Laser excision holds promise as a primary or adjuvant treatment of pilonidal disease; however, large randomized controlled trials are needed to confirm early findings.

Pilonidal sinus disease often presents as a chronic problem in otherwise healthy hirsute men. A range of conservative techniques to surgical flaps have been employed to treat this condition. We review the literature on management of pilonidal sinus disease, including conservative and surgical techniques as well as novel laser therapy. Given current evidence, off-midline repair is now considered the standard of care; however, no statistically significant difference has been noted between primary versus secondary closure or between the Karydakias flap and Limberg flap. Treatment should be tailored to the individual, taking into account recurrent disease, recovery time, and the surgeon's comfort with the procedure.

Cutis. 2018;102:E23-E29.

Pilonidal disease was first described by Mayo¹ in 1833, who hypothesized that the underlying etiology is incomplete separation of the mesoderm and ectoderm layers during embryogenesis. In 1880, Hodges² coined the term *pilonidal sinus*; he postulated that sinus formation was incited by hair.² Today, Hodges theory is known as the acquired theory: hair induces a foreign body response in surrounding tissue, leading to sinus

formation. Although pilonidal cysts can occur anywhere on the body, they most commonly extend cephalad in the sacrococcygeal and upper gluteal cleft (Figure 1).^{3,4} An acute pilonidal cyst typically presents with pain, tenderness, and swelling, similar to the presentation of a superficial abscess in other locations; however, a clue to the diagnosis is the presence of cutaneous pits along the midline of the gluteal cleft.⁵ Chronic pilonidal disease varies based on the extent of inflammation and scarring; the underlying cavity communicates with the overlying skin through sinuses and often drains with pressure.⁶

Pilonidal sinuses are rare before puberty or after 40 years of age⁷ and occur primarily in hirsute men. The ratio of men to women affected is between 3:1 and 4:1.⁸ Although pilonidal sinuses account for only 15% of

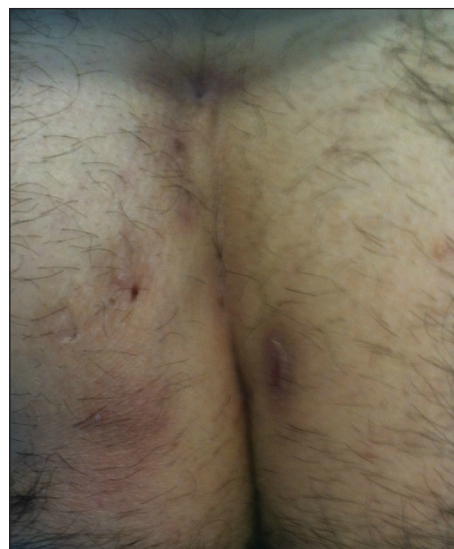

FIGURE 1. Pilonidal sinuses showing with multiple open and scarred sinus tracts on the bilateral buttocks and gluteal cleft of a hirsute man.

From the Department of Dermatology, State University of New York Downstate, Brooklyn. Drs. Alapati and Khachemoune also are from the Department of Dermatology, Brooklyn Campus of the VA NY Harbor Healthcare System.

The authors report no conflict of interest.

Correspondence: Amor Khachemoune, MD, Brooklyn Campus of the VA NY Harbor Healthcare System, 800 Poly Pl, Brooklyn, NY 11209 (amorkh@gmail.com).

anal suppurations, complications arising from pilonidal sinuses are a considerable cause of morbidity, resulting in loss of productivity in otherwise healthy individuals.⁹ Complications include chronic nonhealing wounds,¹⁰ as recurrent pilonidal sinuses tend to become colonized with gram-positive and facultative anaerobic bacteria, whereas primary pilonidal cysts more commonly become infected with anaerobic and gram-negative bacteria.¹¹ Long-standing disease increases the risk of squamous cell carcinoma arising within sinus tracts.^{10,12}

Histopathologically, pilonidal cysts are not true cysts because they lack an epithelial lining. Examination of the cavity commonly reveals hair, debris, and granulation tissue with surrounding foreign-body giant cells (Figure 2).⁵

The preferred treatment of pilonidal cysts continues to be debated. In this article, we review evidence supporting current modalities including conservative and surgical techniques as well as novel laser therapy for the treatment of pilonidal disease.

Conservative Management Techniques

Phenol Injections—Liquid or crystallized phenol injections have been used for treatment of mild to moderate pilonidal cysts.¹³ Excess debris is removed by curettage, and phenol is administered through the existing orifices or pits without pressure. The phenol remains in the cavity for 1 to 3 minutes before aspiration. Remaining cyst contents are removed through tissue manipulation, and the sinus is washed with saline. Mean healing time is 20 days (range, \pm 14 days).¹³

Classically, phenol injections have a failure rate of 30% to 40%, especially with multiple sinuses and suppurative disease⁶; however, the success rate improves with limited disease (ie, no more than 1–3 sinus pits).³ With multiple treatment sessions, a recurrence rate as low as 2% over 25 months has been reported.¹⁴ Phenol injection

also has been proposed as an adjuvant therapy to pit excision to minimize the need for extensive surgery.¹⁵

Simple Incision and Drainage—Simple incision and drainage has a crucial role in the treatment of acute pilonidal disease to decrease pain and relieve tension. Off-midline incisions have been recommended because the resulting closures fared better against sheer forces applied by the gluteal muscles on the cleft.⁶ Therefore, the incision often is made off-midline from the gluteal cleft even when the cyst lies directly on the gluteal cleft.

Rates of healing vary widely after incision and drainage, ranging from 45% to 82%.⁶ Primary pilonidal cysts may respond well, particularly if the cavity is abraded; in one series, 79% (58/73) of patients did not have a recurrence at the average follow-up of 60 months.¹⁶

Excision and Unroofing—Techniques for excision and unroofing without primary closure include 2 variants: wide and limited. The wide technique consists of an inwardly slanted excision that is deepest in the center of the cavity. The inward sloping angle of the incision aids in healing because it allows granulation to progress evenly from the base of the wound upward. The depth of the incision should spare the fascia and leave as much fatty tissue as possible while still resecting the entire cavity and associated pits.⁶ Limited incision techniques aim to shorten the healing period by making smaller incisions into the sinuses, pits, and secondary tracts, and they are frequently supplemented with curettage.⁶ Noteworthy disadvantages include prolonged healing time, need for professional wound management, and extended medical observation.⁵ The average duration of wound healing in a study of 300 patients was 5.4 weeks (range, \pm 1.1 weeks),¹⁷ and the recurrence rate has ranged from 5% to 13%.^{18,19} Care must be taken to respond to numerous possible complications, including excessive exudation and granulation, superinfection, and walling off.⁶

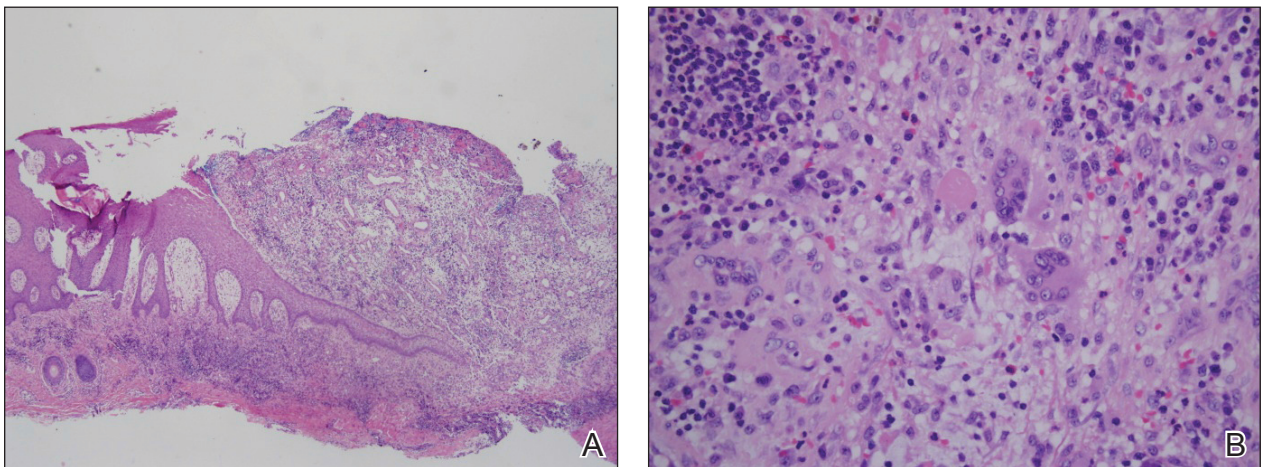


FIGURE 2. A shave biopsy specimen of a pilonidal sinus demonstrated dense inflammation and erosion bordering a sinus tract lined by granulation tissue and stratified squamous epithelium (A)(H&E, original magnification \times 4). The sinus tract connects with a chronic abscess cavity that contains foreign-body giant cells, plasma cells, and neutrophils (B)(H&E, original magnification \times 40).

Although the cost of treatment varies by hospital, location, and a patient's insurance coverage, patient reports to the Pilonidal Support Alliance indicate that the cost of conservative management ranges from \$500 to \$2000.²⁰

Excision and Primary Closure—An elliptical excision that includes some of the lateral margin is excised down to the level of the fascia. Adjacent lateral tracts may be excised by expanding the incision. To close the wound, edges are approximated with placement of deep and superficial sutures. Wound healing typically occurs faster than secondary granulation, as seen in one randomized controlled trial with a mean of 10 days for primary closure compared to 13 weeks for secondary intention.²¹ However, as with any surgical procedure, postoperative complications can delay wound healing.¹⁹ The recurrence rate after primary closure varies considerably, ranging from 10% to 38%.^{18,21-23} The average cost of an excision ranges from \$3000 to \$6000.²⁰

A Cochrane review evaluated 26 studies comparing primary and secondary closure. This large analysis showed no clear benefit for open healing over surgical closure²⁴; however, off-midline closure showed statistically significant benefit over midline closure (mean difference, 5.4 days; 95% CI, 2.3-8.5), and many experts now consider off-midline closure the standard of care in pilonidal sinus management (Figure 3).^{24,25}

Surgical Techniques

For severe or recurrent pilonidal disease, skin flaps often are required. Several flaps have been developed, including advancement, Bascom cleft lift, Karydakis, and modified Limberg flap. Flaps require a vascular pedicle but allow for closure without tension.²⁶ The cost of a flap procedure, ranging from \$10,000 to \$30,000, is greater than the cost of excision or other conservative therapy²⁰; however,

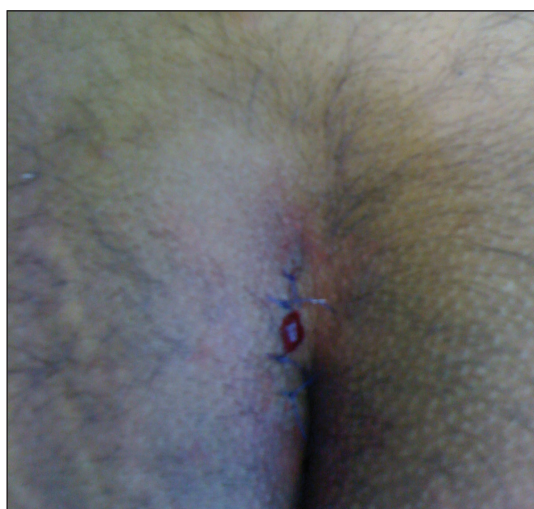


FIGURE 3. Gross image of off-midline primary closure after excision of the defect.

with a lower recurrence rate of pilonidal disease following flap procedures compared to other treatments, patients may save more on treatment over the long-term.

Advancement Flaps—The most commonly used advancement flaps are the V-Y advancement flap and Z-plasty. The V-Y advancement flap creates a full-thickness V-shaped incision down to gluteal fascia that is closed to form a postrepair suture line in the shape of a Y.⁵ Depending on the size of the defect, the flaps may be utilized unilaterally or bilaterally. A defect as large as 8 to 10 cm can be covered unilaterally; however, defects larger than 10 cm commonly require a bilateral flap.²⁶ The V-Y advancement flap failed to show superiority to primary closure techniques based on complications, recurrence, and patient satisfaction in a large randomized controlled trial.²⁷

Performing a Z-plasty requires excision of diseased tissue with recruitment of lateral flaps incised down to the level of the fascia. The lateral edges are transposed to increase transverse length.²⁶ No statistically significant difference in infection or recurrence rates was noted between excision alone and excision plus Z-plasty; however, wounds were reported to heal faster in patients receiving excision plus Z-plasty (41 vs 15 days).²⁸

Cleft Lift Closure—In 1987, Bascom²⁹ introduced the cleft lift closure for recurrent pilonidal disease. This technique aims to reduce or eliminate lateral gluteal forces on the wounds by filling the gluteal cleft.⁵ The sinus tracts are excised and a full-thickness skin flap is extended across the cleft and closed off-midline. The adipose tissue fills in the previous space of the gluteal cleft. In the initial study, no recurrences were reported in 30 patients who underwent this procedure at 2-year follow-up; similarly, in another case series of 26 patients who underwent the procedure, no recurrences were noted at a median follow-up of 3 years.³⁰ Compared to excision with secondary wound healing and primary closure on the midline, the Bascom cleft lift demonstrated a decrease in wound healing time (62, 52, and 29 days, respectively).³¹

The classic Karydakis flap consists of an oblique elliptical excision of diseased tissue with fixation of the flap base to the sacral fascia (Figures 4 and 5). The flap is closed by suturing the edge off-midline.³² This technique prevents a midline wound and aims to remodel and flatten the natal cleft. Karydakis³³ performed the most important study for treatment of pilonidal disease with the Karydakis flap, which included more than 5000 patients. The results showed a 0.9% recurrence rate and an 8.5% wound complication rate over a 2- to 20-year follow-up.³³ These results have been substantiated by more recent studies, which produced similar results: a 1.8% to 5.3% infection rate and a recurrence rate of 0.9% to 4.4%.^{34,35}

In the modified Karydakis flap, the same excision and closure is performed without tacking the flap to the sacral fascia, aiming to prevent formation of a new vulnerable raphe by flattening the natal cleft. The infection rate was

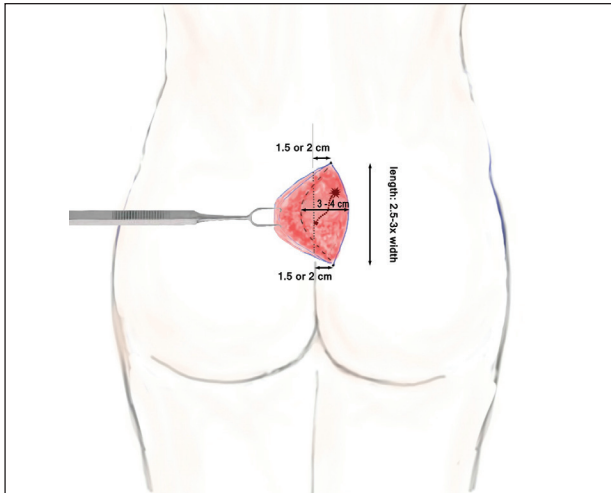


FIGURE 4. Anterior view of Karydakis flap. Oblique excision of diseased tissue was performed. Note the flap dimensions.

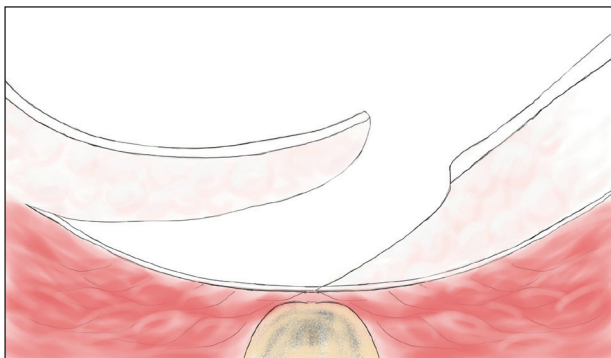


FIGURE 5. Cross-section view of Karydakis flap. The base of the flap is sutured to the sacral fascia. The final position is off-midline.

similar to the classic Karydakis flap, and no recurrences were noted during a 20-month follow-up.³⁶

Limberg Flap—The Limberg flap is derived from a rhomboid flap. In the classic Limberg flap, a midline rhomboid incision to the presacral fascia including the sinus is performed. The flap gains mobility by extending the excision laterally to the fascia of the gluteus maximus muscle. A variant of the original flap includes the modified Limberg flap, which lateralizes the midline sutures and flattens the intergluteal sulcus. Compared to the traditional Limberg approach, the modified Limberg flap was associated with a lower failure rate at both early and late time points and a lower rate of infection^{37,38}; however, based on the data it is unclear when primary closure should be favored over a Limberg flap. Several studies show the recurrence rate to be identical; however, hospital stay and pain were reduced in the Limberg flap group compared to primary closure.^{39,40}

Results from randomized controlled trials comparing the modified Limberg flap to the Karydakis flap vary.

One of the largest prospective, randomized, controlled trials comparing the 2 flaps included 269 patients. Results showed a lower postoperative complication rate, lower pain scores, shorter operation time, and shorter hospital stay with the Karydakis flap compared to the Limberg flap, though no difference in recurrence was noted between the 2 groups.⁴¹

Two randomized controlled trials comprising 145 and 120 patients, respectively, showed no statistically significant difference between the Limberg flap and Karydakis flap with regard to complication rate, length of stay, and recurrence rate^{36,42}; however, patients in the Karydakis group reported subjectively feeling healed more quickly than patients in the modified Limberg flap group,⁴² and 1 of the 2 studies showed an increase in patient satisfaction with the modified Karydakis flap compared to modified Limberg flap.³⁶ In contrast to earlier studies, a 2009 study showed the Karydakis flap was associated with a higher wound infection rate than the Limberg flap group in a randomized trial of 100 patients (13/50 vs 4/50 patients).⁴³

Overall, larger prospective trials are needed to clarify the differences in outcomes between flap techniques. In our opinion, variations in postoperative complication and recurrence rates likely are due to differences in surgeon comfort and surgical technique. The Table provides a comprehensive list of trials comparing flap techniques.

Laser Therapy

Lasers are emerging as primary and adjuvant treatment options for pilonidal sinuses. Depilation with alexandrite, diode, and Nd:YAG lasers has demonstrated the most consistent evidence.⁵⁰⁻⁵⁴ The firm texture and quality of the hair is proposed to incite an inflammatory response with sinus formation; therefore, using a laser to permanently remove this factor may help prevent future disease.

Large randomized controlled trials are needed to fully determine the utility of laser therapy as a primary or adjuvant treatment in pilonidal disease; however, given that laser therapies address the core pathogenesis of pilonidal disease and generally are well tolerated, their use may be strongly considered.

Conclusion

With mild pilonidal disease, more conservative measures can be employed; however, in cases of recurrent or suppurative disease or extensive scarring, excision with flap closure typically is required. Although no single surgical procedure has been identified as superior, one review demonstrated that off-midline procedures are statistically superior to midline closure in healing time, surgical site infection, and recurrence rate.²⁴ Novel techniques continue to emerge in the management of pilonidal disease, including laser therapy. This modality shows promise as either a primary or adjuvant treatment; however, large randomized controlled trials are needed to confirm early findings.

Given that pilonidal disease most commonly occurs in the actively employed population, we recommend that

Treatment of Pilonidal Disease With Skin Flaps

Reference (Year)	Study Design	Total No. of Patients	Technique Used	Outcome	Follow-up Period
Okuş et al ⁴⁴ (2012)	Randomized controlled trial	93	Limberg flap (n=49) vs tension-free primary closure (n=44)	1 patient in each treatment group developed wound infection; 2 patients in the Limberg flap group (4.1%) and 2 in the primary closure group (4.5%) developed recurrence ($P>.05$)	Median, 29.5 mo (range, 8–43 mo)
Akan et al ⁴⁵ (2013)	Retrospective study	100	Modified Limberg flap vs phenol application	Rates of infection, hematoma, and wound dehiscence were higher in the Limberg flap group; no difference in recurrence was noted among the 2 groups	Mean, 26 mo
Bessa ³² (2013)	Randomized controlled trial	120	Modified Karydakias flap vs modified Limberg flap	Operative time was shorter in the modified Karydakias flap group ($P<.001$), but there were no statistically significant difference in rates of overall complications, wound infection, subcutaneous fluid collection, and hypoesthesia; full-thickness wound disruption with modified Limberg flap was 9% vs 0% with modified Karydakias flap ($P=.003$); recurrence developed in 1 patient (2%) in the modified Karydakias flap group vs 2 (3%) in the modified Limberg flap group ($P>.99$); patient satisfaction was statistically significantly higher with modified Karydakias flap than with modified Limberg flap ($P<.001$)	Median, 20.5 mo
Guner et al ⁴⁶ (2013)	Prospective, randomized, controlled trial	122	Limberg flap vs Bascom cleft lift procedure	Bascom cleft lift improved operative time and pain score; no statistically significant difference was seen in healing time, complications, or recurrence	Median, 13 mo
Hosseini et al ⁴⁷ (2013)	Interventional study	194	Modified excision and repair (n=61) vs wide excision and secondary repair (n=81) vs wide excision and flap (n=52)	Longer hospital stay ($P<.05$) with wide excision and flap vs the other 2 methods; 3 recurrences (1.5%) with wide excision and flap ($P<.05$) vs 0 in other methods; postoperative complications developed in 2 patients (3.3%) in modified excision and repair vs 15 (18.5%) in wide excision and secondary repair vs 17 (32.7%) in wide excision and flap ($P<.05$)	1 y
Karaca et al ⁴⁸ (2013)	Retrospective study	540	Limberg flap vs primary closure	No statistically significant difference in duration of hospitalization, complication rate, or recurrence rate between groups; return to work was statistically significantly shorter with Limberg flap ($P<.001$)	Mean, 30 mo
Rao et al ⁴⁹ (2015)	Retrospective study	40	Sinus excision plus Z-plasty	No recurrences; 2 patients (5%) with numbness over flap; 3 patients (7.5%) with infection; 5 patients (12.5%) with seroma	6–12 mo

dermatologic surgeons discuss treatment options with patients who have pilonidal disease, taking into consideration cost, length of hospital stay, and recovery time when deciding on a treatment course.

REFERENCES

- Mayo OH. *Observations on Injuries and Diseases of the Rectum*. London, England: Burgess and Hill; 1833.
- Hodges RM. Pilonidal sinus. *Boston Med Surg J*. 1880;103:485-486.
- Eryilmaz R, Okan I, Ozkan OV, et al. Interdigital pilonidal sinus: a case report and literature review. *Dermatol Surg*. 2012;38:1400-1403.
- Stone MS. Cysts with a lining of stratified epithelium. In: Bologna JL, Jorizzo JL, Schaffer JV, eds. *Dermatology*. 3rd ed. Amsterdam, Netherlands: Elsevier Limited; 2012:1917-1929.
- Khanna A, Rombeau JL. Pilonidal disease. *Clin Colon Rectal Surg*. 2011;24:46-53.
- de Parades V, Bouchard D, Janier M, et al. Pilonidal sinus disease. *J Visc Surg*. 2013;150:237-247.
- Harris CL, Laforet K, Sibbald RG, et al. Twelve common mistakes in pilonidal sinus care. *Adv Skin Wound Care*. 2012;25:325-332.
- Lindholt-Jensen C, Lindholt J, Beyer M, et al. Nd-YAG laser treatment of primary and recurrent pilonidal sinus. *Lasers Med Sci*. 2012;27:505-508.
- Oueidat D, Rizkallah A, Dirani M, et al. 25 years' experience in the management of pilonidal sinus disease. *Open J Gastro*. 2014;4:1-5.
- Gordon P, Grant L, Irwin T. Recurrent pilonidal sepsis. *Ulster Med J*. 2014;83:10-12.
- Ardelt M, Dittmar Y, Kocijan R, et al. Microbiology of the infected recurrent sacrococcygeal pilonidal sinus. *Int Wound J*. 2016;13:231-237.
- Eryilmaz R, Bilecik T, Okan I, et al. Recurrent squamous cell carcinoma arising in a neglected pilonidal sinus: report of a case and literature review. *Int J Clin Exp Med*. 2014;7:446-450.
- Kayaalp C, Aydin C. Review of phenol treatment in sacrococcygeal pilonidal disease. *Tech Coloproctol*. 2009;13:189-193.
- Dag A, Colak T, Turkmenoglu O, et al. Phenol procedure for pilonidal sinus disease and risk factors for treatment failure. *Surgery*. 2012;151:113-117.
- Olmez A, Kayaalp C, Aydin C. Treatment of pilonidal disease by combination of pit excision and phenol application. *Tech Coloproctol*. 2013;17:201-206.
- Jensen SL, Harling H. Prognosis after simple incision and drainage for a first-episode acute pilonidal abscess. *Br J Surg*. 1988;75:60-61.
- Kepeneci I, Demirkan A, Celasin H, et al. Unroofing and curettage for the treatment of acute and chronic pilonidal disease. *World J Surg*. 2010;34:153-157.
- Sondenaa K, Nesvik I, Anderson E, et al. Recurrent pilonidal sinus after excision with closed or open treatment: final results of a randomized trial. *Eur J Surg*. 1996;162:237-240.
- Spivak H, Brooks VL, Nussbaum M, et al. Treatment of chronic pilonidal disease. *Dis Colon Rectum*. 1996;39:1136-1139.
- Pilonidal surgery costs. Pilonidal Support Alliance website. <https://www.pilonidal.org/treatments/surgical-costs/>. Updated January 30, 2016. Accessed October 14, 2018.
- al-Hassan HK, Francis IM, Neglén P. Primary closure or secondary granulation after excision of pilonidal sinus? *Acta Chir Scand*. 1990;156:695-699.
- Khaira HS, Brown JH. Excision and primary suture of pilonidal sinus. *Ann R Coll Surg Engl*. 1995;77:242-244.
- Clothier PR, Haywood IR. The natural history of the post anal (pilonidal) sinus. *Ann R Coll Surg Engl*. 1984;66:201-203.
- Al-Khamis A, McCallum I, King PM, et al. Healing by primary versus secondary intention after surgical treatment for pilonidal sinus. *Cochrane Database Syst Rev*. 2010;1:CD006213.
- McCallum I, King PM, Bruce J. Healing by primary closure versus open healing after surgery for pilonidal sinus: systematic review and meta-analysis. *BMJ*. 2008;336:868-871.
- Lee PJ, Raniga S, Biyani DK, et al. Sacrococcygeal pilonidal disease. *Colorect Dis*. 2008;10:639-650.
- Nursal TZ, Ezer A, Calişkan K, et al. Prospective randomized controlled trial comparing V-Y advancement flaps with primary suture methods in pilonidal disease. *Am J Surg*. 2010;199:170-177.
- Fazeli MS, Adel MG, Lebaschi AH. Comparison of outcomes in Z-plasty and delayed healing by secondary intention of the wound after excision in the sacral pilonidal sinus: results of a randomized, clinical trial. *Dis Col Rectum*. 2006;49:1831-1836.
- Bascom JU. Repeat pilonidal operations. *Am J Surg*. 1987;154:118-122.
- Nordon IM, Senapati A, Cripps NP. A prospective randomized controlled trial of simple Bascom's technique versus Bascom's cleft closure in the treatment of chronic pilonidal disease. *Am J Surg*. 2009;197:189-192.
- Dudnik R, Veldkamp J, Nienhuijs S, et al. Secondary healing versus midline closure and modified Bascom natal cleft lift for pilonidal sinus disease. *Scand J Surg*. 2011;100:110-113.
- Bessa SS. Comparison of short-term results between the modified Karydakias flap and the modified Limberg flap in the management of pilonidal sinus disease: a randomized controlled study. *Dis Colon Rectum*. 2013;56:491-498.
- Karydakias GE. Easy and successful treatment of pilonidal sinus after explanation of its causative process. *Aust N Z J Surg*. 1992;62:385-389.
- Kitchen PR. Pilonidal sinus: excision and primary closure with a lateralised wound - the Karydakias operation. *Aust N Z J Surg*. 1982;52:302-305.
- Akinci OF, Coskun A, Uzunköy A. Simple and effective surgical treatment of pilonidal sinus: asymmetric excision and primary closure using suction drain and subcuticular skin closure. *Dis Colon Rectum*. 2000;43:701-706.
- Bessa SS. Results of the lateral advancing flap operation (modified Karydakias procedure) for the management of pilonidal sinus disease. *Dis Colon Rectum*. 2007;50:1935-1940.
- Mentes BB, Leventoglu S, Chin A, et al. Modified Limberg transposition flap for sacrococcygeal pilonidal sinus. *Surg Today*. 2004;34:419-423.
- Cihan A, Ucan BH, Comert M, et al. Superiority of asymmetric modified Limberg flap for surgical treatment of pilonidal cyst disease. *Dis Colon Rectum*. 2006;49:244-249.
- Muzi MG, Milito G, Cadeddu F, et al. Randomized comparison of Limberg flap versus modified primary closure for treatment of pilonidal disease. *Am J Surg*. 2010;200:9-14.
- Tavassoli A, Noorshafie S, Nazarzadeh R. Comparison of excision with primary repair versus Limberg flap. *Int J Surg*. 2011;9:343-346.
- Ates M, Dirican A, Sarac M, et al. Short and long-term results of the Karydakias flap versus the Limberg flap for treating pilonidal sinus disease: a prospective randomized study. *Am J Surg*. 2011;202:568-573.
- Can MF, Sevinc MM, Hancerliogullari O, et al. Multicenter prospective randomized trial comparing modified Limberg flap transposition and Karydakias flap reconstruction in patients with sacrococcygeal pilonidal disease. *Am J Surg*. 2010;200:318-327.
- Ersoy E, Devay AO, Aktimur R, et al. Comparison of short-term results after Limberg and Karydakias procedures for pilonidal disease: randomized prospective analysis of 100 patients. *Colorectal Dis*. 2009;11:705-710.
- Okuş A, Sevinç B, Karahan O, et al. Comparison of Limberg flap and tension-free primary closure during pilonidal sinus surgery. *World J Surg*. 2012;36:431-435.
- Akan K, Tihan D, Duman U, et al. Comparison of surgical Limberg flap technique and crystallized phenol application in the treatment of pilonidal sinus disease: a retrospective study. *Ulus Cerrahi Derg*. 2013;29:162-166.
- Guner A, Boz A, Ozkan OF, et al. Limberg flap versus Bascom cleft lift techniques for sacrococcygeal pilonidal sinus: prospective, randomized trial. *World J Surg*. 2013;37:2074-2080.
- Hosseini H, Heidari A, Jafarnejad B. Comparison of three surgical methods in treatment of patients with pilonidal sinus: modified excision and repair/wide excision/wide excision and flap in RASOUL, OMID and SADR hospitals (2004-2007). *Indian J Surg*. 2013;75:395-400.

48. Karaca AS, Ali R, Capar M, et al. Comparison of Limberg flap and excision and primary closure of pilonidal sinus disease, in terms of quality of life and complications. *J Korean Surg Soc.* 2013; 85:236-239.
49. Rao J, Deora H, Mandia R. A retrospective study of 50 cases of pilonidal sinus with excision of tract and Z-plasty as treatment of choice for both primary and recurrent cases. *Indian J Surg.* 2015;77(suppl 2): 691-693.
50. Landa N, Aller O, Landa-Gundin N, et al. Successful treatment of recurrent pilonidal sinus with laser epilation. *Dermatol Surg.* 2005; 31:726-728.
51. Oram Y, Kahraman D, Karıncaoğlu Y, et al. Evaluation of 60 patients with pilonidal sinus treated with laser epilation after surgery. *Dermatol Surg.* 2010;36:88-91.
52. Benedetto AV, Lewis AT. Pilonidal sinus disease treated by depilation using an 800 nm diode laser and review of the literature. *Dermatol Surg.* 2005;31:587-591.
53. Lindholt-Jensen CS, Lindholt JS, Beyer M, et al. Nd-YAG treatment of primary and recurrent pilonidal sinus. *Lasers Med Sci.* 2012;27:505-508.
54. Jain V, Jain A. Use of lasers for the management of refractory cases of hidradenitis suppurativa and pilonidal sinus. *J Cutan Aesthet.* 2012;5:190-192.