

Sweet Syndrome Induced by Oral Acetaminophen-Codeine Following Repair of a Facial Fracture

Laurence M. Bradley, MD; Shauna P. Higgins, MD; Monee M. Thomas, MD;
Ife J. Rodney, MD; Rebat M. Halder, MD



PRACTICE POINTS

- The rate of medication-induced Sweet syndrome is on the rise.
- Oral acetaminophen-codeine may induce Sweet syndrome.

Sweet syndrome (SS), also known as acute febrile neutrophilic dermatosis, is an uncommon condition that is clinically characterized by painful, well-demarcated, indurated, erythematous plaques or nodules that typically favor the head, neck, and arms, and are accompanied by fever. The disease is divided into several categories based on the underlying etiology, with the drug-induced variant comprising a rising number of the total cases and being reported in association with an increasing number of medications. We report a rare case of SS induced by an oral acetaminophen-codeine suspension and tablets. The importance of this case lies in the ability to educate both physicians and pharmacists alike regarding a newly recognized cutaneous adverse effect of acetaminophen-codeine so that the medication may be discontinued or substituted upon recognition of this adverse reaction to decrease patient morbidity.

Cutis. 2017;100:E20-E23.

In 1964, Sweet¹ described 8 women with acute onset of fever and erythematous plaques associated with a non-specific infection of the respiratory or gastrointestinal tract. The lesions were histologically characterized by a neutrophilic infiltrate, and the author named the constellation of findings *acute febrile neutrophilic dermatosis*.¹

In 1968, Whittle et al² reported on similar cases and coined the term *Sweet syndrome* (SS).

Although the etiology and pathogenesis of SS remain unknown, several theories have been proposed. Because SS often is preceded by a respiratory or gastrointestinal tract infection, it has been postulated that it may represent a hypersensitivity reaction or may be related to local or systemic dysregulation of cytokine secretion.^{3,4} In addition to respiratory or gastrointestinal tract infections, SS has been reported in association with malignancies, autoimmune diseases, drugs, vaccines, pregnancy, inflammatory bowel disease, and chemotherapy. It also may be idiopathic.⁵

The eruption of SS manifests as erythematous, indurated, and sharply demarcated plaques or nodules that typically favor the head, neck, and arms, with a particularly strong predilection for the dorsal aspects of the hands.⁶ Plaques and nodules are histologically characterized by a diffuse dermal neutrophilic infiltrate, papillary dermal edema, neutrophilic spongiosis, subcorneal pustules, and leukocytoclasia. Vasculitic features are not seen.⁷ The eruption typically resolves spontaneously in 5 to 12 weeks but recurs in approximately 30% of cases.⁸ Relatively common extracutaneous findings include ocular involvement, arthralgia, myalgia, and arthritis.^{4,9} Both cutaneous and extracutaneous findings typically are responsive to prednisone at a dosage of 0.5 to 1 mg/kg daily for 4 to 6 weeks. Prolonged low-dose prednisone for 2 to 3 additional months may be necessary to suppress recurrence.⁸ Potassium iodide at 900 mg daily may be used as an alternative regimen.^{3,8}

Drs. Bradley, Thomas, Rodney, and Halder are from the Department of Dermatology, Howard University Hospital, Washington, DC. Dr. Higgins is from the Department of Dermatology, Keck School of Medicine of the University of Southern California, Los Angeles.

The authors report no conflict of interest.

Correspondence: Laurence M. Bradley, MD, Howard University Hospital, Department of Dermatology, Ste 2107, 2041 Georgia Ave NW, Washington, DC (lbradley@huhosp.org).

Sweet syndrome is divided into 5 subcategories based on the underlying etiology: (1) classic or idiopathic, (2) paraneoplastic, (3) inflammatory and/or autoimmune disease related, (4) pregnancy related, and (5) drug induced.³ Although drug-induced SS comprises the minority of total cases (<5%), its reported incidence has been rising in recent years and has been associated with an escalating number of medications.¹⁰ We report a rare case of SS induced by administration of oral acetaminophen-codeine.

Case Report

A 32-year-old man with a history of diabetes mellitus underwent postoperative repair of a facial fracture. The patient was administered an oral acetaminophen-codeine suspension for postoperative pain control. One week later, he developed a painful eruption on the forehead and presented to the emergency department. He was prescribed acetaminophen-codeine 300/30-mg tablets every 6 hours in addition to hydrocortisone cream 1% applied every 6 hours. After this reintroduction of oral acetaminophen-codeine, he experienced intermittent fevers and an exacerbation of the initial cutaneous eruption. The patient presented for a second time 2 days after being seen in the emergency department and a dermatology consultation was obtained.

At the time of consultation, the patient was noted to have injected conjunctiva and erythematous, well-demarcated, and indurated plaques on the forehead with associated pain and burning (Figures 1A and 1B). Additional erythematous annular plaques were found on the palms, arms, and right knee. Laboratory workup revealed only mild anemia on complete blood cell count with a white blood cell count of $10.1 \times 10^9/L$ (reference range, $4.5\text{--}11.0 \times 10^9/L$), hemoglobin of 12.9 g/dL (reference range, 14.0–17.4 g/dL), and hematocrit of 37.3% (reference range, 41%–50%). The platelet count was $284 \times 10^3/\mu L$ (reference range, $150\text{--}350 \times 10^3/\mu L$). Basic metabolic panel was notable for an elevated glucose level of 418 mg/dL (reference range, 70–110 mg/dL). The most recent hemoglobin A_{1c} (several months prior) was notable at 14.7% of total hemoglobin (reference range, 4%–7% of total hemoglobin). A 4-mm punch biopsy of the right side of the forehead demonstrated minimal to mild papillary dermal edema and a diffuse dermal neutrophilic infiltrate spanning the upper, middle, and lower dermis with evidence of mild leukocytoclasia and no evidence of leukocytoclastic vasculitis (Figure 2). These histologic features together with the clinical presentation were consistent with a diagnosis of SS.

After an initial dose of intravenous methylprednisolone sodium succinate 125 mg in the emergency department, the patient was admitted for additional intravenous steroid administration in the context of uncontrolled hyperglycemia and history of poor glucose control. Upon admission, acetaminophen-codeine was discontinued and the patient was transitioned to intravenous

methylprednisolone sodium succinate 60 mg every 8 hours. The patient also was given intravenous diphenhydramine 25 mg every 6 hours and desonide ointment 0.05% was applied to facial lesions. The inpatient medication regimen resulted in notable improvement of symptoms within 48 hours. Due to rapid improvement with steroids, no special stains for infectious etiologies were performed. The patient was discharged after 3 days in the hospital with triamcinolone ointment 0.1% to be applied to affected areas twice daily. The patient experienced no recurrence 2 months after treatment (Figure 1C).

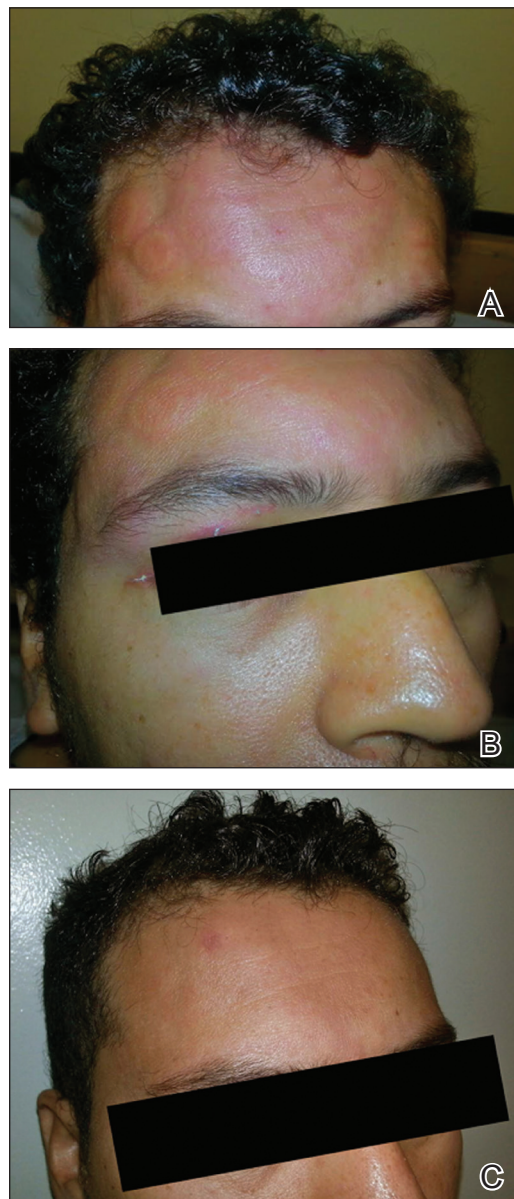

FIGURE 1. Sweet syndrome eruption secondary to acetaminophen-codeine. Erythematous, well-demarcated, and indurated annular and homogenous plaques were noted on the forehead on initial presentation (A and B). Faint erythematous patches scattered across the forehead were noted 2 months after completion of the treatment course (C).

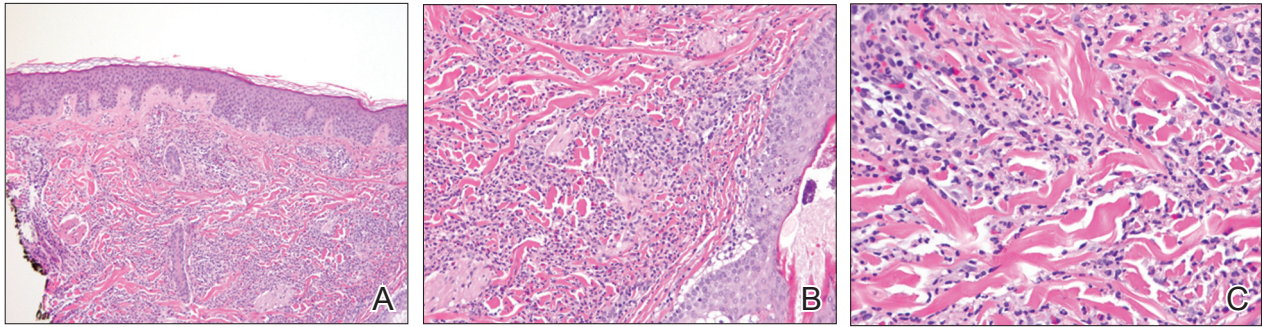


FIGURE 2. Histologic appearance of Sweet syndrome eruption. Diffuse, hypercellular inflammatory infiltrate within the dermis limited to mild papillary edema and no evidence of fibrinoid necrosis or other signs of leukocytoclastic vasculitis (A)(H&E, original magnification $\times 10$). Diffuse neutrophilic infiltrate within the dermis with scattered eosinophils, no leukocytoclastic vasculitis, and absence of fibrinoid necrosis (B)(H&E, original magnification $\times 20$). Dense neutrophilic infiltrate within the dermis with scattered eosinophils (C)(H&E, original magnification $\times 40$).

Comment

Although SS itself is relatively rare, there has been an increasing incidence of the drug-induced subtype, most often in association with use of granulocyte colony-stimulating factor and granulocyte monocyte-stimulating factor. There also have been reported associations with a growing number of medications that include antibiotics, antiepileptic drugs, furosemide, hydralazine, and all-*trans* retinoic acid.¹¹⁻¹⁹ Moghimi et al¹¹ also reported an association with antivirals, cancer biotherapies, non-steroidal anti-inflammatory drugs, psychotropes, azathioprine, oral contraceptives, and propylthiouracil.^{10,20-26} Moghimi et al¹¹ further reported an association with several vaccines.

Several therapies for advanced melanoma also have been reviewed in the literature, including ipilimumab and vemurafenib,²⁷⁻³⁰ as have several medications for the treatment of myelodysplastic syndrome including azacitidine.^{31,32} A severe episode of drug-induced SS, predominantly on the legs, has been reported in association with lenalidomide, an immunomodulatory agent used in the treatment of myelodysplastic syndrome.³³

Additional medications more recently involved in the pathogenesis of drug-induced SS include the chemotherapeutic agents topotecan, mitoxantrone, gemcitabine, and vorinostat.³⁴⁻³⁷ The antimalarial medication chloroquine also has been implicated, as have selective cyclooxygenase-2 inhibitors, hypomethylating agents, the tumor necrosis factor inhibitor adalimumab, IL-2 therapies, aripiprazole, and several other medications.³⁸⁻⁴⁹

Despite drug-induced SS being reported in association with an increasing number of medications, there had been a lack of appropriate diagnostic criteria. To that end, Walker and Cohen⁵⁰ proposed 5 specific diagnostic criteria in 1996, including abrupt onset of painful erythematous plaques or nodules, histopathologic evidence of a dense neutrophilic infiltrate without evidence of leukocytoclastic vasculitis, pyrexia (temperature $>38^{\circ}\text{C}$), temporal relationship between drug ingestion and clinical presentation or temporally related recurrence after oral rechallenge,

and temporally related resolution of lesions after drug withdrawal or treatment with systemic corticosteroids.^{50,51} Our patient met all of these criteria.

Conclusion

The number of cases of drug-induced SS in the literature continues to climb; however, the association with acetaminophen-codeine is unique. The importance of this case lies in educating both physicians and pharmacists alike regarding a newly recognized adverse effect of acetaminophen-codeine. Because acetaminophen-codeine often is used for its analgesic properties, and the predominant symptom of the cutaneous eruption of SS is pain, the therapeutic value of acetaminophen-codeine is substantially diminished in acetaminophen-codeine-induced SS. Accordingly, in these cases, the medication may be discontinued or substituted upon recognition of this adverse reaction to reduce patient morbidity.

REFERENCES

1. Sweet RD. An acute febrile neutrophilic dermatosis. *Br J Dermatol.* 1964;76:349-356.
2. Whittle CH, Back GA, Champion RH. Recurrent neutrophilic dermatosis of the face—a variant of Sweet's syndrome. *Br J Dermatol.* 1968;80:806-810.
3. Von den Driesch P. Sweet's syndrome (acute febrile neutrophilic dermatosis). *J Am Acad Dermatol.* 1994;31:535-536.
4. Honigsman H, Cohen PR, Wolff K. Acute febrile neutrophilic dermatosis (Sweet's syndrome). *Wien Klin Wochenschr.* 1979;91:842-847.
5. Limdiwala PG, Parikh SJ, Shah JS. Sweet's Syndrome. *Indian J Dent Res.* 2014;25:401-405.
6. Walling HW, Snipes CJ, Gerami P, et al. The relationship between neutrophilic dermatosis of the dorsal hands and sweet syndrome: report of 9 cases and comparison to atypical pyoderma gangrenosum. *Arch Dermatol.* 2006;142:57-63.
7. Ratzinger G, Burgdorf W, Zelger BG, et al. Acute febrile neutrophilic dermatosis: a histopathologic study of 31 cases with review of literature. *Am J Dermatopathol.* 2007;29:125-133.
8. Moschella SL, Davis MDP. Neutrophilic dermatoses. In: Bologna J, Jorizzo J, Rapini R, eds. *Dermatology.* 2nd ed. Philadelphia, PA: Elsevier; 2012: 423-428.
9. Fett DL, Gibson LE, Su WP. Sweet's syndrome: signs and symptoms and associated disorders. *Mayo Clinic Proc.* 1995;70:234-240.
10. Carvalho R, Fernandes C, Afonso A, et al. Drug-induced Sweet's syndrome by alclofenac. *Cutan Ocul Toxicol.* 2011;30:315-316.

11. Moghimi J, Pahlevan D, Azizzadeh M, et al. Isotretinoin-associated Sweet's syndrome: a case report. *Daru*. 2014;22:69.
12. Cholongitas E, Pipili C, Dasenaki M, et al. Piperacillin/tazobactam-induced Sweet syndrome in a patient with chronic lymphocytic leukemia and autoimmune cholangitis. *Am J Dermatopathol*. 2008;30:203-204.
13. Kandula S, Burke WS, Goldfarb JN. Clindamycin-induced Sweet syndrome. *J Am Acad Dermatol*. 2010;62:898-900.
14. Jamet A, Lagarce L, Le Clec'h C, et al. Doxycycline-induced Sweet's syndrome. *Eur J Dermatol*. 2008;18:595-596.
15. Cartee TV, Chen SC. Sweet syndrome associated with hydralazine-induced lupus erythematosus. *Cutis*. 2012;89:121-124.
16. Baybay H, Elhatimi A, Idrissi R, et al. Sweet's syndrome following oral ciprofloxacin therapy. *Ann Dermatol Venereol*. 2011;138:606-607.
17. Khaled A, Kharfi M, Fazaa B, et al. A first case of trimethoprim-sulfamethoxazole induced Sweet's syndrome in a child. *Pediatr Dermatol*. 2009;26:744-746.
18. Calixto R, Menezes Y, Ostronoff M, et al. Favorable outcome of severe, extensive, granulocyte colony-stimulating factor-induced, corticosteroid-resistant Sweet's syndrome treated with high-dose intravenous immunoglobulin. *J Clin Oncol*. 2014;32:E1-E2.
19. Margaretten ME, Ruben BS, Fye K. Systemic sulfa-induced Sweet's syndrome. *Arthritis Rheum*. 2008;59:1044-1046.
20. Tanguy-Schmidt A, Avenel-Audran M, Croué A, et al. Bortezomib-induced acute neutrophilic dermatosis. *Ann Dermatol Venereol*. 2009;136:443-446.
21. Choonhakarn C, Chaowattanapanit S. Azathioprine-induced Sweet's syndrome and published work review. *J Dermatol*. 2013;40:267-271.
22. Cyrus N, Stavert R, Mason AR, et al. Neutrophilic dermatosis after azathioprine exposure. *JAMA Dermatol*. 2013;149:592-597.
23. Hurtado-Garcia R, Escribano-Stablé JC, Pascual JC, et al. Neutrophilic dermatosis caused by azathioprine hypersensitivity. *Int J Dermatol*. 2012;51:1522-1525.
24. Valentine MC, Walsh JS. Neutrophilic dermatosis caused by azathioprine. *Skinmed*. 2011;9:386-388.
25. Kim JS, Roh HS, Lee JW, et al. Distinct variant of Sweet's syndrome: bortezomib-induced histiocytoid Sweet's syndrome in a patient with multiple myeloma. *Int J Dermatol*. 2012;51:1491-1493.
26. Ozlem C, Deram B, Mustafa S, et al. Propylthiouracil-induced anti-neutrophil cytoplasmic antibodies and agranulocytosis together with granulocyte colony-stimulating factor induced Sweet's syndrome in a patient with Graves' disease. *Intern Med*. 2011;50:1973-1976.
27. Kylo RL, Parker MK, Rosman I, et al. Ipilimumab-associated Sweet syndrome in a patient with high-risk melanoma. *J Am Acad Dermatol*. 2014;70:E85-E86.
28. Pintova S, Sidhu H, Friedlander PA, et al. Sweet's syndrome in a patient with metastatic melanoma after ipilimumab therapy. *Melanoma Res*. 2013;23:498-501.
29. Yorio JT, Mays SR, Ciurea AM, et al. Case of vemurafenib-induced Sweet's syndrome. *J Dermatol*. 2014;41:817-820.
30. Pattanaprichakul P, Tetzlaff MT, Lapolla WJ, et al. Sweet syndrome following vemurafenib therapy for recurrent cholangiocarcinoma. *J Cutan Pathol*. 2014;41:326-328.
31. Trickett HB, Cumpston A, Craig M. Azacitidine-associated Sweet's syndrome. *Am J Health Syst Pharm*. 2012;69:869-871.
32. Tintle S, Patel V, Ruskin A, et al. Azacitidine: a new medication associated with Sweet syndrome. *J Am Acad Dermatol*. 2011;64:E77-E79.
33. Thieu KP, Rosenbach M, Xu X, et al. Neutrophilic dermatosis complicating lenalidomide therapy. *J Am Acad Dermatol*. 2009;61:709-710.
34. Dickson EL, Bakhru A, Chan MP. Topotecan-induced Sweet's syndrome: a case report. *Gynecol Oncol Case Rep*. 2013;4:50-52.
35. Kimpfel T, Gerdes LA, Flaig M, et al. Drug-induced Sweet's syndrome after mitoxantrone therapy in a patient with multiple sclerosis. *Mult Scler*. 2011;17:495-497.
36. Martorell-Calatayud A, Requena C, Sanmartin O, et al. Gemcitabine-associated sweet syndrome-like eruption. *J Am Acad Dermatol*. 2011;65:1236-1238.
37. Pang A, Tan KB, Aw D, et al. A case of Sweet's syndrome due to 5-azacitidine and vorinostat in a patient with NK/T cell lymphoma. *Cutan Ocul Toxicol*. 2012;31:64-66.
38. El Moutaoui L, Zouhair K, Benchikhi H. Sweet syndrome induced by chloroquine. *Ann Dermatol Venereol*. 2009;136:56-57.
39. Rosmaninho A, Lobo I, Selores M. Sweet's syndrome associated with the intake of a selective cyclooxygenase-2 (COX-2) inhibitor. *Cutan Ocul Toxicol*. 2011;30:298-301.
40. Alencar C, Abramowitz M, Parekh S, et al. Atypical presentations of Sweet's syndrome in patients with MDS/AML receiving combinations of hypomethylating agents with histone deacetylase inhibitors. *Am J Hematol*. 2009;84:688-689.
41. Keidel S, McColl A, Edmonds S. Sweet's syndrome after adalimumab therapy for refractory relapsing polychondritis. *BMJ Case Rep*. 2011;2011.
42. Rondina A, Watson AC. Bullous Sweet's syndrome and pseudolymphoma precipitated by IL-2 therapy. *Cutis*. 2010;85:206-213.
43. Gheorghe L, Cotruta B, Trifu V, et al. Drug-induced Sweet's syndrome secondary to hepatitis C antiviral therapy. *Int J Dermatol*. 2008;47:957-959.
44. Zobniw CM, Saad SA, Kostoff D, et al. Bortezomib-induced Sweet's syndrome confirmed by rechallenge. *Pharmacotherapy*. 2014;34:E18-E21.
45. Kolb-Mäurer A, Kneitz H, Goebeler M. Sweet-like syndrome induced by bortezomib. *J Dtsch Dermatol Ges*. 2013;11:1200-1202.
46. Thuillier D, Lenglet A, Chaby G, et al. Bortezomib-induced eruption: Sweet syndrome? two case reports [in French]. *Ann Dermatol Venereol*. 2009;136:427-430.
47. Kim MJ, Jang KT, Choe YH. Azathioprine hypersensitivity presenting as sweet syndrome in a child with ulcerative colitis. *Indian Pediatr*. 2011;48:969-971.
48. Truchuelo M, Bagazgoitia L, Alcántara J, et al. Sweet-like lesions induced by bortezomib: a review of the literature and a report of 2 cases. *Actas Dermosifiliogr*. 2012;103:829-831.
49. Hoelt P, Fattouh K, Villani AP. Dermopath & clinic: drug-induced Sweet syndrome. *Eur J Dermatol*. 2016;26:641-642.
50. Walker DC, Cohen PR. Trimethoprim-sulfamethoxazole-associated acute febrile neutrophilic dermatosis: case report and review of drug-induced Sweet's syndrome. *J Am Acad Dermatol*. 1996;34:918-923.
51. Thompson DF, Montarella KE. Drug-induced Sweet's syndrome. *Ann Pharmacother*. 2007;41:802-811.