

Sunburn Purpura

Jameson T. Loyal, MD; Nicholas R. Sinclair, MD; Jeremy M. Hugh, MD;
Deborah L. Cook, MD; Joseph C. Pierson, MD



PRACTICE POINTS

- Petechial skin changes acutely following intense sun exposure is a rare phenomenon referred to as sunburn purpura, photolocalized purpura, or solar purpura.
- Idiopathic sunburn purpura should only be diagnosed after vasculitis and/or thrombocytopenia is ruled out, which is best achieved through skin biopsy and a platelet count, respectively.
- The rash typically resolves without treatment in 1 to 2 weeks; however, a variety of UV protection modalities and education should be offered to the patient.

To the Editor:

Chronic UV exposure has been linked to increased skin fragility and the development of purpuric lesions, a benign condition known as actinic purpura and commonly seen in elderly patients. Petechial skin changes acutely following intense sun exposure is a rare phenomenon referred to as sunburn purpura, photolocalized purpura, or solar purpura.

A 19-year-old woman presented with red and purple spots on the pretibial region of both legs extending to the thigh. One week prior to presentation she had a severe sunburn affecting most of the body, which resolved without blistering. Two days later, the spots appeared within the most severely sunburned areas of both legs. The patient reported that the lesions were mildly painful to palpation, but she was more concerned about the appearance. She denied any history of similar skin changes associated with sun exposure. The patient was otherwise healthy and denied any recent illnesses. She noted a history of mild bruising and bleeding with a resulting unremarkable workup by her primary care physician.

The only medication taken was etonogestrel–ethinyl estradiol vaginal ring.

The scalp, face, arms, trunk, and legs were examined, and nonpalpable petechial changes were noted on the anterior aspect of the legs (Figure 1), with changes more prominent on the distal aspect of the legs. Mild superficial epidermal exfoliation was noted on both anterior thighs. The area of the lesions was not warm. The lesions were mildly tender to palpation. The remainder of the physical examination was unremarkable.

Given the timing of onset, preceding sun exposure, and the morphologic characteristics of the lesions, sunburn purpura was suspected. A punch biopsy of the anterior aspect of the left thigh was performed to rule out vasculitis. Microscopic examination revealed reactive epidermal changes with mild vascular ectasia and erythrocyte extravasation not associated with

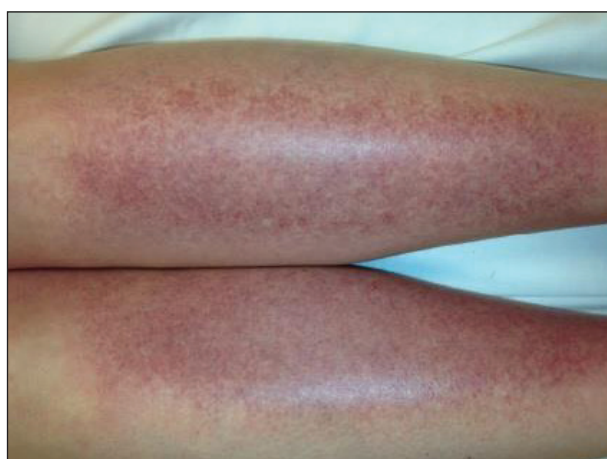

FIGURE 1. Idiopathic sunburn purpura at presentation with a petechial rash on the pretibial region of both legs.

From the University of Vermont Medical Center and the University of Vermont Larner College of Medicine, Burlington. Drs. Loyal, Sinclair, Hugh, and Pierson are from the Division of Dermatology, and Dr. Cook is from the Department of Pathology and Laboratory Medicine.

The authors report no conflict of interest.

Correspondence: Jameson T. Loyal, MD, Given #287, UVM College of Medicine, 89 Beaumont Ave, Burlington, VT 05405-0068 (Jameson.Loyal@med.uvm.edu).

appreciable inflammation or evidence of vascular injury (Figure 2). Biopsy exposure to fluorescein-labeled antibodies directed against IgG, IgM, IgA, C3, and polyvalent immunoglobulins (IgG, IgM, and IgA) yielded no immunofluorescence. These biopsy results were consistent with sunburn purpura. Given the patient's normal platelet count, a diagnosis of idiopathic sunburn purpura was made. The patient was informed of the biopsy results and advised that the petechiae should resolve without treatment in 1 to 2 weeks, which occurred.

Sunburn purpura remains a rare phenomenon in which a petechial or purpuric rash develops acutely after intense sun exposure. We prefer the term *sunburn purpura* because it reflects the acuity of the phenomenon, as opposed to the previous labels *solar purpura* or *photolocalized purpura*, which also could suggest causality from chronic sun exposure. It has been proposed that sunburn purpura is a finding associated with a number of conditions rather than a unique entity.¹ The following characteristics can be helpful in describing the development of sunburn purpura: delay following UV exposure, gross morphology, histologic findings, and possible associated medical conditions.¹ Our case represents an important addition to the literature, as it differs from previously reported cases. Most importantly, the nonspecific biopsy findings and unremarkable laboratory findings associated with our case may represent primary or idiopathic sunburn purpura.

Previously reported cases of sunburn purpura have occurred in patients aged 10 to 66 years. It has been seen following UV exposure, vigorous exercise and high-dose aspirin, or concurrent fluoroquinolone therapy, or in the setting of erythropoietic protoporphyria, idiopathic thrombocytopenic purpura, or polymorphous light eruption.²⁻⁸ When performed, histology has revealed capillaritis, solar elastosis, perivascular infiltrate, lymphocytic perivascular infiltrate with dermal edema, or leukocytoclastic vasculitis.^{1,2,7-9} Our patient did not have a history of erythropoietic protoporphyria, polymorphous light eruption, or idiopathic thrombocytopenic purpura. She had not recently exercised, was not thrombocytopenic, and was not taking antiplatelet medications. She had no recent history of fluoroquinolone use. On histologic examination, our patient's biopsy demonstrated nonspecific petechial changes without signs of chronic UV exposure, dermal edema, vasculitis, lymphocytic infiltrate, or capillaritis.

Idiopathic sunburn purpura should only be diagnosed after other conditions are excluded. When evaluating a patient who presents with new-onset petechial rash following sun exposure, it is important to rule out vasculitis or thrombocytopenia as the cause, which is best achieved through skin biopsy and a platelet count, respectively. If there are no associated symptoms or thrombocytopenia and biopsy shows nonspecific vascular ectasia and erythrocyte extravasation, the physician should consider the diagnosis of idiopathic sunburn (solar or photolocalized)

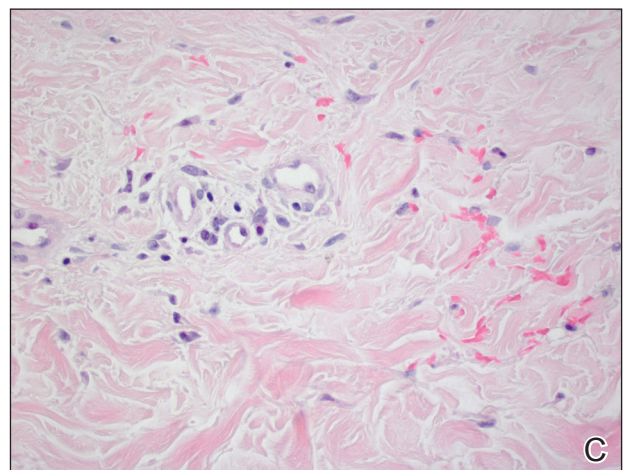
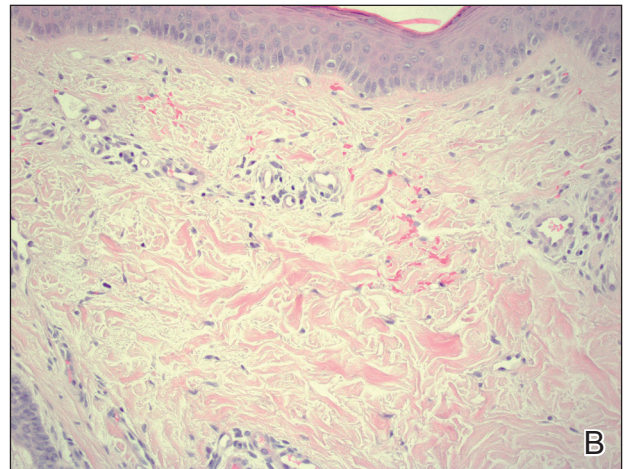
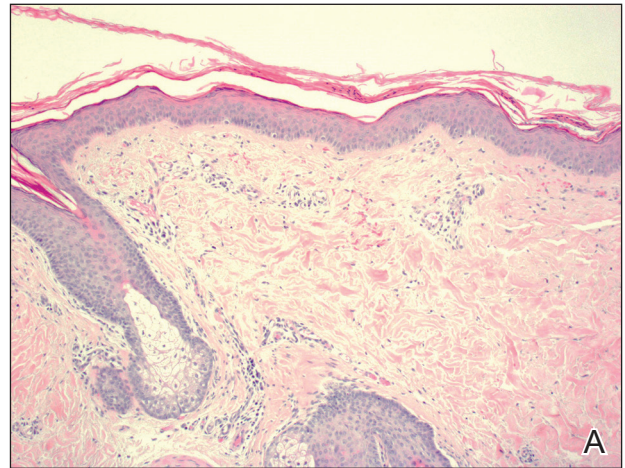


FIGURE 2. Idiopathic sunburn purpura skin biopsy demonstrated reactive epidermal changes with mild vascular ectasia and erythrocyte extravasation not associated with appreciable inflammation or evidence of vascular injury (A–C)(all H&E; original magnifications $\times 100$, $\times 200$, and $\times 400$, respectively).

purpura. Along with regular UV protection, the physician should advise that the rash typically resolves without treatment in 1 to 2 weeks.

REFERENCES

1. Waters AJ, Sandhu DR, Green CM, et al. Solar capillaritis as a cause of solar purpura. *Clin Exp Dermatol*. 2009;34:E821-E824.
2. Latenser BA, Hempstead RW. Exercise-associated solar purpura in an atypical location. *Cutis*. 1985;35:365-366.
3. Rubegni P, Feci L, Pellegrino M, et al. Photolocalized purpura during levofloxacin therapy. *Photodermatol Photoimmunol Photomed*. 2012;28:105-107.
4. Urbina F, Barrios M, Sudy E. Photolocalized purpura during ciprofloxacin therapy. *Photodermatol Photoimmunol Photomed*. 2006;22:111-112.
5. Torinuki W, Miura T. Erythropoietic protoporphyria showing solar purpura. *Dermatologica*. 1983;167:220-222.
6. Leung AK. Purpura associated with exposure to sunlight. *J R Soc Med*. 1986;79:423-424.
7. Kalivas J, Kalivas L. Solar purpura appearing in a patient with polymorphous light eruption. *Photodermatol Photoimmunol Photomed*. 1995;11:31-32.
8. Ros AM. Solar purpura—an unusual manifestation of polymorphous light eruption. *Photodermatol*. 1988;5:47-48.
9. Guarrera M, Parodi A, Rebora A. Solar purpura is not related to polymorphous light eruption. *Photodermatol*. 1989;6:293-294.