

Radial Shaft Stress Fracture in a Major League Pitcher

Karim A. Meijer, MD, Matthew S. Fury, MD, Hayley Ennis, MD, Luis Grau, MD, Michael Baraga, MD, Jean Jose, MS, DO, James R. Andrews, MD, and Lee Kaplan, MD

Abstract

Upper extremity injuries are associated with significant morbidity in throwing athletes, and prevention and diagnosis of overuse injuries in these athletes are increasingly being emphasized. Although stress fractures are common overuse injuries, stress fractures of the upper extremity are relatively rare. To our knowledge, a stress fracture of the radial shaft has not been reported in a throwing athlete. In this article, we describe the case of a Major League Baseball pitcher who presented with a stress fracture of the lateral cortex of the radius, likely caused by contractile forces of the supinator muscle, arising after his attempt to develop a new pitch.

In athletes, the incidence of stress fractures has been reported to be 1.4% to 4.4%.¹ Stress fractures of the upper extremity are less com-

mon and not as well described as lower extremity stress fractures. Although data is lacking, stress fractures involving the upper extremity appear to account for <6% of all stress fractures.² Stress fractures of the upper extremity, though rare, are being recognized more often in overhead athletes.³⁻⁶ In baseball pitchers, stress fractures most commonly occur in the olecranon but have also been found in the ribs, clavicle, humerus, and ulnar shaft.^{2,4,7-10} Stress fractures of the radius are a rare cause of forearm pain in athletes, and there are only a few case reports involving overhead athletes.^{4,11-15} To our knowledge, a stress fracture of the radial shaft has not been reported in a throwing athlete. Currently, there are no reports on stress fractures of the proximal radial shaft.¹⁶⁻¹⁸

In this article, we report the case of a radial shaft stress fracture that was causing forearm pain in a Major League Baseball (MLB) pitcher. We also discuss the etiology, diagnosis, and management of stress fractures of the upper extremity of overhead throwing athletes. The patient provided written informed consent for print and electronic publication of this case report.

Case Report

A 28-year-old right-hand-dominant MLB pitcher presented to the clinic with a 4-week history of right dorsal forearm pain that was refractory to a period of rest and physical therapy modalities. The pain radiated to the wrist and along the dorsal forearm. The pain started after the man attempted to develop a new pitch that required a significant amount of supination. The pain prevented him from pitching competitively. Indomethacin, diclofenac sodium topical gel, and methylprednisolone (Medrol Dosepak) reduced his symptoms only slightly.

Physical examination of the right elbow showed mild range of motion deficits; about 5° of exten-

Take-Home Points

- Stress fractures should always be considered when dealing with overuse injuries.
- Radial shaft stress fractures in overhead throwing athletes are rare.
- Stress fractures can occur anywhere increased muscular forces exceed the bone's ability to remodel.
- Proper imaging is necessary to make the diagnosis of a stress fracture.
- Nonoperative management of radial shaft stress fractures is an effective treatment.

Authors' Disclosure Statement: The authors report no actual or potential conflict of interest in relation to this article.

sion and 5° of flexion were lacking. The patient had full pronation and supination. Palpation of the dorsal aspect of the forearm revealed marked tenderness in the area of the proximal radius. There was no tenderness over the posterior olecranon or the ulnar collateral ligament, and a moving valgus stress test was negative. No pain was elicited by resisted extension of the wrist or fingers. Motor innervation from the posterior interosseous nerve, anterior interosseous nerve, and ulnar nerve was intact with 5/5 strength, and there were no sensory deficits in the distribution of the radial, median, or ulnar nerves.

Initial elbow radiographs and elbow magnetic resonance imaging (MRI) were negative. Repeat radiographs taken about 4 weeks after symptom onset showed a very subtle cortical lesion on the lateral and volar cortex of the radius (**Figures 1A, 1B**). A new MRI, ordered to evaluate the entire forearm, confirmed the presence of the cortical lesion and showed significant edema, periostitis, and myositis within the supinator muscle (**Figures 2A, 2B**). Computed tomography (CT) showed a linear lucent lesion of the proximal radial shaft, consistent with a stress fracture near the insertion of the supinator muscle (**Figures 3A-3D**). Four weeks later, follow-up CT showed evidence of interval fracture healing with decreased visibility of lucent lines. At 10-week follow-up, CT showed interval bridging callus formation, indicative of a healing stress fracture. The patient, who had no pain with activities of daily living, completed a progressive throwing regimen, advanced to live batting practice, and gradually worked back into competitive play. Total return-to-play time was 12 weeks. The patient remained pain-free and returned to an active MLB roster.

Discussion

Stress fractures account for 0.7% to 20% of sports medicine clinic injuries; <10% of all stress fractures involve the rib or upper extremity.^{4,6}

When the intensity or frequency of physical activity is increased, as with overuse, bone resorption

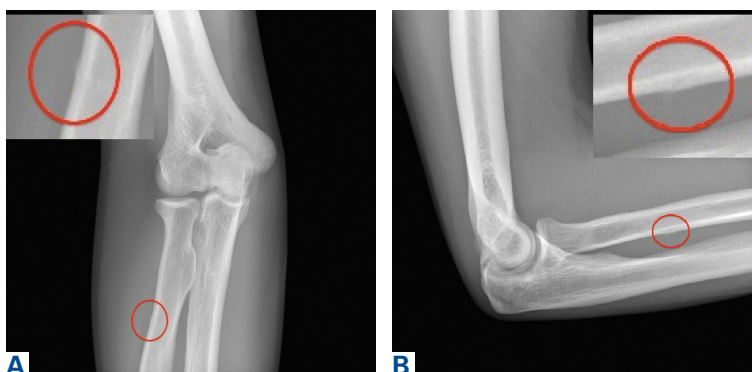

Figure 1. Red circle on (A) oblique and (B) lateral radiographs of the right elbow shows the location of the stress fracture.

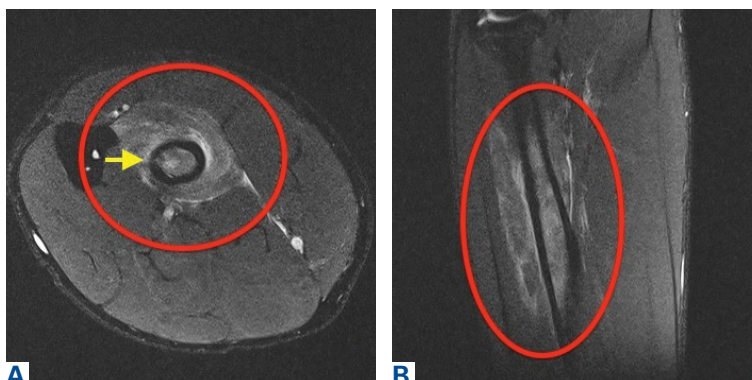


Figure 2. (A) Axial and (B) coronal T2-weighted magnetic resonance imaging of the right radius shows periosteal, cortical, and marrow edema. Reactive myositis surrounds the fracture (yellow arrow).

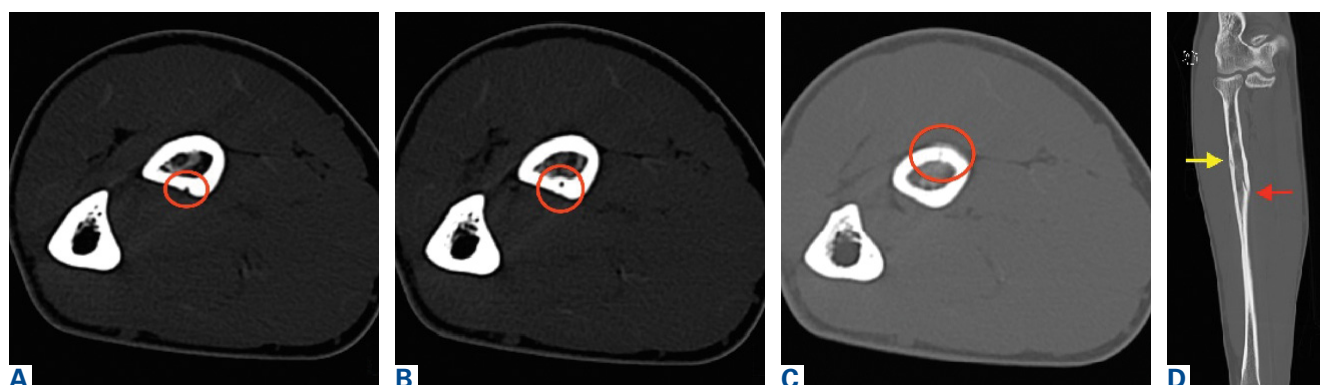


Figure 3. Axial computed tomography shows nutrient vessel and lesion through the cortex of the radius: (A) nutrient vessel enters the radius at the 6 o'clock position, (B) nutrient vessel within the cortical bone at the 6 o'clock position, and (C) stress fracture with periostitis at the 12 o'clock position. (D) Coronal computed tomography shows the cortical fracture (yellow arrow) and the nutrient vessel (red arrow).

surpasses bone production, locally weakening the bone and making it prone to mechanical failure. Failure is thought to be induced by a combination of contractile muscular forces across damaged bone and increased mechanical loading caused by fatigue of supporting structures.^{5,6,19} These forces may have contributed to our baseball pitcher's development of a stress fracture near the insertion of the supinator muscle in his throwing arm.

Given the insidious nature of stress fractures, the evaluating physician must have a high index of suspicion. Early recognition of a stress fracture is important in preventing further injury and allowing for early intervention, which is associated with faster healing.^{6,20} The clinical history often involves a change in training regimen within the weeks before pain onset. Furthermore, understanding the type of pitches used and the mechanics of each pitch can help with diagnosis. Often, pain increases as the inciting activity continues, and relief comes with rest. In an upper extremity examination, it is important to recall the usual stress fracture locations in throwers—the ribs, clavicle, humerus, ulnar shaft, and most often the olecranon—though the patient's history often narrows the anatomical region of suspicion.^{2,4,7-10} Examination begins with inspection of the skin and soft tissues. Range of motion and strength testing results likely are normal throughout the upper extremity.³ Palpation over the suspected injury location often elicits pain and indicates further imaging is needed.⁶ The tuning fork test or the 3-point fulcrum test may elicit symptoms in occult fractures.³ Completing the assessment is a thorough neurovascular examination.

Insidious forearm pain requires a broad differential, including flexor-pronator mass or distal biceps injury, chronic exertional compartment syndrome, radial tunnel syndrome, intersection syndrome, pronator teres syndrome, anterior interosseous syndrome, thoracic outlet syndrome, musculocutaneous nerve compression, deep vein thrombosis of ulnar vein, and periostitis. Stress fractures distal to the elbow more commonly occur in weight-bearing athletes, though as this case shows it is important to consider stress fractures of the radius and ulna when evaluating forearm pain in a throwing athlete.²¹

The first imaging examination for a suspected stress fracture is a radiograph, which can be normal in up to 90% of patients, as it initially was in our athlete's case.²² Often, radiographic evidence takes 2 to 12 weeks to appear.⁵ Even then, radiographs may be positive in only 50% of cas-

es.¹⁹ CT, often regarded as insensitive during the early stages, is useful in visualizing fracture lines in a suspicious location.^{19,22} Radionuclide uptake scanning is highly sensitive during the early stages of stress injury but is nonspecific and may indicate neoplasm or infection; in addition, up to 46% of abnormal foci are asymptomatic.¹⁹ MRI has sensitivity comparable to that of radionuclide scanning but also many advantages, including lack of ionizing radiation, improved spatial resolution, and ability to image bone and soft tissue simultaneously.¹⁹ In our patient's case, the unusual stress fracture location potentially could have hindered identification of the cause of injury. The lesion was just distal to the field of view of a normal elbow MRI and was not detected until a dedicated forearm MRI was examined. Both MRI and CT helped in identifying the stress fracture, and CT was used to follow interval healing.

In baseball players, upper extremity stress fractures are often nonoperatively treated with throwing cessation for 4 to 6 weeks followed by participation in a structured rehabilitation program.^{4,5} The throwing program that we suggest, and that was used in this case, has 21 stages of progression in duration, distance, and velocity of throwing. The athlete advances from each stage on the basis of symptoms.²³ Other issues that may be addressed are vitamin D and calcium status and any flawed throwing mechanics that may have predisposed the athlete to injury. Such mechanics are gradually corrected.

The literature suggests that appropriate nonoperative management of stress fractures allows for return to sport in 8 to 10 weeks. It is important to note that most of the literature on stress fractures involves the lower extremity, and that treatment and time to return to play are therefore better described for such fractures.⁶ More study and evaluation of upper extremity stress fractures are needed to make return-to-sport predictions more reliable and successful treatment modalities more unified for this patient population. Last, it is imperative that clinical examination and symptoms be correlated with serial imaging when deciding on return to play. Our patient took 12 weeks to return to high-level sport. He progressed pain-free through the throwing program and showed radiographic evidence of healing on follow-up CT.

Conclusion

Radial shaft stress fractures are rare in throwing athletes. However, with a thorough history, a

physical examination, and appropriate imaging, the correct diagnosis can be made early on, and proper treatment can be started to facilitate return to sport. To our knowledge, this is the first report of a stress fracture in the radial shaft of a MLB pitcher. Although the radial shaft is an uncommon location for stress fractures, we should keep in mind that they can occur wherever increased muscular forces exceed the ability of native bone to remodel. After diagnosis, the fracture usually heals with nonoperative treatment, and healing is confirmed with follow-up imaging, as was done in our patient's case. Improved prediction of time to return to play for upper extremity fractures, such as the radial stress fracture described in this article, requires more study.

Dr. Meijer is a Sports Medicine Orthopaedic Surgeon, Texas Sports Medicine Orthopaedic Group, Dallas, Texas. Dr. Fury is a Resident in Orthopaedic Surgery, Harvard Combined Orthopaedic Residency Program, Boston, Massachusetts. Dr. Ennis and Dr. Grau are Orthopedic Residents, Dr. Baraga is an Attending Physician and a Professor, and Dr. Jose is Director of Sports Imaging, University of Miami Health System, Miami, Florida. Dr. Andrews is Chairman and Director, Andrews Research and Education Foundation, Gulf Breeze, Florida. Dr. Kaplan is Chief, Division of Sports Medicine, University of Miami Health System, Miami, Florida.

Address correspondence to: Karim A. Meijer, MD, Texas Sports Medicine & Orthopaedic Group, 6901 Snider Plaza, Ste 200, Dallas, TX 75205 (tel, 512-663-4537; email, Karim.Meijer@gmail.com).

Am J Orthop. 2017;46(5):E326-E329. Copyright Frontline Medical Communications Inc. 2017. All rights reserved.

References

- Monteleone GP Jr. Stress fractures in the athlete. *Orthop Clin North Am.* 1995;26(3):423-432.
- Iwamoto J, Takeda T. Stress fractures in athletes: review of 196 cases. *J Orthop Sci.* 2003;8(3):273-278.
- Miller TL, Kaeding CC. Upper-extremity stress fractures: distribution and causative activities in 70 patients. *Orthopedics.* 2012;35(9):789-793.
- Jones GL. Upper extremity stress fractures. *Clin Sports Med.* 2006;25(1):159-174.
- Brooks AA. Stress fractures of the upper extremity. *Clin Sports Med.* 2001;20(3):613-620.
- Fredericson M, Jennings F, Beaulieu C, Matheson GO. Stress fractures in athletes. *Top Magn Reson Imaging.* 2006;17(5):309-325.
- Gurtler R, Pavlov H, Torg JS. Stress fracture of the ipsilateral first rib in a pitcher. *Am J Sports Med.* 1985;13(4):277-279.
- Polu KR, Schenck RC Jr, Wirth MA, Greeson J, Cone RO 3rd, Rockwood CA Jr. Stress fracture of the humerus in a collegiate baseball pitcher. A case report. *Am J Sports Med.* 1999;27(6):813-816.
- Wu C, Chen Y. Stress fracture of the clavicle in a professional baseball player. *J Shoulder Elbow Surg.* 1998;7(2):164-167.
- Schickendanz MS, Ho CP, Koh J. Stress injury of the proximal ulna in professional baseball players. *Am J Sports Med.* 2002;30(5):737-741.
- Loosli AR, Leslie M. Stress fractures of the distal radius. A case report. *Am J Sports Med.* 1991;19(5):523-524.
- Inagaki H, Inoue G. Stress fracture of the scaphoid combined with the distal radial epiphysiolysis. *Br J Sports Med.* 1997;31(3):256-257.
- Read MT. Stress fractures of the distal radius in adolescent gymnasts. *Br J Sports Med.* 1981;15(4):272-276.
- Orloff AS, Resnick D. Fatigue fracture of the distal part of the radius in a pool player. *Injury.* 1986;17(6):418-419.
- Eisenberg D, Kirchner SG, Green NE. Stress fracture of the distal radius caused by "wheelies." *South Med J.* 1986;79(7):918-919.
- Brukner P. Stress fractures of the upper limb. *Sports Med.* 1998;26(6):415-424.
- Farquharson-Roberts MA, Fulford PC. Stress fracture of the radius. *J Bone Joint Surg Br.* 1980;62(2):194-195.
- Orloff AS, Resnick D. Fatigue fracture of the distal part of the radius in a pool player. *Injury.* 1986;17(6):418-419.
- Anderson MW. Imaging of upper extremity stress fractures in the athlete. *Clin Sports Med.* 2006;25(3):489-504.
- Bennell K, Brukner P. Preventing and managing stress fractures in athletes. *Phys Ther Sport.* 2005;6(4):171-180.
- Sinha AK, Kaeding CC, Wadley GM. Upper extremity stress fractures in athletes: clinical features of 44 cases. *Clin J Sport Med.* 1999;9(4):199-202.
- Matheson GO, Clement DB, McKenzie DC, Taunton JE, Lloyd-Smith DR, MacIntyre JG. Stress fractures in athletes. A study of 320 cases. *Am J Sports Med.* 1987;15(1):46-58.
- Kaplan L, Lesniak B, Baraga M, et al. Throwing program for baseball players. 2009. http://uhealthsportsmedicine.com/documents/UHealth_Throwing_Program.pdf. Accessed May 24, 2016.