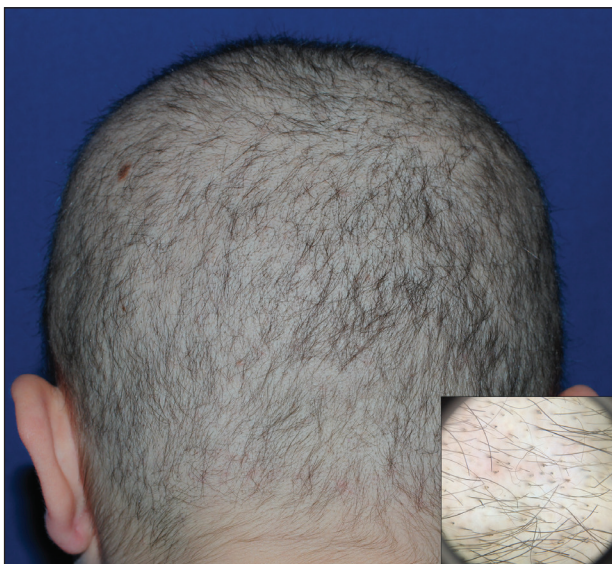

Diffuse Nonscarring Alopecia

Laura A. Greyling, MD; Samantha E. Lee, MD; Jake E. Turrentine, MD



A 19-year-old woman with attention deficit hyperactivity disorder and an anxiety disorder presented with hair loss of 2 years' duration. She initially had small circular bald areas throughout the scalp that had progressed to diffuse hair loss of the entire scalp. She denied recent hairpulling but admitted to a remote prior history of eyelash and eyebrow pulling. She denied any voice changes, acne, or menstrual irregularities. Physical examination revealed short hairs of varying lengths throughout the scalp with no loss of follicles, erythema, scale, or exclamation point hairs. Eyebrows and eyelashes were normal. A hair-pull test was negative. Trichoscopy illuminated variation in hair shaft diameters, as well as short, irregularly broken hairs of different lengths (inset).

WHAT'S THE DIAGNOSIS?

- a. androgenetic alopecia
- b. diffuse alopecia areata
- c. syphilitic alopecia
- d. telogen effluvium
- e. trichotillomania

PLEASE TURN TO **PAGE E5** FOR THE DIAGNOSIS

Dr. Greyling is in private practice at Water's Edge Dermatology, Jupiter, Florida. Drs. Lee and Turrentine were from the Medical College of Georgia, Augusta University. Dr. Lee currently is from Vanderbilt University, Nashville, Tennessee. Dr. Turrentine currently is in private practice, Hickory, North Carolina.

The authors report no conflict of interest.

Correspondence: Laura A. Greyling, MD, Water's Edge Dermatology, 1096 W Indiantown Rd, Jupiter, FL 33458 (lthornsberry@gmail.com).

THE DIAGNOSIS: Trichotillomania

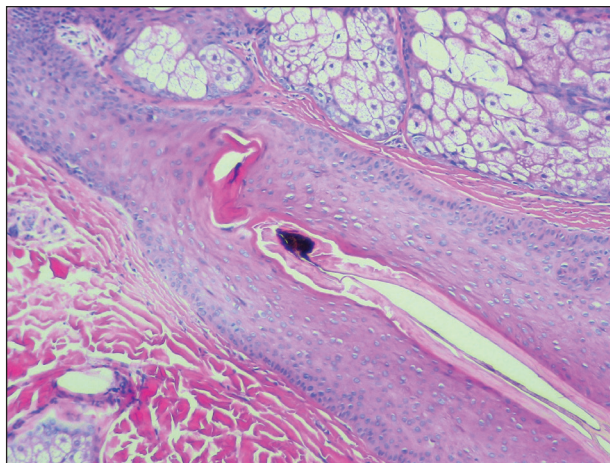
A scalp punch biopsy revealed pigmented hair casts, an increase in catagen and telogen follicles, and a lack of perifollicular inflammation (Figure). Based on the clinical and histopathological findings, a diagnosis of trichotillomania (TTM) was established.

Trichotillomania is a hairpulling disorder with notable dermatologic and psychiatric overlap. Although previously considered an impulse control disorder, the *Diagnostic and Statistical Manual of Mental Disorders* (Fifth Edition) reclassified it within obsessive-compulsive and related disorders, which also include body dysmorphic disorder and excoriation (skin-picking) disorder. Diagnostic criteria for TTM include the following: the patient must have recurrent pulling out of his/her hair resulting in hair loss despite repeated attempts to stop; underlying medical conditions and other psychiatric diagnoses must be excluded; and the patient must experience distress or impairment in social, occupational, or other areas of functioning from the hairpulling.¹ Trichotillomania mainly occurs in children and young adults, with a lifetime prevalence of approximately 1% to 2%.² The coexistence of a mood or anxiety disorder is common, as seen in our patient.

The diagnosis of TTM requires strong clinical suspicion because patients and their parents/guardians usually deny hairpulling. The main clinical differential diagnosis often is alopecia areata (AA) because both conditions can present as well-defined patches of nonscarring hair loss. Trichoscopy provides an invaluable noninvasive diagnostic tool that can be particularly useful in pediatric patients who may be reluctant to have a scalp biopsy. There are many overlapping trichoscopic findings of TTM and AA, including yellow dots, black dots, broken hairs, coiled hairs, and exclamation mark hairs.³ More specific trichoscopy findings for TTM include flame hairs (wavy proximal hair residue), V-sign (2 shafts within 1 follicle broken at the same length), and tulip hairs (dark, tulip-shaped ends of broken hairs).⁴ Hair breakage of varying lengths and trichoptilosis (split ends) can be better visualized using trichoscopy and support a diagnosis of TTM over AA.

Androgenetic alopecia (female pattern hair loss) presents with gradual thinning around the part line of the frontal and parietal scalp with trichoscopy showing miniaturization of hairs and decreased follicle density. The moth-eaten-like appearance of alopecia due to secondary syphilis may mimic alopecia areata clinically, but serologic testing can confirm the diagnosis of syphilis. Telogen effluvium does not have the trichoscopic features that are seen in TTM and is clinically distinguished by hair shedding and a positive hair pull test.

Biopsy can provide objective yet nonspecific support for the diagnosis, demonstrating trichomalacia, pigmented



Trichotillomania histopathology revealed pigmented hair casts without perifollicular inflammation (H&E, original magnification $\times 100$).

hair casts, empty follicles, and an increase in catagen hairs with a lack of inflammation. Normal and damaged hair follicles may be seen in close proximity, and hemorrhage may be seen secondary to trauma. Pigmented hair casts are not specific to TTM and are present in other traumatic hair disorders, such as traction alopecia; therefore, clinical correlation is essential for diagnosis.

Habit reversal training is the most effective treatment of TTM and involves 3 major components: awareness training with self-monitoring, stimulus control, and competing response procedures.⁵ Although numerous pharmacotherapies have been reported as effective treatments for TTM, a 2013 Cochrane review of 8 randomized controlled trials concluded that no medication has demonstrated reliable efficacy. Reported therapies included selective serotonin reuptake inhibitors, naltrexone, olanzapine, *N*-acetylcysteine, and clomipramine.⁶

REFERENCES

1. American Psychiatric Association. *Diagnostic and Statistical Manual of Mental Disorders*. 5th ed. Washington, DC: American Psychiatric Association; 2013.
2. Schumer MC, Panza KE, Mulqueen JM, et al. Long-term outcome in pediatric trichotillomania. *Depress Anxiety*. 2015;32:737-743.
3. Lencastre A, Tosti A. Role of trichoscopy on children's scalp and hair disorders. *Pediatr Dermatol*. 2013;30:674-682.
4. Rakowska A, Slowinska M, Olszewska M, et al. New trichoscopy findings in trichotillomania: flame hairs, V-sign, hook hairs, hair powder, tulip hairs. *Acta Derm Venereol*. 2014;94:303-306.
5. Morris S, Zickgraf H, Dingfelder H, et al. Habit reversal training in trichotillomania: guide for the clinician. *Expert Rev Neurother*. 2013;13:1069-1177.
6. Rothbart R, Amos T, Siegfried N, et al. Pharmacotherapy for trichotillomania. *Cochrane Database Syst Rev*. 2013;11:CD007662.