



George E. Eldayrie, MD; Kristy Smith, MD; Michael Seth Smith, MD, CAQSM, PharmD

Department of Community Health and Family Medicine (Drs. Eldayrie and K. Smith) and Department of Orthopedics and Rehabilitation (Dr. MS Smith), University of Florida, Gainesville

smithms@ortho.ufl.edu

The authors reported no potential conflict of interest relevant to this article.

Adult foot fractures: A guide

This review can help you refine your approach to the diagnosis and management of adult foot fractures, while offering guidance on when to pursue advanced imaging.

PRACTICE RECOMMENDATIONS

› *Manage most fractures of the proximal fifth metatarsal metaphyseal-diaphyseal junction (Jones fracture) conservatively with appropriate treatment and close follow-up; refer for early surgical evaluation only those patients who are highly active and who are interested in a faster return to activity.* **(B)**

› *Use the Ottawa Ankle and Foot Rules to determine whether x-rays are needed in a patient with foot pain and a suspected fracture.* **(A)**

› *Start with weight-bearing x-rays and then consider computed tomography or magnetic resonance imaging for complete evaluation of suspected injury to the Lisfranc joint.* **(C)**

Strength of recommendation (SOR)

- (A)** Good-quality patient-oriented evidence
- (B)** Inconsistent or limited-quality patient-oriented evidence
- (C)** Consensus, usual practice, opinion, disease-oriented evidence, case series

The evaluation and management of acute musculoskeletal conditions are frequently handled by primary care providers.¹ It's estimated that up to 14% of orthopedic complaints encountered by family physicians involve fractures,² and approximately 15% of these are foot fractures.² Diagnosis requires radiographic evaluation, but ultrasound is proving useful, too. This article reviews the diagnosis and management of adult foot fractures, with an emphasis on when advanced imaging and referral are indicated (TABLE^{1,3-10}).

Phalanx fractures: The most common foot fractures

Phalanx fractures typically occur by crush injury, hyperextension, or direct axial force (eg, stubbing the toe).³ Patients with phalanx fractures typically present with pain at or near the site of injury, edema, ecchymosis, and erythema. Throbbing pain is characteristic, and dependent position may worsen the pain.¹ Emergently evaluate any fracture causing tenting of the skin, protrusion from the skin, or neurovascular compromise, and attempt realignment to regain neurovascular function.

Most patients with phalanx fractures have point tenderness over the site of the fracture; however, this may also occur with contusions. Placing a gentle loading force along the long axis of the bone distal to the injury may help you differentiate between a contusion and a fracture.⁴ Pain observed with axial loading of the bone during examination points to a fracture rather than a contusion.

Differential diagnosis

Obtain imaging, including anterior-posterior (AP), lateral, and oblique views at a minimum, for all patients in whom you suspect fractures.⁵ Multiple fractures of the phalanges are common; therefore, always thoroughly examine the phalanges adjacent to the injured one.

Sesamoid bone fractures are uncommon but do occur and are usually due to direct injury from jumping or landing. The

TABLE

Foot fractures: How to manage, when to refer

Fracture type	Mechanism of injury	Radiology	Treatment	Follow-up	Indications for surgical referral
Great toe fractures	Crush, axial force, hyperextension ^{1,3,4}	Three-view foot/toe (AP, lateral, and oblique) ^{1,3,5}	Short leg walking boot for 2-3 wks, then rigid shoe for 3-4 wks ^{1,3,4}	1 wk with repeat imaging. Every 2-4 weeks if fracture is intra-articular or requires reduction ^{1,3,4}	Fractures involving >25% of joint space, open fractures, fracture dislocations, neurovascular compromise ^{1,3,4}
Second to fifth phalanx fractures	Crush, axial force, hyperextension ^{1,3}	Three-view foot/toe (AP, lateral, and oblique) ^{1,3,5}	Buddy taping and rigid-soled shoes for 4-6 wks ^{1,3}	1-2 wks with repeat imaging if intra-articular or required reduction. Then every 2-4 wks ^{1,3}	Angulation >25° in dorsoplantar plane, >10° in mediolateral plane, rotation >20°, fractures involving >25% of joint space, open fractures, fracture dislocations, neurovascular compromise ^{1,3}
Metatarsal shaft fractures	Direct crush, indirect rotation with forefoot flexed, and hindfoot or leg rotated ^{1,3}	Three-view foot (AP, lateral, and oblique). MRI if stress fracture suspected ^{1,3,5}	Posterior splint for 3-5 days to allow swelling to improve, NWB crutches. Then short leg walking cast/boot or hard sole shoe for 4-6 wks ^{1,3}	1 wk with repeat imaging and again at 4-6 wks ^{1,3}	First metatarsal: Open, displaced, angulated, or intra-articular fractures; fractures that cause neurovascular compromise. Lesser metatarsals: First metatarsal indications and multiple fractures, dorsoplantar displacement >3 mm, dorsoplantar angulation >10° ^{1,3}
Fifth metatarsal tuberosity avulsion fractures	Ankle inversion (commonly with lateral ankle sprain) ^{1,3}	Three-view foot (AP, lateral, and oblique) ^{1,3,5}	Weight bearing as tolerated, short leg walking boot/cast for 2 wks or hard sole shoe for 4-8 wks, progressive ROM ^{1,3}	Every 2-4 wks, repeat x-rays if continued pain ^{1,3}	Displaced fracture >3 mm, step-off >1 mm over the cuboid surface, or fracture involving >60% of metatarsal cuboid joint surface ^{1,3}
Fifth metatarsal Jones fractures	Direct crush, ankle inversion ¹	Three-view foot (AP, lateral, and oblique). MRI if stress fracture suspected ^{1,5}	Posterior splint and NWB for 3-5 days to allow swelling to improve, then short leg NWB cast for 6-8 wks. If evidence of healing, then progress to walking boot and weight bearing. If no evidence of healing, then continued cast for 4 additional wks ^{1,3}	1 wk with repeat imaging at cast placement after splinting, then at 6-8 wks ¹	Failure to achieve healing with 10-12 wks of nonsurgical management. Elite athletes or very active individuals may opt for surgical management, as this may shorten the treatment course ^{1,3}
Lisfranc injury	Axial load on plantar-flexed forefoot ¹	Three-view foot (AP, lateral, and oblique) first. Weight bearing comparison views. CT/MRI if highly suspect and normal plain films ^{1,5}	Nonsurgical management is recommended only for patients who are not surgical candidates. This includes immobilization in a short leg cast for 8 wks and NWB ¹	Referral to surgical specialists is strongly indicated. Repeat imaging can be decided by surgical specialist ¹	Majority of cases should be managed surgically, especially for those with any evidence of instability of the joint. Reserve nonsurgical treatment for patients who are not good surgical candidates due to pre-existing conditions or who are nonambulatory ¹

CONTINUED

TABLE

Foot fractures: How to manage, when to refer (*cont'd*)

Fracture type	Mechanism of injury	Radiology	Treatment	Follow-up	Indications for surgical referral
Cuboid fractures	High-velocity direct trauma, foot inversion with external rotation of the tibia, direct blow, or axial load on a plantar-flexed heel ¹	Three-view foot (AP, lateral, and oblique). Consider weight-bearing view if there is concern for Lisfranc ligament complex involvement ^{1,5}	Short leg walking cast/boot for 6 wks, then transition to rigid sole shoe for additional 6 wks. Stress fractures can be managed with NWB crutches for 2 weeks, then transition to walking boot, as tolerated ^{1,7}	There is no consensus on follow-up, but every 2-4 wks is appropriate. Consider repeating imaging at 6 wks if pain continues	Severe comminution, displacement, or fracture with concomitant dislocation. >2 mm step-off ^{1,7}
Cuneiform fractures	Direct impact, axial loading on dorsiflexed or plantar-flexed foot with rotational force, or severe rotation of the midfoot in a fixed foot ¹	Three-view foot (AP, lateral, and oblique). Consider weight-bearing view if there is concern for Lisfranc ligament complex involvement ^{1,5}	Short leg walking cast/boot for 6 wks, then rigid-sole shoe for additional 6 wks ^{1,6,8}	There is no consensus on follow-up, but every 2-4 wks is appropriate. Consider repeating imaging at 6 wks if pain continues	Severe comminution, displacement, or fracture with concomitant dislocation. >2 mm step-off ^{1,6,8}
Navicular fractures	Twisting force with foot in plantar flexion may cause avulsion fractures. Tuberosity fractures occur from eversion force. Body fractures occur from hyperextension, direct trauma, flexion with rotation ¹	Three-view foot (AP, lateral, and oblique). MRI if stress fracture is highly suspected despite normal plain films ^{1,5}	Dorsal avulsion fracture: Short leg walking cast/boot for 6-8 wks. Tuberosity fracture: Short leg walking cast/boot for 4-6 wks. Body fracture: Below-the-knee walking cast for 6-8 wks, then longitudinal arch support ^{1,9}	Repeat radiographs after 4-6 wks of immobilization. If nonunion at 6 wks, continue immobilization for 2-4 wks. For body fractures, repeat imaging at 6 wks and every 2-4 wks until union is seen ^{1,9}	Large displaced dorsal avulsion fractures involving >20% of talonavicular articular surface; tuberosity fractures with >1 cm displacement proximally; any displaced body fracture; after 10 wks of nonoperative treatment and evidence of nonunion ^{1,9}
Calcaneus fractures	Extra-articular fractures occur from falls from height and landing on the heel. Forceful abduction of the forefoot can cause compression of the anterior calcaneal surface ¹	Lateral, axial and dorsoplantar view ^{1,5}	Anterior, medial, or lateral process fractures: Short leg walking cast/boot for 4-6 wks. Tuberosity fractures: Short leg NWB cast with 5-10° equinus for 6-8 wks. Body: Active exercise ^{1,10}	After immobilization, repeat plain films to document healing at 4-6 wks for anterior, medial, or lateral process fractures, and after 6-8 weeks for tuberosity fractures. Then transition to formal physical therapy for foot and ankle ROM and strengthening ^{1,10}	Open fractures, intra-articular fractures, or subtalar fractures; fractures with significant displacement or chronic pain or nonunion after conservative treatment; significantly displaced fractures causing widening of the heel ^{1,10}

AP, anterior-posterior; CT, computed tomography; MRI, magnetic resonance imaging; NWB, non-weight bearing; ROM, range of motion.

most common sesamoid to be injured is the medial sesamoid of the great toe, although the lateral sesamoid can also be injured. Bipartite sesamoids can occur and may confuse the

examiner due to their similar appearance on x-rays to a sesamoid fracture.¹ These normal variants often appear smooth and are commonly bilateral as opposed to the jagged or

abrupt edges of a fracture. Stress fractures occur as well and are typically due to overuse-type injuries.

Other causes of pain similar to that experienced with phalanx fractures include soft tissue injuries to adjacent ligaments, tendons, and muscles. To help discern the cause of pain, evaluate nail beds for subungual hematomas, indicating injury to the nail bed causing bleeding and pressure under the nail. Obvious deformities of the toes or metatarsal-phalangeal joints signal the possibility of a fracture-dislocation. First metatarsophalangeal (MTP) sprain (“turf toe,” a condition common in athletes who hyperextend the toe, such as when pushing off from hard surfaces like turf) and gout can also present with acute pain in the first phalanx.

Treatment

Due to the role of the great toe in weight bearing and balance, great toe fractures are sometimes managed differently than fractures in Toes 2 through 5. Proper alignment and healing from a fracture in the first toe are critical to prevent future pain and other sequelae. Refer for orthopedic evaluation great toe fractures with displacement, angulation, rotational deformity, neurovascular compromise, >25% involvement of the joint space, or obvious dislocation.¹ If referral is not indicated, treat great toe fractures with a short leg walking cast/boot for 2 to 3 weeks followed by buddy taping and use of a hard-soled shoe for 3 to 4 weeks.¹

With regard to the lesser toes, refer patients with fracture-dislocations, displaced intra-articular fractures, and fractures that do not reduce easily. Nondisplaced fractures of the lesser toes do not require surgical referral.¹ These can be treated with splinting (buddy taping) and use of rigid-sole shoes for 4 to 6 weeks. Treatment duration depends largely on patient compliance; generally, continue treatment until point tenderness resolves.¹

Treatment of sesamoid fractures consists of resting the affected foot with a walking boot, hard-soled shoe, or “donut” pad under the sesamoid bone to help distribute weight on the foot when standing. Length of treatment is approximately 6 to 8 weeks for most fractures.¹ Consider surgical referral if non-operative management is unsuccessful.

Metatarsal fractures: Look for malalignment

Metatarsal fractures account for 5% of all foot fractures encountered in primary care.² These fractures typically occur as a result of falls, direct trauma, or rotational injuries (eg, ankle and foot sprains).¹ In athletes, the most common cause of these fractures is high rotational force. Patients typically present with pain over the injury site, swelling, bruising, and pain with weight bearing.

As part of your exam, look for malalignment, rotational deformities, and evidence of open fracture. Palpation at the site of the fracture may increase the pain; however, as is true with phalanx fractures, contusions may also cause significant tenderness upon palpation. Also assess range of motion—with special attention to signs of malrotation—and evaluate the adjacent metatarsals, as multiple bones, ligaments, or both are often involved.¹

Fifth metatarsal fractures are the most common in adults, likely because of decreased cortical thickness as compared with the other metatarsals.^{3,11} In addition, multiple soft tissue attachments connect at the proximal aspect of the fifth metatarsal. Classification of these types of metatarsal fractures is based on anatomic location.³ Jones fractures are one type of fracture at the proximal aspect of the fifth metatarsal that occur at the metaphyseal-diaphyseal junction specifically (FIGURE 1). Because this area receives its blood supply from small terminal vessels, fractures here have a high risk of non-union and, thus, should be top of mind in any patient with tenderness at the base of the fifth metatarsal.

MRI/ultrasound in addition to plain films?

Use the Ottawa Ankle and Foot Rules to determine the need for foot radiographs in the acute setting.¹² If indicated, imaging should include AP, lateral, and oblique views of the foot.⁵ Consider magnetic resonance imaging (MRI) if you suspect a stress fracture, which typically presents as an overuse injury in athletes.

Ultrasound may be effective for identifying metatarsal fractures, as well.¹³ Ultrasound can be used to visualize fractures of the long

➤ Ultrasound can be used to visualize fractures of the long bones and to identify displacement, angulation, and step-offs.

FIGURE 1
**Proximal fifth metatarsal
 Jones fracture**

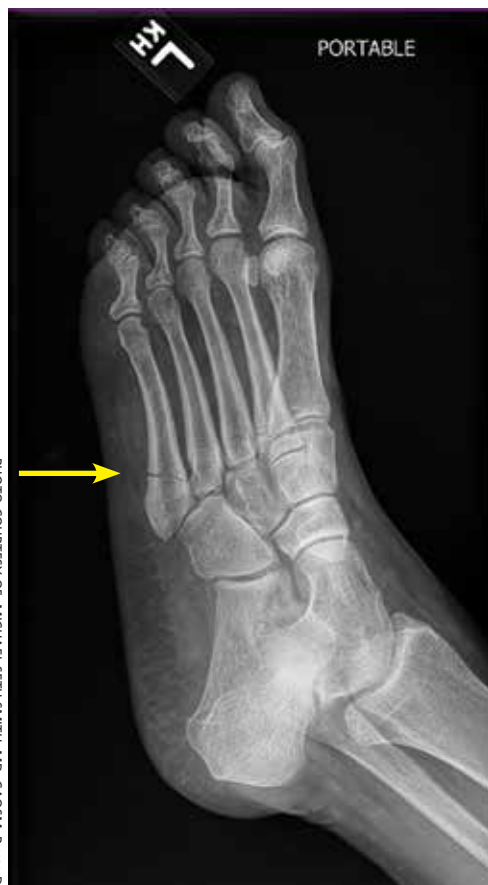

PHOTO COURTESY OF: MICHAEL SETH SMITH, MD, CAQSM, PHARMD

>
 Manage stress fractures and stress reactions of the proximal fifth metatarsal with strict activity modifications and a non-weight bearing short leg cast, given the high risk of nonunion.

metatarsal bones and identify displacement, angulation, and step-offs. Although its use in the United States has been limited for this purpose, studies in other countries are showing that it yields results comparable to plain films in the emergency department setting for diagnosis and initial management of these fractures.¹³

Differential diagnosis

Multiple other diagnoses present similarly to metatarsal fractures including: ligamentous/tendon/soft tissue injuries, interdigital neuroma, sesamoid fractures, and Lisfranc ligament injury (which we'll discuss in a bit). Stress fractures of the metatarsal, most commonly seen in the second metatarsal, are insidious in nature and are common with repetitive movement such as that made

by gymnasts, dancers, and track athletes.¹⁴ Metatarsalgia, which causes pain at the ball of the foot, is a condition that can stem from a myriad of causes including a low or high arch, biomechanics, and previous injury.

Treatment

Nondisplaced, minimally displaced (<3 mm), and minimally angulated (<10° dorsal/plantar angulation) fractures of any metatarsal shaft may be managed conservatively with a hard-soled shoe or walking boot with weight bearing as tolerated for 4 to 6 weeks.¹ Most stress fractures (excluding fifth metatarsal stress fractures) may be treated similarly. Surgical referral is indicated for patients with any open fracture, first metatarsal fractures with displacement, central metatarsal fractures with >10° deformity, >3 mm of translation, multiple fractures, or fifth metatarsal stress fracture.¹

Base of fifth metatarsal tuberosity avulsion fractures can be managed nonoperatively with protected weight bearing in a boot or cast for 2 weeks or hard sole shoe for 4 to 8 weeks if the fracture is at the proximal tubercle (see Zone I, **FIGURE 2**). Jones fractures (Zone II, **FIGURE 2**) or fractures of the proximal diaphysis (Zone III, **FIGURE 2**) of the fifth metatarsal may also be managed nonoperatively in patients who are not competitive athletes. This can be done with a non-weight bearing (NWB) short leg cast for 6 to 8 weeks at a minimum.⁴ If the patient is an athlete who wishes to resume competition, surgical referral is indicated, as the risk of nonunion is high with these fractures.¹⁵

Stress fractures and stress reactions (early evidence of bone edema seen on MRI, indicating progression to stress fracture) of the proximal fifth metatarsal should be managed with strict activity modifications and a NWB short leg cast for 6 to 8 weeks, given the high risk of nonunion.

Midfoot fractures: The cuboid, cuneiforms, and navicular bone

Although fractures are less common in the midfoot, the midfoot serves an important role in weight bearing and stabilization. In addition, along with the metatarsal bones, the

midfoot is critical to proper alignment and articulation.

Cuboid and cuneiform fractures

Cuboid fractures may occur with high-velocity trauma, foot inversion with external rotation of the tibia, a direct blow, or axial load on a plantar-flexed heel. Pain with weight bearing or with walking on toes is usually present. Cuneiform fractures are less common and rarely occur in isolation.⁶ Mechanisms of injury for cuneiform fractures include direct impact, axial loading on a dorsiflexed or plantar-flexed foot with rotational force, and severe rotation of the midfoot section in a fixed foot. Pain is usually localized to the dorsal or dorsomedial aspect of the foot.

With these 2 midfoot injuries, the exam should include palpation of the cuboid, navicular, and cuneiform bones and careful inspection of the Lisfranc joint, as this can be injured in midfoot fractures.⁷ Obtain AP, lateral, and oblique views of the foot,⁵ and strongly consider bilateral weight-bearing films to evaluate for tarsometatarsal (TMT) joint complex injuries (typically Lisfranc joint complex injuries), given their association with midfoot fractures¹ (FIGURE 3).

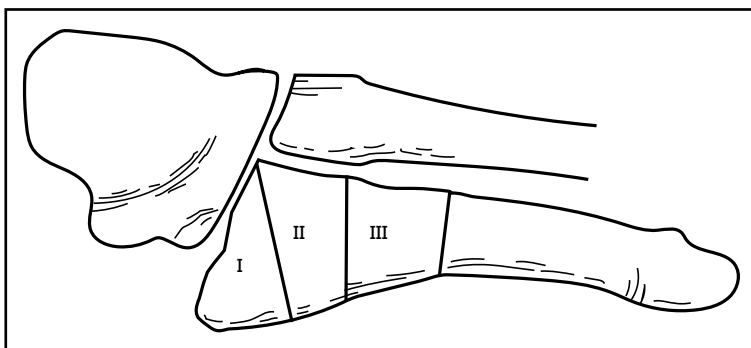
If the fracture is at or near the TMT joint complex, obtain a CT scan or MRI regardless of plain film findings to evaluate the Lisfranc joint complex. Because the Lisfranc joint is particularly important in midfoot stability, untreated injuries can lead to impaired gait or chronic foot pain and deformity. Early identification and surgical referral for these injuries is crucial.

Navicular fractures

Navicular fractures are typically caused by a twisting mechanism with forced plantar flexion or forced dorsiflexion of the midfoot. They present with severe pain over the dorsal or dorsomedial foot, particularly while bearing weight. Tenderness to palpation over the navicular bone generally warrants imaging studies to rule out fracture, as undiagnosed fractures can lead to severe long-term disability. Use Ottawa Ankle and Foot Rules¹² in the acute setting to determine the need for radiographs. If imaging is indicated, obtain AP, lateral, and oblique views.

FIGURE 2

Zones of the proximal fifth metatarsal



Zone I represents the area of avulsion fractures, denoted by a fracture proximal to the joint line of the fourth metatarsal and its interaction with the cuboid. Zone II is the site of a true Jones fracture, which is at high risk for nonunion. Zone III represents the area of diaphysis.

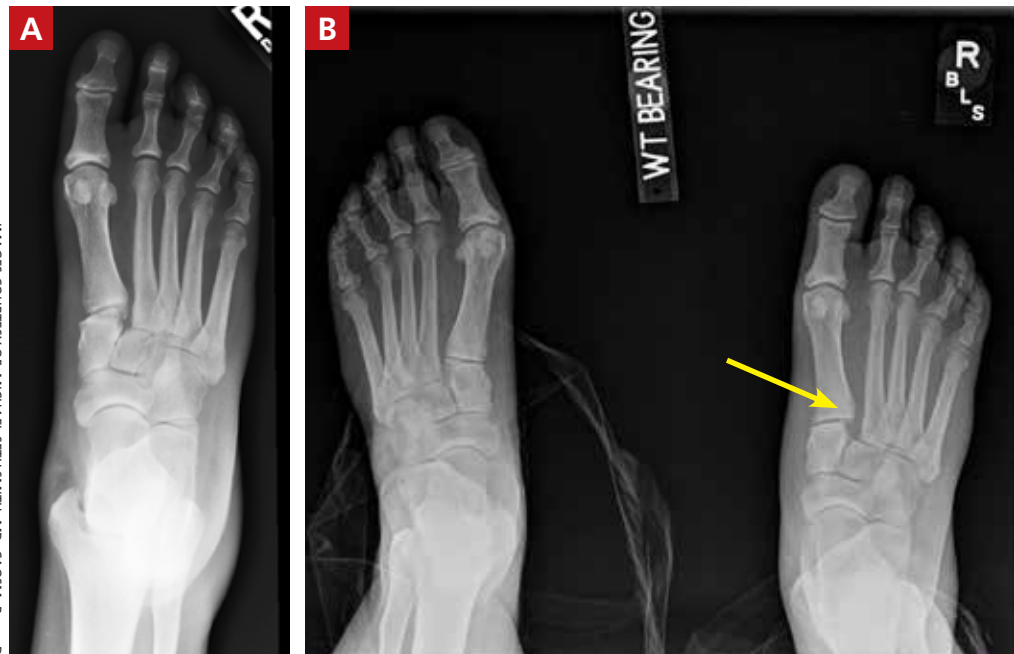
Tuberosity fractures may be seen on the AP view, while dorsal avulsions, talonavicular joint disruptions, and naviculo-cuneiform joint injuries are better seen on lateral views.¹⁶ Patients, particularly cross-country and track athletes, presenting with insidious onset of pain over the navicular bone should be evaluated for stress fracture using MRI, even in the presence of normal radiographs.

■ **Differential diagnosis.** Suspect Lisfranc joint complex injuries in any patient with mid-foot pain or fracture. The transverse arch of the foot is reliant upon the articulation of the second metatarsal with all 5 neighboring bones. The Lisfranc ligament is the strongest of 3 supporting ligaments to anchor the TMT joint complex. Other causes of mid-foot pain include soft tissue injury, contusion, and tendinopathy. In addition, other conditions that may cause pain in this area include cuboid syndrome, peroneal tendinopathy, Jones fracture, stress fracture, anterior calcaneal fracture, and sinus tarsi syndrome.

■ **Treatment.** Nondisplaced fractures of the cuboid or cuneiform may be treated with a short leg walking cast/boot for 6 weeks followed by the use of a shoe with a thin, rigid, longitudinal arch support for an additional 6 weeks.¹ Fractures requiring referral for surgical evaluation include fractures that are open and fractures with vascular or neurological compromise. Also refer comminuted

FIGURE 3

Non-weight bearing and weight bearing views of the right foot



A comparison of the non-weight bearing view of the right foot (A) and the weight bearing view of the same right foot (B; with left foot for comparison) shows the widening between the base of the first and second metatarsals at the Lisfranc joint (arrow), indicating a Lisfranc injury.

fractures and those that present with >2 mm step-off. Lastly, midfoot fractures that involve the Lisfranc joint should be immobilized and referred for orthopedic evaluation with instructions to the patient to avoid weight bearing until orthopedic evaluation.⁸

■ **Avulsion fractures** of the navicular bone may be managed nonoperatively with a short leg walking cast/boot if there is <20% involvement of the talonavicular surface. Simple nondisplaced body fractures may also be managed conservatively with immobilization and protected weight bearing for 6 to 8 weeks.¹⁵ Refer for surgical evaluation avulsion fractures that are intra-articular or dorsal involving 20% or more of the talonavicular surface and tuberosity fractures, given their risk of nonunion.⁹ All navicular body fractures that are not longitudinal in nature should also be referred for surgical evaluation. Navicular stress fractures that do not extend into the plantar cortex may be managed conservatively with a minimum of 6 weeks of a short leg cast and strict NWB with close follow-up.¹⁷

Calcaneal fractures

Calcaneal fractures typically occur from severe axial load or fall from a height. Weight bearing is usually limited and secondary to significant pain. Tenderness to palpation over the calcaneus or with squeezing of the heel will produce pain on exam. Initial x-rays should include a lateral and axial view of the calcaneus. Additional imaging, including a CT scan, may be indicated for further evaluation to determine the extent of the fracture or to determine if a fracture is present despite normal x-rays.¹⁰

Acute compartment syndrome occurs in 10% of calcaneal fractures and must be considered in patients with calcaneal fractures from severe trauma.¹⁸ Tendon injuries of the ankle, hindfoot, and midfoot may present similarly but can be ruled out with clinical exam and appropriate imaging.

Treatment

Avulsion fractures that do not involve more than 25% of the calcaneocuboid joint and nondisplaced calcaneal fractures may be

IMAGES COURTESY OF: MICHAEL SETH SMITH, MD, CAQSM, PHARMD

managed conservatively by instructing patients to wear a NWB short leg cast/boot for 4 to 6 weeks.¹ Refer for surgical evaluation patients with calcaneal fracture fragments >1 cm, displacement >3 mm, open fractures, joint involvement >25%, and those whose symptoms fail to resolve with conservative management. Stress fractures can be man-

aged conservatively with cessation of aggravating activities and immobilization in a walking boot until symptoms resolve, which typically takes 4 to 6 weeks.¹

JFP

CORRESPONDENCE

Michael Seth Smith, MD, CAQSM, PharmD, 3450 Hull Road, Gainesville, FL 32611; smithms@ortho.ufl.edu

References

- Eiff MP, Hatch RL, et al. *Fracture Management for Primary Care*. 3rd ed. Philadelphia, PA: Elsevier Saunders; 2012.
- Hatch RL, Rosenbaum CI. Fracture care by family physicians. A review of 295 cases. *J Fam Pract*. 1994;38:238-244.
- Bica D, Sprouse RA, Armen J. Diagnosis and management of common foot fractures. *Am Fam Physician*. 2016;93:183-191.
- Hatch RL, Hacking S. Evaluation and management of toe fractures. *Am Fam Physician*. 2003;68:2413-2418.
- Snider RK. *Essentials of Musculoskeletal Care*. 2nd ed. Rosemont, IL: American Orthopedic Surgeons; 2001.
- Guler F, Baz AB, Turan A, et al. Isolated medial cuneiform fractures: report of two cases and review of the literature. *Foot Ankle Spec*. 2011;4:306-309.
- Borrelli J, De S, Van Pelt M. Fracture of the cuboid. *J Am Acad Orthop Surg*. 2012;20:472.
- Pinney SJ, Sangeorzan BJ. Fractures of the tarsal bones. *Orthop Clin North Am*. 2001;32:21-33.
- Rosenbaum AJ, Uhl R, DiPreta JA. Acute fractures of the tarsal navicular. *Orthopedics*. 2014;37:541-546.
- Sanders RW, Clare MP. Calcaneous fractures. In: *Rockwood and Green's Fractures in Adults*. 7th ed. Philadelphia, PA: Lippincott Williams & Wilkins; 2010:2064.
- Singer G, Cichocki M, Schalamon J, et al. A study of metatarsal fractures in children. *J Bone Joint Surg Am*. 2008;90:772-776.
- Stiell IG, Greenberg GH, McKnight RD, et al. A study to develop clinical decision rules for the use of radiography in acute ankle injuries. *Ann Emerg Med*. 1992;21:384-390.
- Ekinci S, Polat O, Günalp M, et al. The accuracy of ultrasound evaluation in foot and ankle trauma. *Am J Emerg Med*. 2013;31:1551-1555.
- Welck MJ, Hayes T, Pastides P, et al. Stress fractures of the foot and ankle. *Injury*. 2017;48:1722-1726.
- Hatch RL, Alsobrook JA, Clugston JR. Diagnosis and management of metatarsal fractures. *Am Fam Physician*. 2007;76:817-826.
- Schildhauer TA, Coulibaly MO, Hoffman MF. Fractures and dislocations of the midfoot and forefoot. In: *Rockwood and Green's Fractures in Adults*. 8th ed. Philadelphia, PA: Lippincott Williams & Wilkins; 2015:2690.
- Mayer SW, Joyner PW, Almekinders LC, et al. Stress fractures of the foot and ankle in athletes. *Sports Health*. 2014;6:481-491.
- Kalsi R, Dempsey A, Bunney EB. Compartment syndrome of the foot after calcaneal fracture. *J Emerg Med*. 2012;43:e101-106.