

CASE IN POINT

GASTRIC FUNDIC POLYPS OR CYSTS?

Azam Ansari, MD and Ryan Devine, BS

As this case illustrates, microscopic examination of gastric fundic “polyps” often reveals cystic dilation.

Gastric fundic polyps (GFPs), as they're often called, are a common form of gastric lesions.¹ In a study of 612 Western European patients undergoing upper gastrointestinal endoscopy (UGIE), the prevalence of GFPs was reported to be 2%²—though this figure may be higher than that within the general population since the study cohort had indications for UGIE.

Until the late 1970s, all GFPs were considered precancerous, and radiologic diagnosis of multiple sporadic GFPs resulted in gastrectomy.³ In 1977, however, Elster and colleagues described the histologic character of a class of these so-called polyps as being that of noninflammatory cysts of varying

size (rarely more than 8 mm in diameter), located within the intact fundal glands.¹ The researchers theorized that these cysts showed no sign of becoming cancerous.

Over the years, Elster's theory has taken hold. Most GFPs have proven to be benign, to resolve spontaneously,⁴ and to be characterized histopathologically by cystic dilations of the fundic gland.⁵ Today, these GFPs sometimes are referred to as Elster glandular cysts (EGCs),³ and there is a tendency within medical literature to use the terms GFP and EGC loosely and interchangeably. This practice, however, is problematic: Cysts are not truly polyps. Differentiation between the two entities can be achieved only through histopathologic examination of a biopsy specimen.

Unfortunately, not all “polyps” are biopsied to determine whether they are actually cysts. Here, we present one patient's case in order to clarify the cystic nature of EGCs,

to promote their description in medical literature as gastric fundic cysts, and to emphasize further the importance of microscopic examination for diagnostic purposes.

INITIAL EXAM

A 66-year-old woman with recurrent attacks of reactive airway disease and ear, nose, and throat manifestations of gastroesophageal reflux disease (GERD) was noted upon endoscopic retroflexion during UGIE to have multiple lesions of variable sizes (3 to 9 mm) and shapes (pearl- or raindrop-like) located high in the gastric fundus (Figure 1).

The biopsy revealed extremely soft, collapsible lesions that resembled punctured balloons and could be peeled off with ease. Histopathologic examination showed prominent fundic glands with disordered architecture characterized by tortuosity, budding, and microcysts lined with fundic epithelium (Figure 2). Dysplasia was not pres-

Dr. Ansari is a gastroenterologist in the department of medicine at Fairview Southdale Hospital, Edina, MN. He also is a fellow of the American College of Gastroenterology. **Mr. Devine** is a student of osteopathic medicine at Philadelphia School of Osteopathic Medicine, Philadelphia, PA.

CASE IN POINT

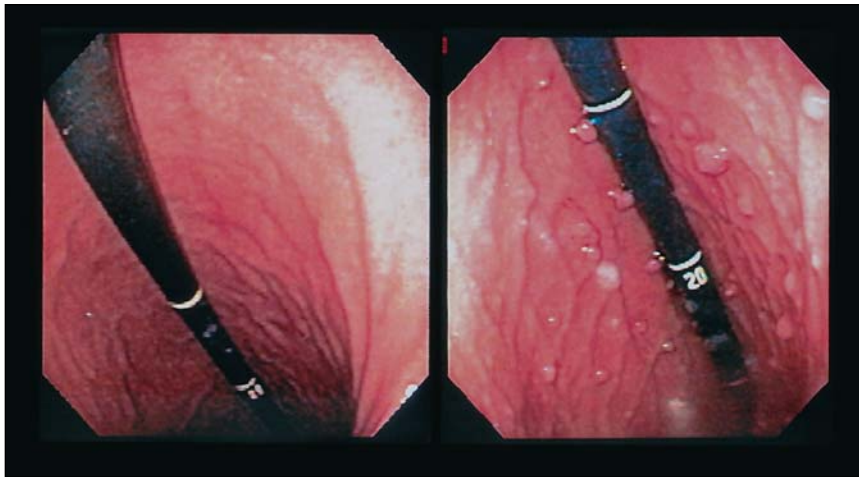


Figure 1. A normal gastric cardia and fundus on endoscopic retroflexion in a 65-year-old woman (left) and that of our 66-year-old patient (right), the latter of which shows scattered, multiple, 3- to 9-mm, pearl- or raindrop-like cysts.

ent and *Helicobacter pylori* organisms were not detected. The patient reported having taken no proton pump inhibitor in the past.

TREATMENT COURSE

The patient was advised to take ranitidine 150 mg once a day before dinner for three months and to consider complete colonoscopy to exclude familial adenomatous polyposis (FAPs), though her family history was negative.

The ensuing colonoscopy showed no polyps. In four to six weeks, the patient became asymptomatic of GERD. By virtue of a negative family history and normal colonoscopy excluding FAPs, she was diagnosed with the sporadic form of EGCs.

ABOUT THE CONDITION

Although EGCs can occur sporadically (typically, in middle-aged females), they are seen most commonly in association with FAPs.⁴ In fact, in 80% to 93% of FAP cases, there is also evidence of EGCs.³ For this reason, we concur with Gra-

ham who, in 1998, recommended ruling out FAPs anytime EGCs are detected (even if their occurrence appears to be sporadic).⁶

Traditionally, sporadic EGCs were considered nondysplastic, hamartomatous or hyperplastic lesions, possibly resulting from the progressive formation and unfold-

ing of secondary glandular buds.⁵ Recently, however, they have been shown to demonstrate genetic alteration involving beta-catenin mutations—the same mutations seen in FAPs—even in the absence of dysplastic morphology.⁷

Investigators using immunohistochemical study and monoclonal antibodies found that, in the paranuclear zone, EGCs express the sialyl-Tn epitope, a side-chain sugar normally masked in adult gastric mucin. This finding signifies an alteration in gastric mucin synthesis, correlates with the high proliferative index of EGCs as compared to the normal gastric fundic mucosa, and supports the hypothesis that EGCs are hyperproliferative in nature.⁸

Recently, two other contributing factors to the development of EGCs have been found: (1) the prolonged use of the proton pump inhibitor omeprazole in patients without *H. pylori* infection and (2) the acceleration of atrophic gastritis in the gastric fundus or body in patients with *H. pylori* infection.⁹

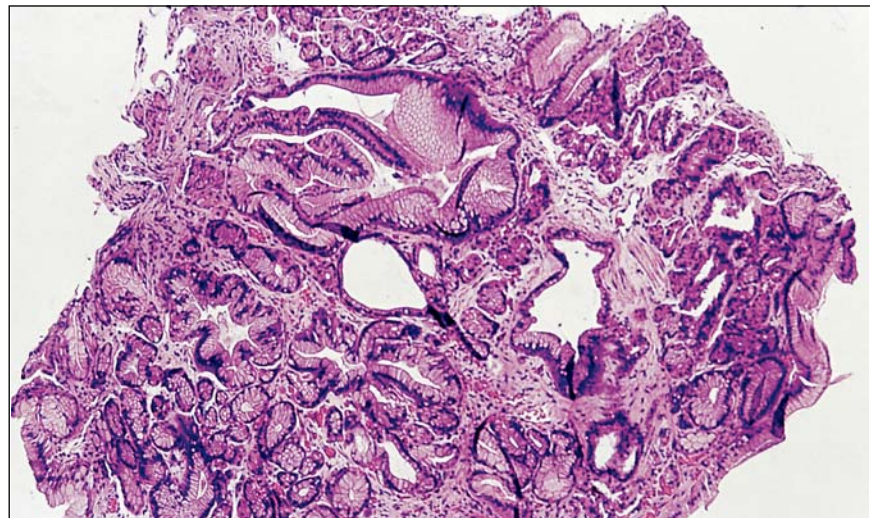


Figure 2. Histopathologic image (hematoxylin-eosin stain, magnified 10 times) of a fundic section that was removed from our 66-year-old patient and is characterized by dilation and tortuosity of the fundic glands and microcysts lined with fundic epithelium.

Continued on page 39

Continued from page 34

Encountered unexpectedly during UGIE, EGCs call to mind a wide range of possible diagnoses, including gastric carcinoids, gastric hamartomas, amyloidosis, lymphomatous polyposis, and chronic *H. pylori* gastritis—all of which can present similar endoscopic pictures. These conditions, however, are easily distinguishable from one another upon histopathologic examination. Furthermore, while it is possible to arrive at a provisional diagnosis based on appearance, size, and surrounding pathology, microscopic examination of the biopsy specimens is mandatory because the results of such examination determine subsequent management of the condition.

It would be misleading to describe the UGIE findings from the patient described here as gastric

fundic glandular polyps because microscopic examination actually revealed fundic glandular cysts. We recommend that a final diagnosis be made only after a histopathologic examination; visual assessment alone is insufficient. ●

The opinions expressed herein are those of the authors and do not necessarily reflect those of Federal Practitioner, Quadrant HealthCom Inc., the U.S. government, or any of its agencies. This article may discuss unlabeled or investigational use of certain drugs. Please review complete prescribing information for specific drugs or drug combinations—including indications, contraindications, warnings, and adverse effects—before administering pharmacologic therapy to patients.

REFERENCES

1. Elster K, Eidt H, Ottenjann R, Rosch W, Seifert E. The glandular cyst, a polypoid lesion of the gastric mucosa [in German]. *Dtsch Med Wochenschr.* 1977;102:183-187.
2. Dickey W, Kenny BD, McConnell JB. Prevalence of fundic gland polyps in a western European population. *J Clin Gastroenterol.* 1996;23:73-75.
3. Stolte M, Vieth M, Ebert MP. High-grade dysplasia in sporadic fundic gland polyps: Clinically relevant or not? *Eur J Gastroenterol Hepatol.* 2003;15:1153-1156.
4. Stolte M. Fundic gland polyps: A rare, innocuous, and reversible disturbance. *Gastroenterology.* 1993;150:1590-1591.
5. Lee RG, Burt RW. The histopathology of fundic gland polyps of the stomach. *Am J Clin Pathol.* 1986;86:498-503.
6. Graham JR. Gastric acne: Omeprazole-induced fundic gland polyposis. *Med J Aust.* 1998;168:93.
7. Declich P, Sironi M. Fundic gland polyps: An innocuous curiosity possibly with important pathological associations. *Hum Pathol.* 1997;28:1328-1329.
8. Declich P, Isimbaldi G, Sironi M, et al. Sporadic fundic gland polyps: An immunohistochemical study of their antigenic profile. *Pathol Res Pract.* 1996;192:808-815.
9. el-Zimaity HM, Jackson FW, Graham DY. Fundic gland polyps developing during omeprazole therapy. *Am J Gastroenterology.* 1997;92:1858-1860.