

# Clinical Safety and Efficacy in Photoaged Skin With CoffeeBerry Extract, a Natural Antioxidant

David H. McDaniel, MD

---

The effects of a skin care system containing CoffeeBerry extract (CBE) are explored in a series of studies designed to evaluate its effects on fine lines and wrinkles, pigmentation, and gene expression. A 6-week pilot study was designed to assess the effects of twice-daily application of CBE 1% cream and CBE 0.1% cleanser in a study group of 30 participants with moderate photoaging. Ten of these participants were involved in a split-face arm that compared CBE with its vehicle. Blinded expert grading of photographs measured the global improvement of facial skin and also percent improvement of fine lines and wrinkles and pigmentation. In addition to the photographic analysis and evaluation undergone by all participants, biopsies were taken and sectioned from 4 participants in the split-face protocol in order to evaluate changes in collagen I, collagen IV, matrix metalloproteinase (MMP)-1, and IL-1 $\beta$ . The remaining 20 participants applied CBE cleanser and day and night creams to the entire face. In addition to this clinical study, an in vitro study was designed to examine the gene expression of extracellular matrix and adhesion-related proteins in cultured human skin fibroblasts exposed to 0.001% CBE once or twice a day for 72 hours. In the split-face arm, the degree of improvement from baseline at week 6 was greater on the facial side receiving the CBE system when compared with vehicle: 29% versus 8% ( $P \leq .05$ ), 24% versus 3% ( $P \leq .05$ ), and 15% versus 5% ( $P = .055$ ) for global improvement, fine lines and wrinkles, and pigmentation, respectively. Biopsies showed the CBE system reduced MMP-1 and IL-1 $\beta$  relative to vehicle. In the full-face arm, global improvement and improvements in fine lines and wrinkles and pigmentation were observed at week 6 relative to baseline. The CBE creams were generally well tolerated. In the in vitro study, CBE up-regulated gene expression for 4 collagen structural proteins and down-regulated gene expression for 3 MMPs. CoffeeBerry extract appears to improve the appearance of photoaged skin and shows preliminary evidence of modulating aspects of the chemokine cascade involved in photoaging.

---

*Dr. McDaniel is Director, Institute of Anti-Aging Research, Virginia Beach; Codirector and Professor, School of Science, Hampton University Skin of Color Research Institute, Virginia; Assistant Professor, Clinical Dermatology and Plastic Surgery, Eastern Virginia Medical School, Norfolk; and Adjunct Assistant Professor, School of Biological Sciences, Old Dominion University Norfolk.*

*Dr. McDaniel is a paid consultant for, is on the medical advisory board of, and has received research grants from Allergan, Inc, and Stiefel Laboratories, Inc, and has also received research grants from Lifespan Extension, L'Oreal USA, and Pharma Cosmetix Research, LLC. This study was sponsored by Stiefel Laboratories, Inc.*

*Correspondence: David H. McDaniel, MD, 933 First Colonial Rd, Ste 113-114, Virginia Beach, VA, 23454.*

**A**ntioxidants have been shown to help reduce the signs of intrinsic (natural) aging of skin while restoring and protecting skin from extrinsic (environmental) aging. Natural antioxidants (applied topically or ingested) may reinforce the activity of the body's endogenous antioxidant defense systems, thus providing additional protection from oxidative stress.<sup>1</sup>

One natural antioxidant that has been studied extensively is green tea, which contains many polyphenols. Although epidemiologic and human studies have not yet generated conclusive results, basic scientific studies of green tea polyphenols indicate that they not only scavenge for reactive oxygen species and function as antioxidants in the epidermis, but also act as modulators of different gene groups and signal pathways.<sup>2</sup>

CoffeeBerry extract (CBE) is a natural antioxidant derived from the subripe fruit of the coffee plant (*Coffea arabica*) that demonstrates potential antiaging benefits for skin.<sup>3</sup> It is rich in polyphenol antioxidants, including chlorogenic acid, condensed proanthocyanidins, quinic acid, and ferulic acid. Compared with a control, significantly greater improvements have been observed with CBE in the mean score for texture, roughness, and a global photoaging assessment.<sup>4</sup>

A scientific basis for the potential effectiveness of CBE is provided by results of the oxygen radical absorbance capacity (ORAC) assay, which measures the antioxidant capacity of natural sources against reactive oxygen and nitrogen radicals. Specifically, the ORAC assay determines free radical scavenging activity against the peroxy radical for both water-soluble and lipid-soluble substances.

Previous studies have shown that the ORAC score for CBE (15,000  $\mu\text{mol}$  Trolox equivalents [TE]/g) was far greater than the scores for other commonly known natural antioxidants, including green tea (3000–5000  $\mu\text{mol}$  TE/g); pomegranate (3000  $\mu\text{mol}$  TE/g); and vitamin C, vitamin E, and ferulic acid (200  $\mu\text{mol}$  TE/g).

This article presents the results of the initial clinical evaluations of CBE, including an *in vitro* study and a study in humans. Because ideal antioxidant skin treatments penetrate the skin surface and reach a cellular level, affecting DNA, RNA regulation, and collagen production, an *in vitro* study was designed to examine the gene expression of extracellular matrix and adhesion-related proteins in cultured human skin fibroblasts exposed to 0.001% CBE once or twice daily for 72 hours.

In addition, a 6-week pilot study was designed to assess the effects of twice-daily application of CBE 1% cream and CBE 0.1% cleanser in a study group of 30 participants. Ten of these participants were involved in a split-face protocol that compared CBE with its vehicle.

Biopsies were taken and sectioned from 4 participants in the split-face protocol in order to evaluate changes in collagen I, collagen IV, matrix metalloproteinase (MMP)-1, and IL-1 $\beta$ .

## MATERIALS AND METHODS

### Full-Face and Split-Face Protocols

*Participant Population*—Thirty female participants with moderate photoaging were enrolled in this pilot study and randomly assigned to participate in the full-face protocol (n=20) or the split-face protocol (n=10). Specific inclusion and exclusion criteria are provided in Table 1. It should be noted that although there was no washout period, participants were required to discontinue the use of any antiaging compounds for the duration of the study.

*Study Medication, Treatment Regimen, and Concomitant Medications*—Full-face participants were given product labeled “A” (active product), and split-face participants were given products labeled “A” and “B” (vehicle). Split-face participants were further randomized into groups of 5 using product A on opposite sides of the face (5 on the left and 5 on the right) in order to minimize any possible bias from sun exposure. Participants were instructed to use a cleanser (CBE 0.1% or vehicle alone) and cream (CBE 1% or vehicle alone) combination twice daily, in the morning (day cream, also containing a sun protection factor of 15) and the evening (night cream), for 6 weeks. In the morning, participants were to apply a dime-sized amount of the cleanser to moistened hands, work it into a lather, and gently massage it onto the face. They were then to rinse the face thoroughly with lukewarm water and pat dry. After the face was completely dry, participants were to apply a nickel-sized amount of day cream to the hand and rub it thoroughly into the face and neck. If desired, colored cosmetics could be applied after the cream dried. Participants were to repeat the same process in the evening using the night cream.

Participants were prohibited from using any soap, facial cleanser, topical medications, or moisturizer on the face other than those provided for the study and were restricted from applying cosmetics prior to study visits. Participants were asked to avoid sunbathing, tanning beds, the use of sun lamps, and excessive exposure to UV light during the study.

*Study Evaluations*—Clinical evaluations were performed at the pretreatment visit (baseline) and at 3-week and 6-week study visits. All participants had the right, left, and full-face views photographed at each study visit using the Canfield VISIA-CR system according to the clinic's standard operating procedure and manufacturer

TABLE 1

## Inclusion and Exclusion Criteria for Study of CBE

Inclusion criteria	<p>Participants with moderate photoaging must be diagnosed by the investigator.</p> <p>Participants must be female and preferably older than 30 y with no known medical conditions that, in the investigator's opinion, may interfere with study participation.</p> <p>Participants must discontinue all current photoaging products.</p> <p>Participants must provide written informed consent and photography consent.</p>
Exclusion criteria	<p>Participants with any dermatological disorder or any personal appearance that, in the investigator's opinion, may interfere with the accurate evaluation of the participant's face.</p> <p>Participants who have demonstrated a previous hypersensitivity reaction to any ingredients in the study products.</p> <p>Participants receiving concurrent therapy with any medication, either topical or oral, that might interfere with the study.</p> <p>Participants who have undergone any surgical treatment to the tissues of the face.</p> <p>Participants who are not willing to discontinue any antiaging prescription or OTC cosmeceutical preparations to the face.</p> <p>Participants who have participated in another clinical trial or who have taken an experimental drug within the past 30 d.</p> <p>Participants who are pregnant, breast-feeding, or planning a pregnancy.</p> <p>Participants who are unwilling or unable to comply with the requirements of the protocol.</p>

Abbreviations: CBE, CoffeeBerry extract; OTC, over-the-counter.

instructions. Images selected from the VISIA-CR photography suite were color, parallel polarized, cross polarized, and UV reflective.

In addition, split-face participants had additional photographs taken at the pretreatment and 6-week study visits using the Canfield stereotactic head cage.

A dermatologist assessed the blinded baseline and 6-week images for each patient and graded cosmetic-related categories (skin roughness and dryness, fine lines and wrinkles, dyschromia and hyperpigmentation, and global improvement) based on a scale of 0 to 4, where 0=no change from baseline (0%); 1=slight improvement from baseline (1%–25%); 2=moderate improvement from baseline (26%–50%); 3=marked improvement from baseline (51%–75%); and 4=severe improvement from baseline (76%–100%).

Evaluation of skin roughness and dryness represents a qualitative assessment of skin texture from very smooth (grade 0) to very rough (grade 4). Textural features likely to contribute to this grade include dryness, scalliness, wrinkles, and other surface irregularities. Discrete lesions such as keratoses, nevi, and comedones were not included in this grading.

Fine lines and wrinkles were evaluated based on a visual assessment of the change in the appearance of superficial wrinkles from grade 0 (no lines) to 4 (heavily lined) from baseline as determined by the expert grader.

Erythema and edema were graded based on a qualitative assessment of redness of the skin from very slight (grade 0) to extreme (grade 4).

Dyschromia and hyperpigmentation were evaluated based on a qualitative assessment of skin pigmentation from normal (grade 0) to extreme (grade 4).

Global improvement represents a qualitative assessment of all the previous scoring categories when combined.

Photographs were processed with Canfield's RBX (red and brown) technology and resulted in 2 images, 1 highlighting redness and 1 highlighting brownness and pigment. These photographs were presented to the grader with the pretreatment and posttreatment participant images laid out side by side, but in random order (ie, the pretreatment image could be on the right or left side for each participant). The grader was then asked to select the best photograph of the participant.

The participants who had a posttreatment photograph selected as the best image were classified as improved, the

participants who had a pretreatment photograph selected as the best image were classified as worse, and if neither photograph was selected as the best image, the participant was classified as unchanged.

Participants were provided with a diary and asked to record each evening any adverse events or reactions that they had experienced. Adverse event data from the diaries were listed and summarized.

The study was conducted from October 30, 2006, through December 18, 2006, at the Institute of Anti-Aging Research, Virginia Beach, and the principal investigator was David H. McDaniel, MD.

### Biopsies

Bilateral, uniform skin biopsies were taken from 4 split-face participants (2 with active ingredient on the right side, 2 on the left side) at baseline and week 6. The paraffin sections were stained with hematoxylin-eosin and Masson trichrome and were immunostained with antibodies for collagen I, collagen IV, MMP-1, and IL-1 $\beta$ .

The stained slides were imaged using fluorescent filters and recorded digitally. The digital images were then analyzed using a color-based method to determine the percentage of tissue stained for a specific marker in both the pretreatment and posttreatment slides.

### In Vitro Polymerase Chain Reaction Microarray Evaluations

Human skin fibroblasts (cell culture AG07999, 32-year-old female) were seeded into 6 well dishes at an average density of  $8.6 \times 10^4$  cells per well in 5 mL of minimal essential medium with 10% fetal bovine serum (FBS),  $1 \times$  nonessential amino acids, 2 mM L-glutamine, and  $1 \times$  GlutaMAX. After 3 days, the cells were near or at confluency and were fed 2.5 mL of the same medium, except that FBS was lowered to 5% and 0.29 mg/mL L-ascorbic acid phosphate magnesium salt n-hydrate was added to support collagen production. After 24 hours, cells were exposed to test conditions. For the duration of the experiment, the same medium with L-ascorbic acid phosphate magnesium salt n-hydrate was used except that FBS was lowered to 1%. Duplicate wells received 0.001% CBE in 2.5-mL medium at 12-hour intervals or 0.001% CBE for 12 hours, then medium only for 12 hours or medium only at 12-hour intervals. At 72 hours (total of 6 medium changes), a final medium change was made and RNA from the duplicate wells was isolated for microarray analysis.

Isolation of RNA was done using the QIAGEN RNeasy Mini Kit and the manufacturer's recommended instructions for animal cells directly lysed in culture dishes.

All results were analyzed using SuperArray software per the manufacturer's instructions. As a control measure, the

individual threshold cycles were used to distinguish any outlying values to be excluded from analysis. The detection range for threshold cycles of genes was 35 cycles (ie, any gene with no threshold cycle value under 35 cycles, either in the control or experimental cycle, was out of the detectable range).

## RESULTS

### Participant Disposition

Of the 30 participants enrolled, 28 completed the 6-week study, including all 10 split-face participants and 17 of 20 full-face participants. The reasons for premature discontinuation were lost to follow-up because of personal or work-related commitments.

### Demographic and Baseline Characteristics

All 30 participants enrolled were females with moderate photoaging as assessed by the investigator. Mean age was 55 years (range, 31–71 years).

### Efficacy

The blinded experts' grading results are summarized in Figures 1 and 2 for the full-face participants (n=17) and split-face participants (n=10), respectively.

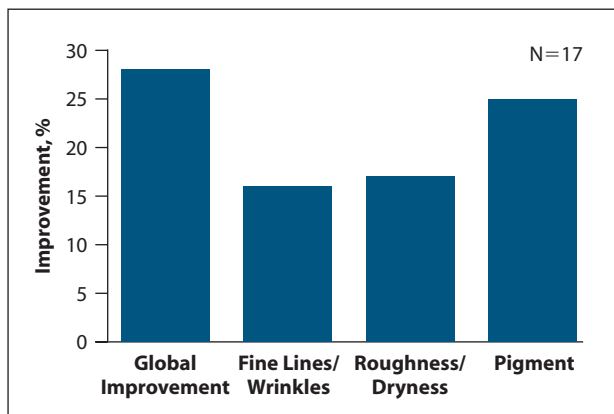
Based on the blinded experts' grading, the mean percentage improvement in full-face participants after 6 weeks of treatment with CBE was 27% for global improvement, 16% for fine lines and wrinkles, 18% for roughness and dryness, and 25% for pigment (Figure 1). In the split-face participants, the mean percentage improvement was greater on the CBE side versus the vehicle side for global improvement (29% vs 8%), fine lines and wrinkles (24% vs 3%), roughness and dryness (10% vs 9%), and pigment (15% vs 5%) (Figure 2).

### Safety

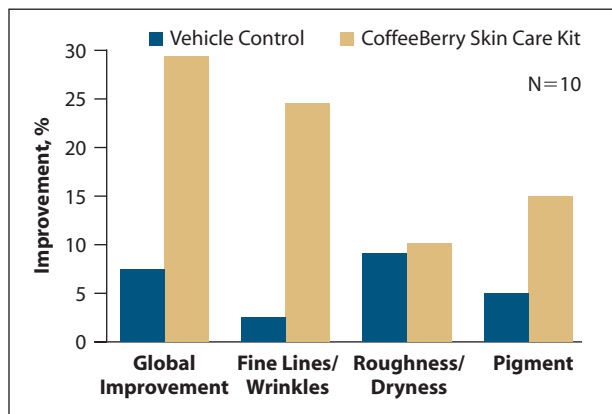
No serious adverse events or allergic reactions were reported. A total of 22 adverse events were reported in 13 participants, including acne flare-up (6 participants), redness (4 participants), burning (4 participants), and peeling (1 participant). All of the adverse events were assessed as mild in severity, and 2 were assessed as related to the study product. The redness and burning were of short duration, and the peeling resolved with continued product use. Of the 6 cases of acne flare-ups, 4 appeared to be related to either hormonal cycle or other factors unrelated to product use, although transient chemical folliculitis resembling acne may occur with topical antioxidants.

### Biopsy Results

In the 4 split-face participants who were biopsied, the mean percentage improvement was greater on the CBE



**Figure 1.** Blinded expert grading. Mean percentage improvement in full-face participants after 6 weeks of using the CoffeeBerry extract system (N=17).



**Figure 2.** Blinded expert grading. Mean percentage improvement in split-face participants after 6 weeks of using the CoffeeBerry extract system or the vehicle regimen (N=10).

side versus the vehicle side for global improvement (45% vs 9%), fine lines and wrinkles (39% vs 6%), and pigment (19% vs 3%) and the same for roughness and dryness (13% on both sides).

Results of the most distinctive (defined as the largest noticeable difference) CBE-treated slides are summarized in Table 2, which presents the percentage of tissue stained for a specific marker prior to and after treatment with CBE and vehicle control for each participant.

In general, the results were variable among participants, with some showing greater degrees of change after treatment with CBE. The basic trend was toward increased dermal collagen I and IV, a reduction of MMP-1, and inflammatory response. There were some mild changes in the compactness of the stratum corneum and in the organizational arrangement of the epidermal layer, and this type of finding is usually consistent with clinically improved skin texture and a reduction in fine lines and wrinkles.

TABLE 2


Percentage of Tissue Stained for a Specific Marker Prior to and After Treatment With CBE and Vehicle Control for Each Participant

Protein/ Participant	Vehicle			CBE		
	Pre-treatment	Post-treatment	Change	Pre-treatment	Post-treatment	Change
Collagen I, % tissue stained						
Participant 1 <sup>a</sup>	27	29	2	27	38	11
Participant 2 <sup>b</sup>	42	64	22	23	33	10
Collagen IV, % tissue stained						
Participant 1 <sup>a</sup>	22	38	16	45	52	7
IL-1β1, % tissue stained						
Participant 1 <sup>a</sup>	3	3	8	33	25	-8
Participant 3 <sup>b</sup>	8	2	-6	31	11	-20
MMP-1, % tissue stained						
Participant 1	11	27	16	32	18	-14
Participant 3	8	4	-4	17	6	-11


Abbreviations: CBE, CoffeeBerry extract; IL, interleukin; MMP, matrix metalloproteinase.

<sup>a</sup>Participant 1 was treated with vehicle on the left and CBE on the right side of the face.

<sup>b</sup>Participants 2 and 3 were treated with CBE on the left and vehicle on the right.



**Figure 3.** Red coloration of the dermis before (A,C) and after using the CoffeeBerry extract system (suggesting a reduction in vascularity)(B,D). Photographs have undergone color separation processing in order to isolate the red coloration in the dermis.

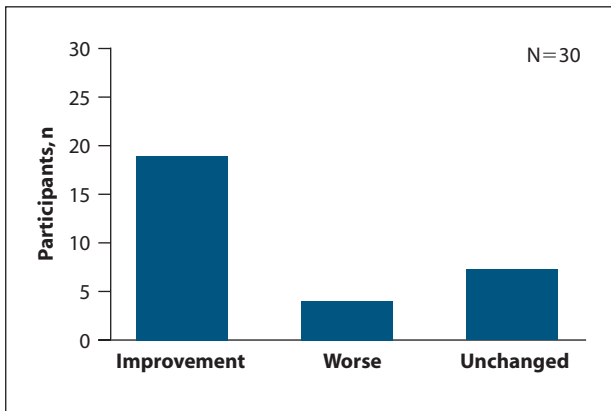


**Figure 5.** Brown coloration of the dermis before (A,C) and after using the CoffeeBerry extract system (indicating a reduction in pigmentation)(B,D). Photographs have undergone color separation processing in order to isolate the brown coloration in the dermis.

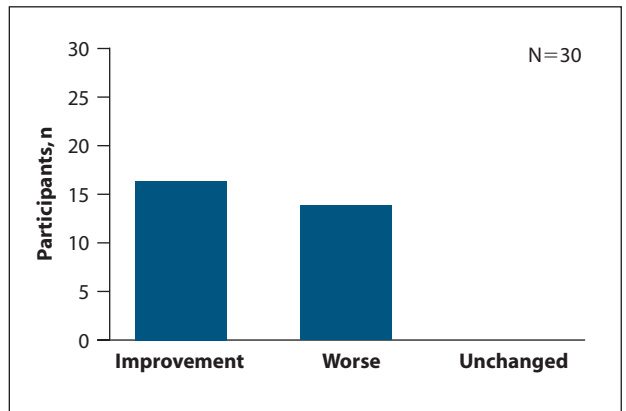
**Results of In Vitro Polymerase Chain Reaction Microarray Evaluations**

Common practice for determining the significance of polymerase chain reaction–based tests is to use a 2-fold change as the minimum (or 100% increase in genetic message). However, for the purposes of this study, a minimum change of 1.6-fold (60% increase in genetic

message) was defined as significant to illustrate trends and show potential for future studies. The following genes demonstrated either a positive or negative 1.6-fold minimum change when exposed to 0.001% CBE once a day or twice a day for 72 hours. Once-daily up-regulation or positive change in expression levels was shown in collagen 12a1 (1.62); collagen 14a1 (2.00); collagen 15a1 (1.62);



**Figure 4.** Expert grading of red variable, Canfield RBX analysis demonstrating a comparative red color (vascularity) space analysis of participants treated with CoffeeBerry extract.



**Figure 6.** Expert grading of brown variable, Canfield RBX analysis demonstrating a comparative brown color (pigment) space analysis of participants treated with CoffeeBerry extract .

## TREATMENT OF PHOTOAGED SKIN

$\alpha_3$  integrin (1.62); laminin  $\alpha_2$  (1.62); laminin  $\beta_3$  (2.00); paraplegin (1.74); C-type lectin domain family 3 member B (1.74); and tenascin C (1.62). Once-daily down-regulation or negative change in expression levels was shown in CD44 antigen (-2.64) and  $\alpha_5$  integrin (-2.14). Twice-daily up-regulated genes were collagen 12a1 (1.77); collagen 14a1 (1.65); collagen 15a1 (1.65); collagen 16a1 (2.03); connective tissue growth factor (1.65); laminin  $\gamma_1$  (1.90); thrombospondin 2 (1.65); and vascular cell adhesion module 1 (1.77). Twice-daily down-regulated genes were fibronectin 1 (-1.60);  $\alpha_5$  integrin (-1.83); MMP-1 (collagenase) (-1.60); MMP-13 (collagenase 3) (-1.60); and MMP-15 (-1.71).

### RBX Color Space Analysis

Figures 3 through 6 depict the Canfield RBX color space analysis technology. An expert grader evaluated participant photographs at week 6 for amount of redness (vascularity) or brownness (pigmentation) and compared to photographs at baseline by assigning a score of improved, worse, or unchanged. Analysis of these results showed that 63% of the participants improved in the expert grading of the redness variable. The results also showed that 53% of the participants improved in the expert grading of the brownness variable.

## DISCUSSION

This article presents results of the initial clinical evaluations of CBE, including the gene-expression profile of cultured human fibroblasts after multiple dosing of 0.001% CBE and results of a 6-week pilot study of twice-daily application of 1% concentration CBE cream and 0.1% concentration CBE cleanser in a study group of 30 participants.

In the pilot study, blinded expert grader evaluations showed significant improvement globally and in fine lines and wrinkles and skin pigmentation with CBE treatment relative to vehicle controls. In full-face evaluations, the improvement in pigmentation was one of the most

noticeable changes and led to greater global improvement scores than if only fine lines and wrinkles had been considered.

No serious adverse events or allergic reactions were reported in this study, and the few adverse events reported were mild and short in duration.

The biopsy results suggest that CBE produces an increase in the accumulation of structural proteins such as collagen I and collagen IV, as well as a reduction in collagenase (MMP-1) and IL-1 $\beta$ 1 (inflammatory mediators). This is consistent with the gene expression data (polymerase chain reaction microarray analysis).

## CONCLUSION

The collective results of this pilot study show that CBE demonstrates some level of corrective and reparative effects upon photoaged skin. Additional clinical trials are warranted to further evaluate the benefits of CBE in participants with photoaged skin.

**Acknowledgments**—Technical and clinical support by Christopher Mazur, Denise Bennett-Carter, Dawn Holm, Susan Leslie, Susan Wilson, and Eugene Taylor.

## REFERENCES

1. Valenzuela A, Sanhueza J, Nieto S. Natural antioxidants in foods: from food safety to health benefits. *Grasas y aceites*. 2003;54:295-303.
2. Hsu S. Green tea and the skin. *J Am Acad Dermatol*. 2005;52:1049-1059.
3. Lupo MP, Draelos ZD, Farris PK, et al. CoffeeBerry: a new, natural antioxidant in professional antiaging skin care. *Cosmet Dermatol*. 2007;20(suppl 4):2-9.
4. Draelos Z. A double-blind, randomized clinical trial evaluating the dermatologic benefits of coffee berry extract [abstract]. *J Am Acad Dermatol*. 2008;58(suppl 2):AB64.
5. Canfield introduces next generation skin imaging technology-RBX™. Canfield Scientific, Inc. [http://www.canfieldsci.com/News/Press\\_Releases.html](http://www.canfieldsci.com/News/Press_Releases.html). Accessed December 21, 2007.
6. Demirli R, Otto P, Viswanathan R, et al. RBX™ technology overview. <http://www.canfieldsci.com/FileLibrary/RBX%20tech%20overview-LoRz1.pdf>. Accessed September 28, 2009. ■