

# Hyaluronic Acid Filler and Botulinum Toxin Type A Delivered Simultaneously in the Same Syringe and Needle: A Novel Technique for Combination Aesthetic Rejuvenation Therapy

Julie R. Kenner, MD, PhD

---

Hyaluronic acid (HA) fillers and botulinum toxin type A (BNT) are frequently used in the same anatomic site to provide durable and natural looking outcomes by combining volumizing and contouring with movement reduction. In the current pilot study, HA and BNT from one manufacturer was coadministered simultaneously in a single syringe and needle into the crow's-feet region. These data were compared to findings published earlier using products derived from a different manufacturer. These preliminary data confirm that regardless of the manufacturer, delivering combined HA and BNT simultaneously through a single syringe and needle to the crow's-feet region of the face can result in highly acceptable cosmesis with half the number of needlesticks and high patient satisfaction. This technique may improve the patient experience by allowing the use of small-gauge needles and lessening the number of needlesticks incurred. Larger studies will better evaluate optimal techniques and safety/stability implications for administering simultaneous combination HA and BNT.

---

---

*Dr. Kenner is from Kenner Dermatology Center, Kailua, Hawaii.*

*The author reports no conflicts of interest in relation to this article.*

*Correspondence: Julie R. Kenner, MD, PhD, Kenner Dermatology Center, 642 Ulukahiki St, Ste 104, Kailua, HI 96734 (jkenner480@pol.net).*

**W**ith advances in our understanding of the causes of facial aging and patients' demands for less invasive procedures, facial rejuvenation techniques have evolved to rely heavily on the use of hyaluronic acid (HA) fillers and botulinum toxin type A (BNT).<sup>1,2</sup> Exponential increases in numbers of cosmetic procedures performed have occurred over the last decade.<sup>3</sup> While this trend includes both surgical and nonsurgical rejuvenation and enhancement procedures, the number of minimally invasive treatments far outweigh ( $\approx 80\%$ ) surgical interventions. Injectable facial shaping agents top the list of nonsurgical aesthetic treatments. These agents include BNT for treating dynamic wrinkles and replacement fillers such as HA for restoring volume, with both of these agents being widely used by cosmetic surgeons of all disciplines.<sup>1,4-17</sup> Because injectable rejuvenation procedures can delay or enhance more invasive surgical procedures with less cost and downtime for the patient, not only is the use of these agents growing but the ways in which we are using them are becoming more diverse and sophisticated.<sup>15-22</sup>

Standard practice for the administration of HA and BNT in the same facial region (ie, periorbital, glabella, forehead, prejowl, chin) is to have product applied in separate syringes at separate delivery depths, with BNT being delivered deeply to muscles for immobilization and HA delivered superficially in the dermis to reduce wrinkles.<sup>1,2</sup> Newer approaches to the administration of filler advocate much deeper placement to better achieve volume restoration.<sup>15-22</sup> Filler and neurotoxin treatments are often performed at separate appointments. In reality, many busy patients cannot take off time for 2 separate visits, resulting in suboptimal treatment and lost revenue to practices when patients do not follow-up as recommended. To counter this, a growing trend among cosmetic surgeons is to administer both HA and BNT at a single visit.<sup>1,2</sup> Not only has this practice allowed a more satisfying single experience for patients by providing them with immediate filling effects while they wait for the neurotoxin effects to take hold, but early data suggest that this technique of combining HA and BNT in the same area may increase the longevity of the aesthetic outcomes.<sup>1,2,12,14,16</sup> Although the choice of which injectable to administer first, HA or BNT, varies among physicians, products are routinely administered in separate syringes.<sup>1,2</sup> Less common since the advent of prepackaged HA with lidocaine, some practitioners still initially administer a pretreatment injection of local anesthesia into the treatment site to reduce the discomfort of the subsequently injected HA and BNT.<sup>2</sup> Yet other physicians may add anesthesia to the HA in

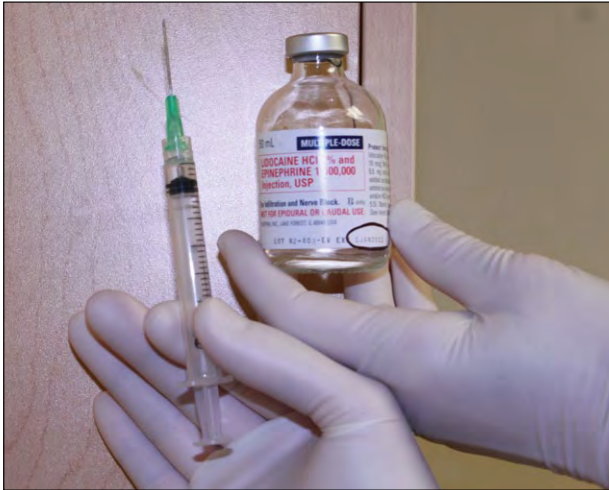a single syringe and inject this combined product prior to or after the administration of BNT.<sup>2,9</sup> Clearly double, or even triple, needlesticks to delicate areas such as the periocular region, can be uncomfortable and often results in bruising.

With this in mind, it was thought that by using a technique of injecting HA plus lidocaine and BNT simultaneously in the same needle, it might be possible to improve the aesthetic experience with half the number of needlesticks, while still maintaining excellent outcome.

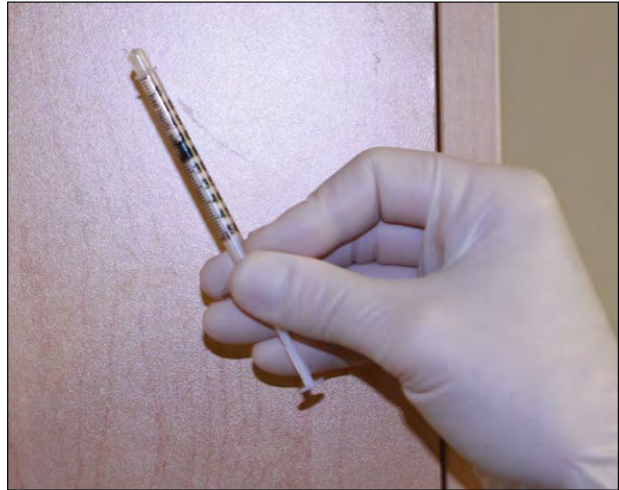Recently published findings using HA and BNT from one popular manufacturer (Medicis Pharmaceutical Corporation) provide encouraging data supporting the use of simultaneous coadministration of both products.<sup>23</sup> In the current study, we followed the same basic study design, administering simultaneously combined HA and BNT to the crow's-feet region, this time using products from a different manufacturer (Allergan, Inc) to see if results were similar to the previous study.

## METHODS

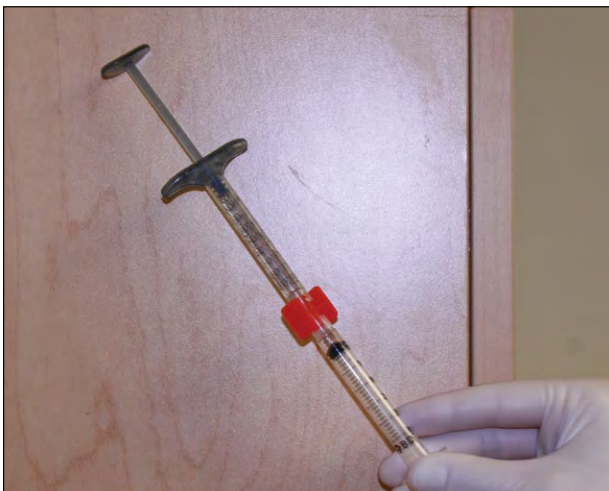Five female volunteers ranging in age from 49 to 58 years were recruited. Baseline standardized digital photographs were taken of each participant's frontal face and oblique left and right sides. Participants were photographed prior to treatment; immediately after; and 1, 2, 4, 6, and 8 weeks posttreatment. The treated areas were bilateral crow's-feet. One vial of HA (Juvéderm Ultra, Allergan, Inc) and 20 U of BNT (Botox Cosmetic, Allergan, Inc) were used for each volunteer, split evenly between left and right treatment sites. Neurotoxin was made freshly by using 1 cc of preservative containing normal saline in one 100-U vial of BNT. The combined products were prepared as follows. One 1-cc vial of HA filler was mixed with 0.25 cc of 1% lidocaine with 1:100,000 epinephrine in a 3-cc syringe using a 2-way connector (Figures 1 and 2). At least 10 back-and-forth mixings were performed to ensure even distribution of anesthesia within the filler. The BNT was then added to a second 3-cc syringe and mixed with the HA-anesthesia product (in the first 3-cc syringe) using the connector (Figures 3-5). At least 10 back-and-forth mixings were performed to ensure even distribution of all product ingredients throughout the volume. The combined product cocktail was administered to the crow's-feet of the participants (Figures 6-9). Three injection sites per side were used (6 injections total), with volume split evenly amongst each injection site. The combined product was placed in the skin just below the dermis using a 30-gauge ½-in needle and injected in small boluses as per usual practice. For several minutes immediately



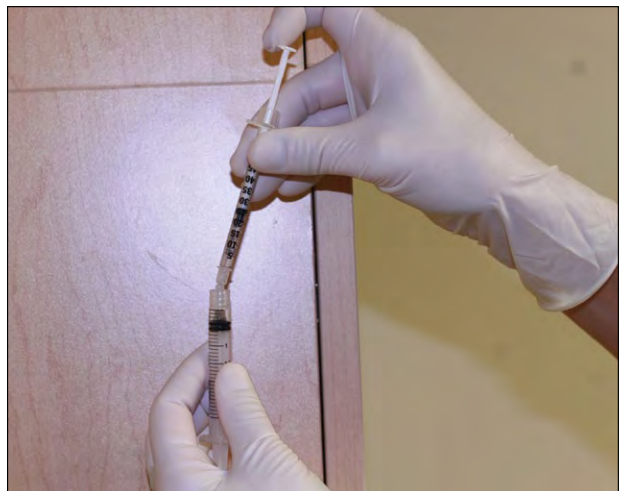
**Figure 1.** Lidocaine with epinephrine in a 3-cc syringe.



**Figure 3.** Botulinum toxin type A measured out in a tuberculin syringe.



**Figure 2.** Hyaluronic acid being mixed with anesthesia.

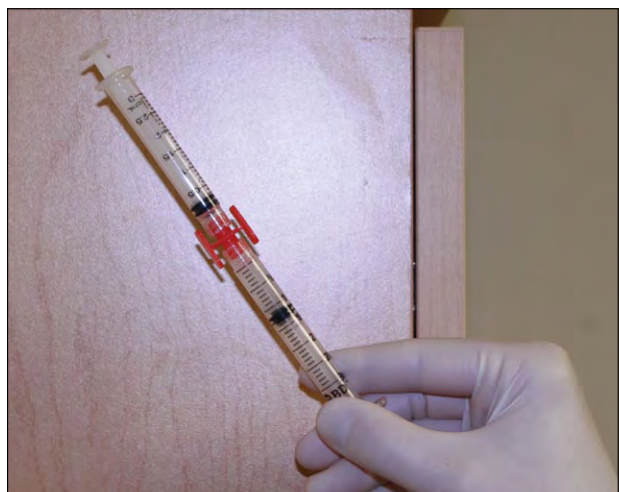


**Figure 4.** Botulinum toxin type A added to a 3-cc syringe.

after injection, gentle massage of the treated areas was performed.

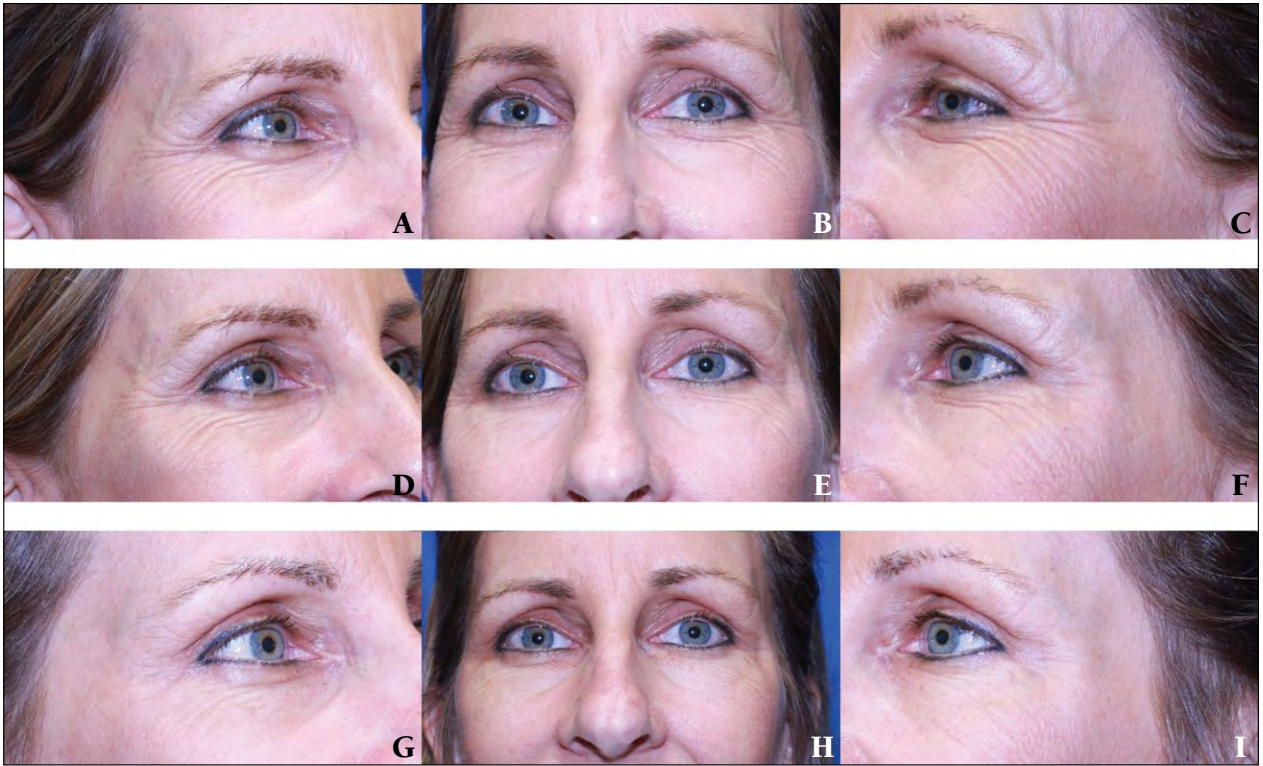
## RESULTS

All participants tolerated the procedure well, without bruising, asymmetry, ptosis, surface nodules, or other complications. The combined product that was massaged locally immediately after injection blended smoothly into the treatment areas (Figures 6 and 8). Botulinum toxin, when given in combination with filler in this small population, appeared to take hold as rapidly (3–5 days) and robustly as historical rates of product onset when given alone, without evidence of “drift” into undesired areas (Figures 7 and 9). Study participants were all pleased with their results both immediately posttreatment and throughout the 2-month observation period.

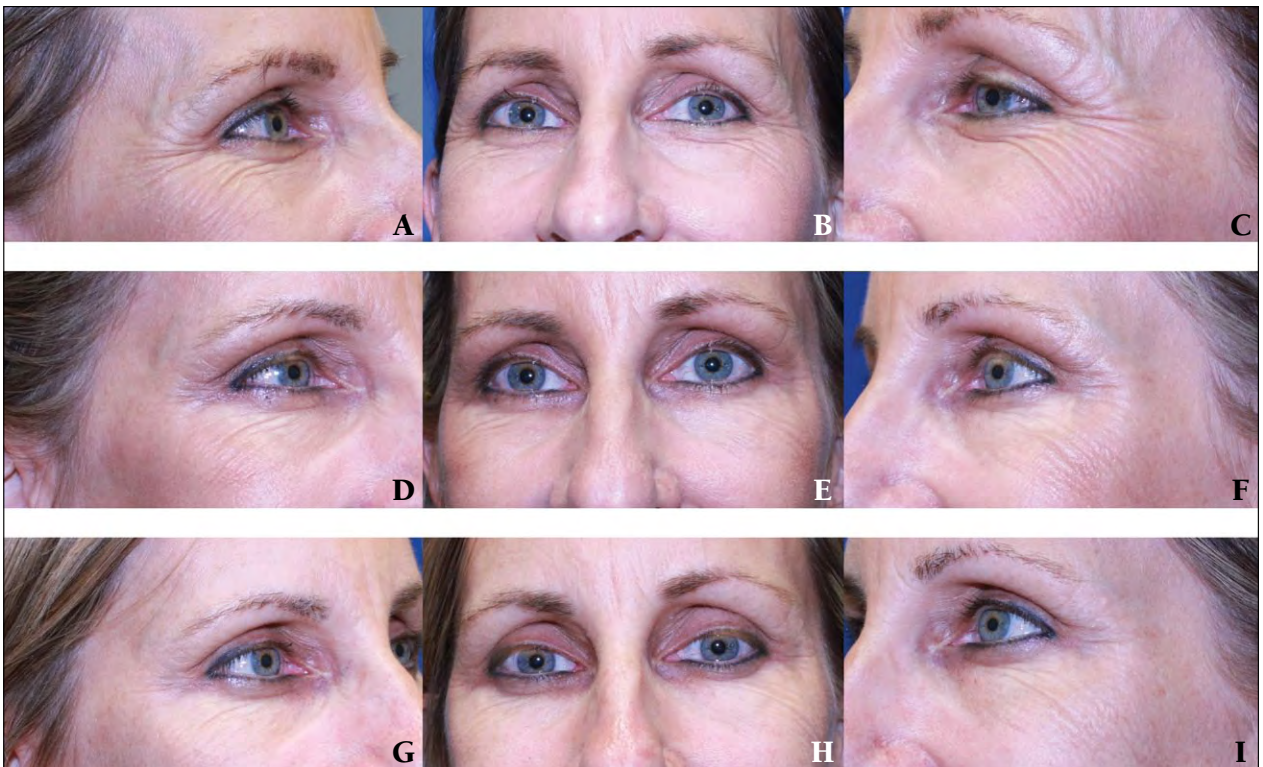


**Figure 5.** Botulinum toxin type A being mixed into hyaluronic acid–anesthesia via connector.



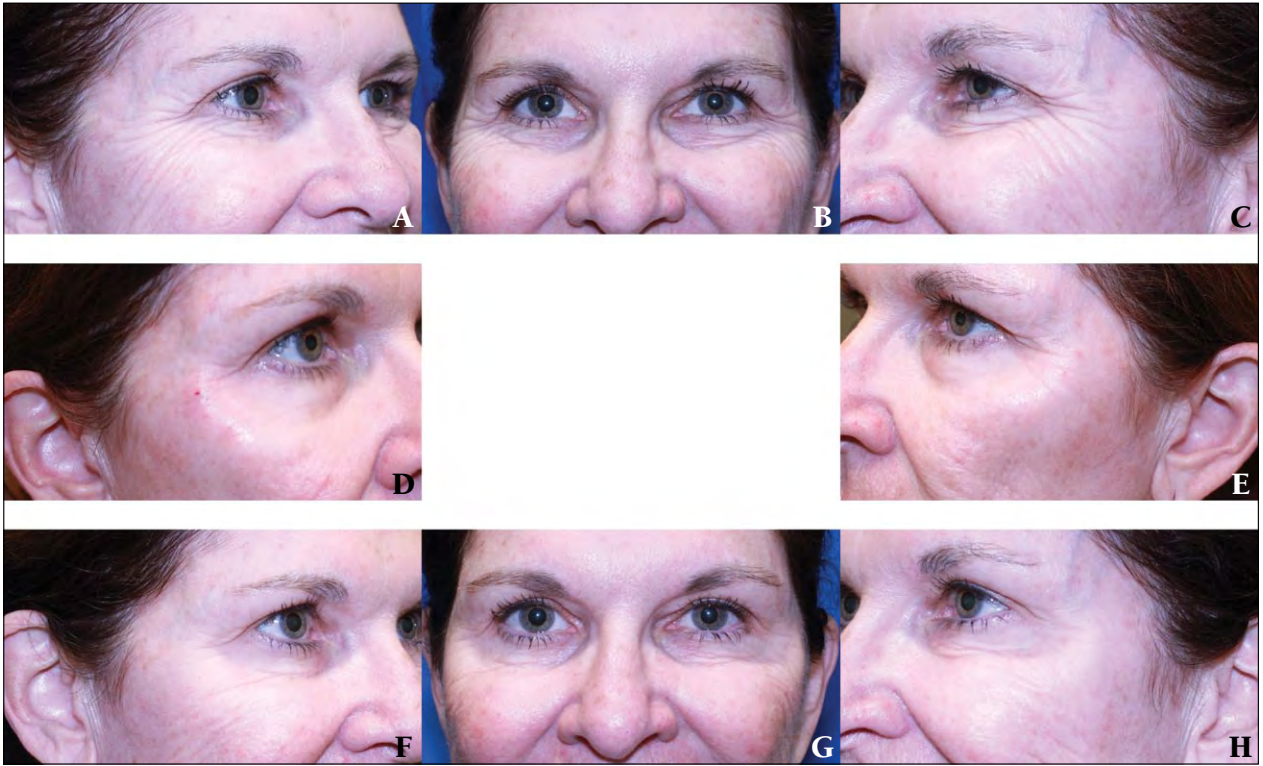

**Figure 6.** Pretreatment (A–C), immediately posttreatment (D–F), and 2 weeks posttreatment (G–I).

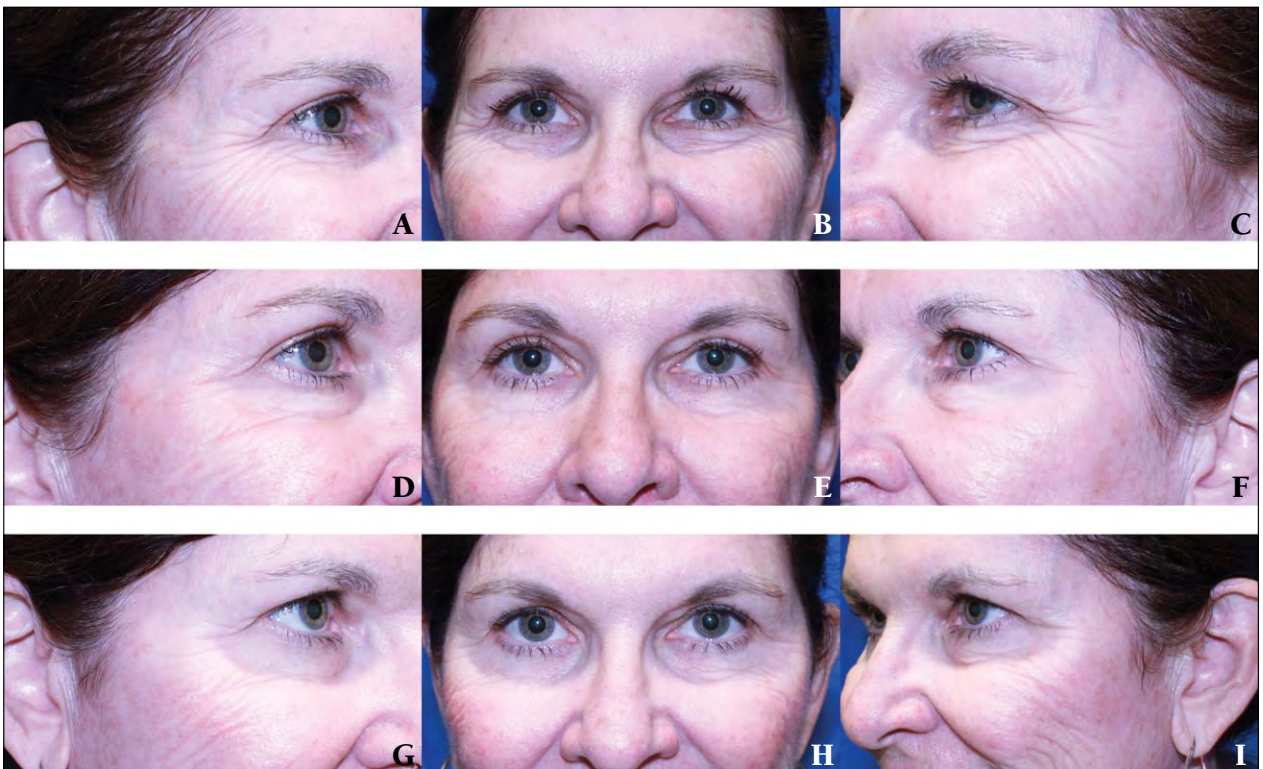


**Figure 7.** Pretreatment (A–C), 1-month posttreatment (D–F), and 2-months posttreatment (G–I).





**Figure 8.** Pretreatment (A–C), immediately posttreatment (D and E), and 2 weeks posttreatment (F–H).



**Figure 9.** Pretreatment (A–C), 1-month posttreatment (D–F), and 2-months posttreatment (G–I).

## COMMENT

The application of safe and effective nonsurgical cosmetic treatments, particularly with injectable shaping agents such as HA and BNT, has increased substantially over the last decade.<sup>1-3,10-14,22</sup> With more collective experience and as more is learned about the anatomy of the aging face, more sophisticated and innovative methods for delivering these products have developed, resulting in less downtime and improved outcome.<sup>15,19,22</sup> Hyaluronic acid and BNT are now routinely injected into similar locations of the face to optimally address the needs of the aging face.<sup>1,2,15,22</sup> In addition to the complementary actions of these products, data are emerging to suggest that the combination of HA and BNT may actually result in synergism of effects, with both products lasting longer than when compared to individual administration, an issue of considerable importance to patients.<sup>1,2,12,14,22</sup> Moreover, some practitioners suggest that using both products in the same area may reduce adverse events, with the BNT-induced muscle relaxation allowing filler to stay in place better, and conversely the mass effect of filler preventing BNT from drifting into unwanted locations near the eyes, lips, glabella, or chin.<sup>2</sup>

When addressing the wrinkles of the crow's-feet region, current practice today is to inject HA and BNT in separate needles, either at a single visit or sequential appointments. Both of these techniques result in 2 sets of needlesticks in the same location, effectively doubling the pain and risk for bruising for patients. By convention, these products are administered to different cutaneous depths, with HA being placed in the dermis and BNT in the muscles.<sup>1,2,4-12</sup> In reality, certain regions of the aged face, particularly the periocular area, have very little distance between the dermis, subcutis, and muscle regions, and recent data suggest there is often spillover of product into unintended (deeper) cutaneous regions in the clinical injection setting regardless of intended placement.<sup>16,17</sup>

The deeper placement of filler in skin appears to be gaining momentum as an improved volumizing technique.<sup>15,22</sup> Products are placed into the deeper aspects of skin both to reduce the incidence of superficial nodules and irregular contours and to fill hollows more naturally.<sup>13,18,22</sup> The advanced practitioner is now commonly using both replacement and biostimulatory fillers at all layers of the face, including the subcutis and periosteum, to more naturally contour and reshape the aging face, thus postponing or avoiding the need for invasive surgery.<sup>15,18,22</sup>

In a recent pilot study,<sup>23</sup> it was demonstrated that HA and BNT can be delivered simultaneously in the same needle to the crow's-feet and glabella regions of the face with excellent results. Although larger-population studies

will be needed to determine the long-term efficacy and safety of this technique using the Medicis HA and BNT products, the current study explored the question of whether using a different company's products would give similar findings to this earlier study. This current pilot study, using Allergan products, confirms the concept that HA and BNT, irrespective of manufacturer source, may be administered simultaneously in a safe and efficacious manner.

Combining HA and BNT treatment in a single needle for simultaneous injection offers several advantages over separate injections for both the patient and the injector. Bruising and pain are inherently cut in half by administering combined products into a single injection. Patients receive an enhanced cosmetic experience by seeing the immediate effects of filler while waiting for the neurotoxin to take hold over the next several days and may benefit from longer efficacy of both products when administered together. Using anesthesia in the mixture of products not only reduces pain and bruising at the treatment sites but also keeps the treated areas immobile for a few hours posttreatment, allowing the filler to be massaged into the treated areas smoothly. Mixing the viscous HA with the thinner consistency neurotoxin and anesthesia results in a less thick injection, enabling the practitioner to use smaller-gauge needles for injecting, which further reduces the pain and chance of bruising. Finally, there is a theoretical possibility that mixing the jellylike HA product with neurotoxin may prevent diffusion and allow more precise neurotoxin placement in the muscles of interest.<sup>2</sup>

Clearly, there will always be the need for injectables such as HA and BNT to be delivered to skin individually in different locations when managing the aging face. Nevertheless, with the rise in use of both of these agents administered to similar anatomic locations to capitalize on their complementary actions, it is an exciting time to follow technical innovations regarding the use of these products in combination. The current study demonstrates a novel technique that may improve the coadministration of HA and BNT in certain regions of the face, such as the crow's-feet, glabella, and depressor anguli oris/chin areas (although these latter areas were not explored in this small study). Larger randomized, controlled studies using HA and BNT are needed to obtain adequate safety data, determine optimal combination treatment techniques, and study the long-term effects of combined products on patient outcome.

## REFERENCES

1. Carruthers JD, Glogau RG, Blitzer A. Facial Aesthetics Consensus Group Faculty Collaborators. Advances in facial rejuvenation:

- botulinum toxin type A, hyaluronic acid dermal fillers, and combination therapies—consensus recommendations. *Plast Reconstr Surg*. 2008;121(suppl 5):5S-30S; 31S-36S.
2. Klein AW, Fagien S. Hyaluronic acid fillers and botulinum toxin type A: rationale for their individual and combined use for injectable facial rejuvenation. *Plast Reconstr Surg*. 2007;120(suppl 6):81S-88S.
  3. Fitzgerald R, Graivier MH, Kane M, et al. Surgical versus nonsurgical rejuvenation. *Aesthetic Surg J*. 2010;30:285-305.
  4. Ascher B, Rzany BJ, Grover R. Efficacy and safety of botulinum toxin type A in the treatment of lateral crow's feet: double-blind, placebo-controlled, dose-ranging study. *Dermatol Surg*. 2009;5:1478-1486.
  5. Kane MA, Brandt F, Rohrich RJ, et al. Evaluation of variable-dose treatment with a new US botulinum toxin type A (Dysport) for correction of moderate to severe glabellar lines: results from a phase 3, double-blind, placebo-controlled study. *Plast Reconstr Surg*. 2009;124:1619-1629.
  6. Moy R, Maas C, Monheit G, et al. Long term safety and efficacy of a new botulinum toxin type A in treating glabellar lines. *Arch Facial Plast Surg*. 2009;11:77-83.
  7. Lowe N, Grover R. Injectable hyaluronic acid implant for malar and mental enhancement. *Dermatol Surg*. 2006;32:881-885.
  8. Carruthers A, Carruthers J. A prospective, randomized, parallel group study analyzing the effect of BTX-A (Botox) and nonanimal sourced hyaluronic acid (NASHA, Restylane) in combination compared with NASHA (Restylane) alone in severe glabellar rhytides in adult female subjects: treatment of severe glabellar rhytides with a hyaluronic acid derivative compared with the derivative and BTX-A. *Dermatol Surg*. 2003;29:802-809.
  9. Beer K, Solish, N. Hyaluronics for soft-tissue augmentation: practical considerations and technical recommendations. *J Drugs Dermatol*. 2009;8:1086-1091.
  10. Kane M, Donofrio L, Ascher B, et al. Expanding the use of neurotoxins in facial aesthetics: a consensus panel's assessment and recommendations. *J Drugs Dermatol*. 2010;9:57-522.
  11. Brandt F, Swanson N, Baumann L, et al. Randomized, placebo-controlled study of a new botulinum toxin type A for treatment of glabellar lines: efficacy and safety. *Derm Surg*. 2009;35:1893-1901.
  12. Rohrich R, Ghavami A, Crosby M. The role of hyaluronic acid fillers (Restylane) in facial cosmetic surgery: review and technical considerations. *Plast Reconstr Surg*. 2007;120(suppl 6):41S-54S.
  13. Beer, K, Yohn M, Cohen J. Evaluation of injectable CaHA for the treatment of mid-face volume loss. *J Drugs Dermatol*. 2008;7:359-366.
  14. Tierney E, Hanke C. Recent advances in combination treatments for photoaging: review of the literature. *Dermatol Surg*. 2010;36:829-840.
  15. Vleggaar D, Fitzgerald R. Dermatological implications of skeletal aging: a focus on suprapariosteal volumization for perioral rejuvenation. *J Drugs Dermatol*. 2008;7:209-220.
  16. Greco T, Elenitsas. Localization and histological characterization of injected hyaluronic acid in excised nasolabial fold tissue. *J Drugs Dermatol*. 2010;9:399-404.
  17. Arlett JP, Trotter MJ. Anatomic location of hyaluronic acid filler material injected into nasolabial fold: a histologic study. *Dermatol Surg*. 2008;34(suppl 1):S56-S63.
  18. Fitzgerald R, Graivier MH, Kane M, et al. Update on facial aging. *Aesthetic Surg J*. 2010; 30(suppl 1):11S-24S.
  19. Carruthers J, Carruthers A. Volumizing the glabella and forehead. *Dermatol Surg*. 2010;36:1905-1909.
  20. Carruthers J, Carruthers A, Tezel A, et al. Volumizing with a 20-mg/ml smooth, highly cohesive, viscous hyaluronic acid filler and its role in facial rejuvenation therapy. *Dermatol Surg*. 2010;36:1886-1892.
  21. Kleinerman R, Emanuel P, Goldenberg G. Treatment with hyaluronic acid fillers. *Cosmet Dermatol*. 2010;23:405-409.
  22. Fitzgerald R, Graivier MH, Kane M, et al. Appropriate selection and application of nonsurgical facial rejuvenation agents and procedures: panel consensus recommendations. *Aesthetic Surg J*. 2010; 30(suppl 1):36S-45S.
  23. Kenner J. Hyaluronic acid filler and botulinum neurotoxin delivered simultaneously in the same syringe for effective and convenient combination aesthetic rejuvenation therapy. *J Drugs Dermatol*. 2010;9:1135-1138. ■