

# Treatment Strategies for Pigmentation Disorders in Skin of Color

Eduardo K. Moioli, PhD; Aenoeal D. Bakus, PhD; Dina Yaghmai, MD; Claudia Hernandez, MD

Dyschromia can be especially disfiguring in patients with skin of color. Exogenous ochronosis, postinflammatory hyperpigmentation (PIH), and vitiligo often are highly noticeable in darker skin types and cause anguish for individuals affected by these conditions. This article will review the literature regarding current medical and procedural therapies for pigmentary disorders to update physicians on specific treatment options that are available for patients with darker skin types. Although treatment of these disorders remains difficult, there is an increasing number of therapeutic options that could lead to improvement in both the cosmetic appearance of the skin and the quality of life of patients who are affected by these psychologically distressing conditions. Most of the existing literature on the safety and efficacy of these treatments consists of case reports and cohort studies; there is a lack of larger randomized controlled trials. Further studies are necessary to yield safe reproducible results for treating pigmentary disorders in patients with skin of color. *Cosmet Dermatol.* 2011;24:524-531.

At first glance, the effects of cutaneous pigmentation disorders may seem purely cosmetic in nature, but they also can result in a profound psychological burden for patients, especially when located on the face, neck,

or hands. Although pigmentation disorders can affect all skin types, individuals with darker skin, including Asians, blacks, Latinos, and American Indians, are more susceptible. Ethnic minorities account for more than 30% of the US population, a percentage that is projected to increase to approximately 50% by 2050<sup>1</sup>; therefore, familiarity with the skin disorders that commonly affect patients with darker skin and the available treatment options is crucial to the practicing dermatologist. This review will provide updates on current management options for 3 pigmentation disorders: exogenous ochronosis, postinflammatory hyperpigmentation (PIH), and vitiligo.

## EXOGENOUS OCHRONOSIS

Exogenous ochronosis is a cosmetically disfiguring hyperpigmentation disorder that is highly prevalent in blacks

---

*Drs. Moioli and Yaghmai are from Feinberg School of Medicine, Northwestern University, Chicago, Illinois. Drs. Bakus and Yaghmai are from the Physician Laser and Dermatology Institute of Chicago. Dr. Hernandez is from the Department of Dermatology, University of Illinois at Chicago.*

*The authors report no conflicts of interest in relation to this article.*

*Correspondence: Claudia Hernandez, MD, University of Illinois at Chicago, Department of Dermatology (MC 624), 808 S Wood St, Room 376 CME, Chicago, IL 60612 (claudiah@uic.edu).*

and rarely affects white individuals. Hardwick et al<sup>2</sup> found that 15% of black males and 42% of black females attending general outpatient departments in 2 South African hospitals presented with ochronosis. Sixty-nine percent of the patients with ochronosis also reported prior use of topical skin lighteners.<sup>2</sup> Exogenous ochronosis also has been commonly reported in Asians who use hydroquinone (HQ) to treat melasma.<sup>3</sup>

Clinically, ochronosis presents as a bluish gray, asymptomatic, hyperpigmented discoloration that typically affects the malar eminences, temples, inferior cheeks, neck, back, and extensor surfaces of the extremities. Coarseness, erythema, and some pigmentation of the skin can be present in some mild cases. Disease progression often is marked by hyperpigmentation with darkly pigmented, coalescing papules and associated atrophy. Chronic and severe cases may result in the development of papulonodules. Yellow-brown or green globules and ochronotic fibers are observed in the papillary dermis on dermatopathologic evaluation. Chronic cases demonstrate ochronotic colloid milium, representing the degeneration of the ochronotic fibers and granulomas.

Exogenous factors that have been implicated in the development of ochronosis include topical use of HQ, which is the most commonly reported cause; topical use of phenol for leg ulcers; skin-lightening soaps and creams that contain mercuric compounds; resorcinol found in some over-the-counter topical acne treatments; and injectable quinine and other oral antimalarials.

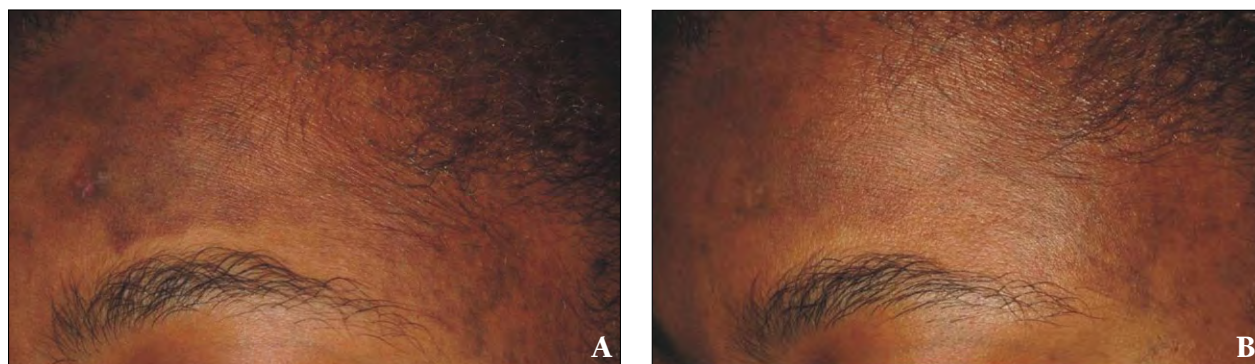
### Management of Ochronosis

*Topical*—Treatment of ochronosis remains difficult. The first step in any treatment plan should be avoidance of the offending agent; however, an extended period of time without contact with the agent is needed to yield noticeable improvement.<sup>4</sup> Sun avoidance and sunscreens also have shown modest efficacy.<sup>5</sup> Variable results have

been reported in the use of retinoic acid with some patients developing undesired transient hyperpigmentation, which underscores the sensitivity of darker skin types to irritation. Tetracycline has been shown to promote clearance of papular sarcoidlike ochronosis; however, this result has only been reported in 1 patient.<sup>6</sup> Overall, ochronosis remains largely refractory to topical treatment.

*Procedural*—Early procedural approaches such as chemical peels with trichloroacetic acid and cryotherapy with liquid nitrogen were reported in 1 black patient with no significant improvement of ochronosis.<sup>4</sup> The efficacy and safety of these treatments as monotherapies have not been reported. Advances in laser technology have increased the success rate in managing dyschromia associated with ochronosis. As reported by Bellew and Alster,<sup>7</sup> laser therapy is believed to disrupt the dermal ochronotic pigment fibers, leading to their subsequent phagocytosis and removal through lymphatic drainage or transepidermal elimination. In this study, 2 patients with exogenous ochronosis were treated bimonthly with a Q-switched alexandrite laser at a fluence of 7 to 8 J/cm<sup>2</sup> using non-overlapping 3-mm collimated spots; the patients also were instructed to avoid sun exposure. Progressive fading of hyperpigmentation was noted, and histologic evaluation after 6 treatments revealed a lack of dermal pigment deposits.<sup>7</sup>

Other pigment-specific lasers are thought to evoke a similar mechanism of pigment clearance, including the Q-switched 694-nm ruby and Q-switched 1064-nm Nd:YAG lasers. The Q-switched 1064-nm Nd:YAG laser has been successfully used for the treatment of dyschromia (Figure 1). In another study, a patient who was treated with a Q-switched ruby laser at 7 J/cm<sup>2</sup> for discoloration secondary to decades of HQ cream 2% use showed improvement<sup>8</sup>; however, physicians must be cautious, as the Q-switched 694-nm ruby laser has a shorter



**Figure 1.** A black female with exogenous ochronosis on the left side of the forehead and temporal regions secondary to chronic use of hydroquinone before (A) and after treatment with the Q-switched 1064-nm Nd:YAG laser (B).

wavelength, resulting in greater absorption at the melanocyte level. This possibility of decreased penetration into the dermis may not be desirable for the treatment of ochronosis given that it primarily occurs in patients with skin of color, limiting utility of the laser in this setting.

One case report of a black female patient who was treated with a combination of dermabrasion and a CO<sub>2</sub> laser achieved skin lightening with the CO<sub>2</sub> laser used in areas that were not amenable to dermabrasion, such as around the eyes, nose, and forehead.<sup>4</sup>

It should be noted that topical and nonpharmaceutical therapies should be used in combination with procedural methods because they are not likely to demonstrate high efficacy when used as monotherapy. A summary of therapeutic approaches for the treatment of exogenous ochronosis are highlighted in Table 1, and Figure 2 provides a treatment algorithm for exogenous ochronosis.

**POSTINFLAMMATORY HYPERPIGMENTATION**

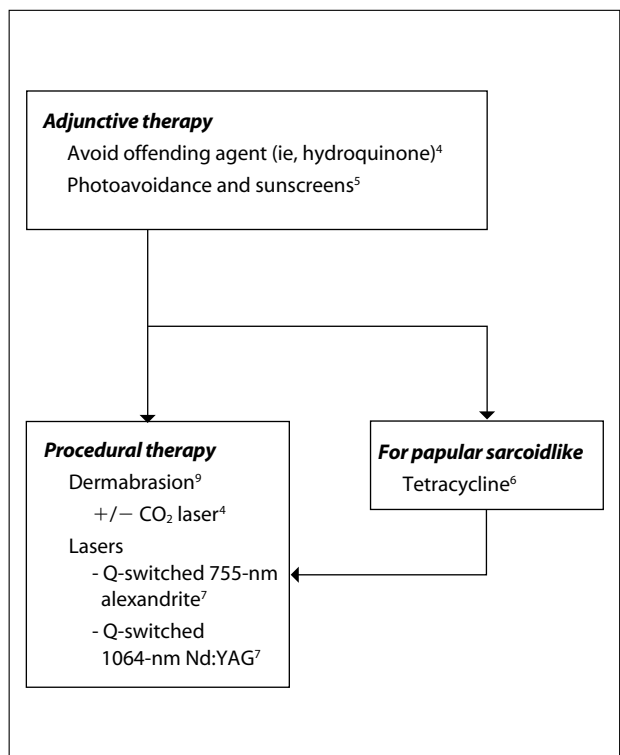
Postinflammatory hyperpigmentation in the epidermis presents as a tan or brown discoloration, while PIH in the dermis has a blue-gray appearance. Without treatment, dyschromia can take months to years to resolve and may be permanent. Postinflammatory hyperpigmentation is most commonly observed in Fitzpatrick skin types III to VI, which includes the majority of patients with skin of color. The development of PIH following acne likely is the most common cause of PIH seen by dermatologists. One study (239 blacks, 55 Hispanics, 19 Asians) showed that 65.3% of blacks, 52.7% of Hispanics, and 47.4% of Asians developed acne-induced PIH.<sup>10</sup>

**Management of PIH**

*Nonpharmaceutical*—Treatment of PIH should begin with management of the cause of inflammation. For instance, if the patient’s PIH is secondary to acne, optimal acne treatment should be administered to reduce the patient’s frustration with the occurrence of dyschromia. The same should be done with other inflammatory processes. Patients also should be counseled on the development of PIH given that they may erroneously continue treating areas with previously prescribed medications for the inflammatory condition. Patients often resort to tanning in an attempt to even out the pigmentation; however, use of photoprotection with sunscreen and photoavoidance should be part of patient counseling, as pigmentary lesions tend to darken with tanning.

*Topical*—The most commonly used topical agent for depigmentation is HQ. Hydroquinone works by inhibiting the enzyme tyrosinase, which blocks the conversion of dihydroxyphenylalanine to melanin. However,

Nonpharmaceutical	Topical	Procedural
Discontinuation of offending agent <sup>4</sup>	Sunscreens <sup>5</sup>	Dermabrasion <sup>9</sup>
Sun avoidance <sup>5</sup>	Tetracycline <sup>6</sup>	Dermabrasion plus CO <sub>2</sub> laser <sup>4</sup>
	Retinoic acid <sup>9</sup>	Q-switched 694-nm ruby laser <sup>8</sup>
		Q-switched 755-nm alexandrite laser <sup>7</sup>
		Q-switched 1064-nm Nd:YAG laser <sup>7</sup>



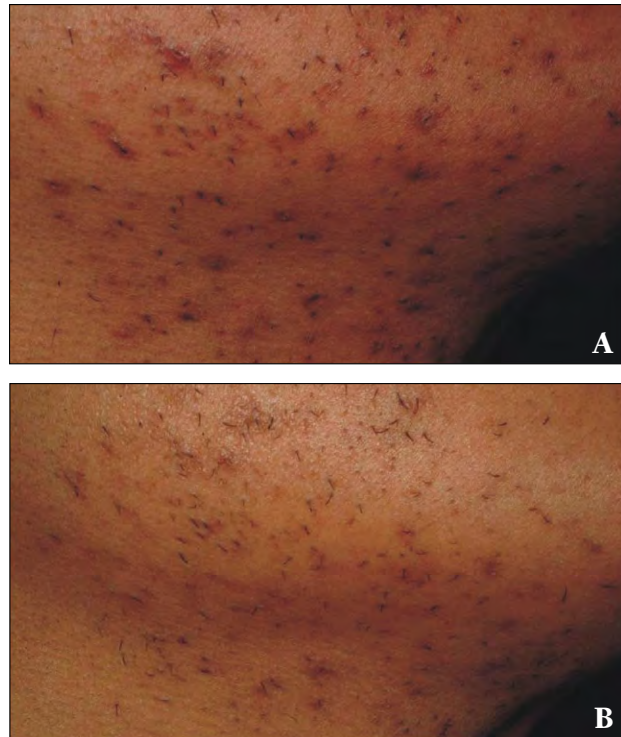
**Figure 2.** A suggested treatment algorithm for exogenous ochronosis.

monotherapy has not been as successful as the use of a combination of topical products. Patients in an open-label study who were treated twice daily with microencapsulated HQ 4% and retinol 0.15% with antioxidants for 12 weeks demonstrated improvement in their dyschromia. The investigators observed reductions in lesion size and darkness as early as 4 weeks into treatment, while 63% (12/19) of participants had either 75% overall improvement or complete clearing of hyperpigmented lesions after 12 weeks.<sup>11</sup> In addition to causing exogenous ochronosis, which was previously discussed, the side effects of HQ include contact dermatitis, nail discoloration, permanent leukoderma, and halo effect.<sup>12</sup> Retinoids,<sup>13</sup> tazarotene,<sup>14</sup> adapalene,<sup>15</sup> azelaic acid,<sup>16</sup> and *N*-acetylglucosamine or *N*-acetylglucosamine/niacinamide combination<sup>17</sup> also have been shown to improve PIH.

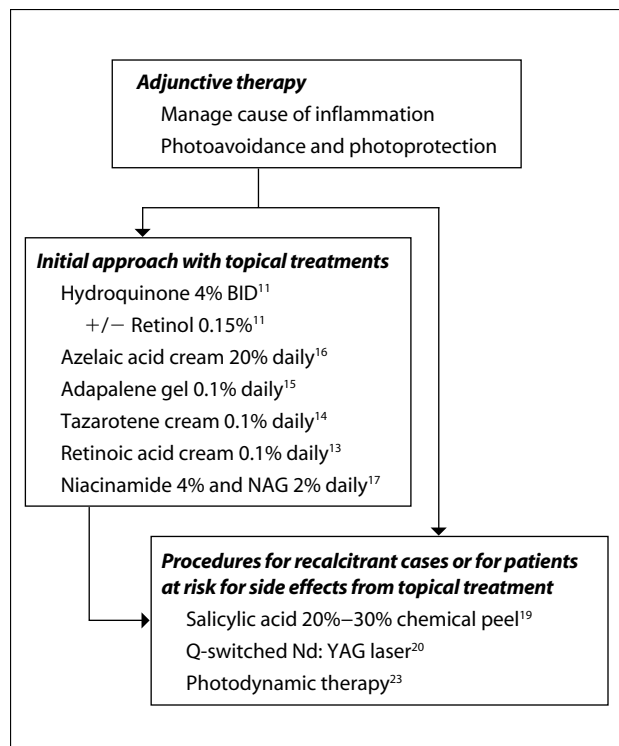
**Procedural**—Superficial chemical peels have been shown to be effective in the treatment of PIH, even in patients with darker skin.<sup>18</sup> Frequently used agents include glycolic acid (20%–70%) and salicylic acid (20%–30%).<sup>18,19</sup> A study of 10 patients with Fitzpatrick skin types IV to VI showed that salicylic acid peels were safe when used in this population; although patients rated the peels as clinically effective, blinded raters found peels to be less effective.<sup>19</sup>

Photodynamic therapy, lasers, and fractional photothermolysis are now increasingly used for the treatment of PIH. Three cases of PIH in Asian patients treated with a low-fluence 1064-nm Q-switched Nd:YAG laser showed maintenance of improvement at 2 months after final treatment. Patients underwent 5 treatment sessions that were delivered weekly to the entire face, with settings of 1.9 to 2.6 J/cm<sup>2</sup>, a 6-mm spot size, and 3 passes with appropriate overlapping.<sup>20</sup> Figure 3 shows PIH secondary to folliculitis that was treated with the Q-switched 1064-nm Nd:YAG laser. A study using fractional photothermolysis demonstrated improvement of dyschromia after 5 sessions administered 1 to 2 weeks apart using the 1550-nm wavelength Fraxel SR750 laser (Reliant Technologies, Inc) at a pulse energy of 6 to 10 mJ and a final density of 2000 to 3000 microscopic thermal zones/cm<sup>2</sup>. After 2 months, 50% to 75% improvement in dyschromia from baseline was observed in 1 patient and was maintained 3 months after cessation of treatment.<sup>21</sup> Six PIH patients treated with a 1550-nm nonablative fractional laser demonstrated no significant improvement in all outcome measures, including reflectance spectroscopy, melanin index, number of melanocytes, and amount of dermal melanin between treated and control skin.<sup>22</sup>

Blue light photodynamic therapy with aminolevulinic acid 20% has been used in combination with daily HQ cream 4% for 4 months in a black patient with both acne and associated PIH.<sup>23</sup> Visible improvement was



**Figure 3.** Brown-pigmented perifollicular macules in the mandibular area of a male patient secondary to folliculitis before (A) and after treatment with the Q-switched 1064-nm Nd:YAG laser (B).



**Figure 4.** A stepwise approach to the treatment of postinflammatory hyperpigmentation. BID indicates twice daily; NAG, *N*-acetylglucosamine.



observed after only 2 monthly photodynamic therapy sessions, and continued resolution of dyschromia persisted after 4 months. Of note, concurrent acne treatments included topical clindamycin/benzoyl peroxide and tazarotene throughout the study.<sup>23</sup> A stepwise approach to PIH is suggested in Figure 4.

### VITILIGO

Vitiligo results in milky white, cosmetically disfiguring patches that are especially noticeable in patients with skin of color because of the contrast observed in darker skin types. Vitiligo is a progressive disorder that is characterized by the destruction of melanocytes and affects up to 2% of the worldwide population. Commonly affected areas include the face, neck, scalp, ventral wrists, dorsal hands, and genitals, as well as mucous membranes. Proposed etiologies for the disease include autoimmune, cytotoxic, melanocyte defect, oxidant-antioxidant, and neural mechanisms.<sup>24</sup>

#### Management of Vitiligo

**Nonpharmaceutical**—Nonpharmacologic approaches have included cosmetic camouflage products, self-tanners, and cosmetic tattooing. One study showed that patients who used camouflage techniques had significantly improved emotional symptoms ( $P=.024$ ) compared to those who did not use camouflage.<sup>25</sup> Longer-lasting camouflage options include a color-matched simulated second skin that is sprayed on and can last up to 5 days (Microskin, Microskin & Simulated Skin Inc). This product has improved psychosocial functioning in pediatric burn patients.<sup>26</sup> Improvement in the appearance of lesions after cosmetic tattooing also has been demonstrated in localized stable vitiligo.<sup>25</sup>

**Topical**—Topical steroids have been used for treatment of vitiligo for decades and remain the most commonly used therapies. Systemic corticosteroids also have been shown to improve vitiligo symptoms; however, the side effects caused by systemic steroids preclude their extensive use. A thorough discussion of the risks and benefits must accompany the use of systemic steroids for a potentially chronic disease. Side effects of topical steroids include skin atrophy, telangiectasia, striae, adrenal insufficiency, and infections, among others. The repigmentation effects of topical steroids may be increased when combined with topical calcipotriene; however, calcipotriene alone has been shown to be inferior to topical steroids.<sup>27</sup>

Topical calcineurin inhibitors such as tacrolimus also can promote repigmentation of vitiligo lesions in children. Thirty patients evaluated as part of a prospective study found that tacrolimus ointment 0.1% applied twice daily resulted in some repigmentation in 83.3% (25/30)

of patients after 4 months. Seventy-six percent to 100% repigmentation was noted in 37.1% of patients with head and/or neck involvement, and initial repigmentation typically was noted after 6 weeks of treatment.<sup>28</sup> Although tacrolimus may cause a burning sensation in the area of application, it is thought to be a better option for sensitive areas given that it does not promote skin atrophy.<sup>29</sup>

**Phototherapy**—Phototherapy and photochemotherapy, to a more limited extent, have remained popular in the treatment of vitiligo given their effectiveness. The superiority of narrowband UVB (NB-UVB) to psoralen plus UVA has been reported. In one study, 64% (16/25) of patients in the NB-UVB group showed an improvement of more than 50% in body surface area affected compared to 36% (9/25) of patients in the psoralen plus UVA group.<sup>30</sup> Narrowband UVB also has been utilized in conjunction with pseudocatalase. In their study utilizing this regimen in pediatric vitiligo patients, Schallreuter et al<sup>31</sup> reported more than 75% repigmentation in 93% (66/71) of patients receiving treatment of the face and neck, 79% (48/61) of patients receiving treatment of the trunk, and 73% (40/55) of patients receiving treatment of the extremities. Phototherapy treatment options have been extensively covered in the literature.<sup>30-33</sup>

**Lasers**—High-energy monochromatic light can be precisely delivered to depigmented areas with the use of the excimer laser. Prior uses of this technology include treatment of postresurfacing leukoderma, mature hypopigmented striae, and psoriasis. A retrospective chart review of 97 chronic vitiligo patients who were treated with the 308-nm xenon chloride excimer laser demonstrated that 50.6% (112/221) of vitiligo patches treated showed 75% pigmentation or more, 25.5% (56/221) achieved 100% pigmentation, and 64.3% (142/221) showed 50% pigmentation or more.<sup>34</sup> As with other light delivery techniques, facial lesions showed a greater response to treatment than those in other areas.<sup>31</sup> The excimer laser yielded a better repigmentation response at earlier stages of the disease than in more chronic lesions, and long-term use with high-cumulative UV light elicited better responses.<sup>35</sup>

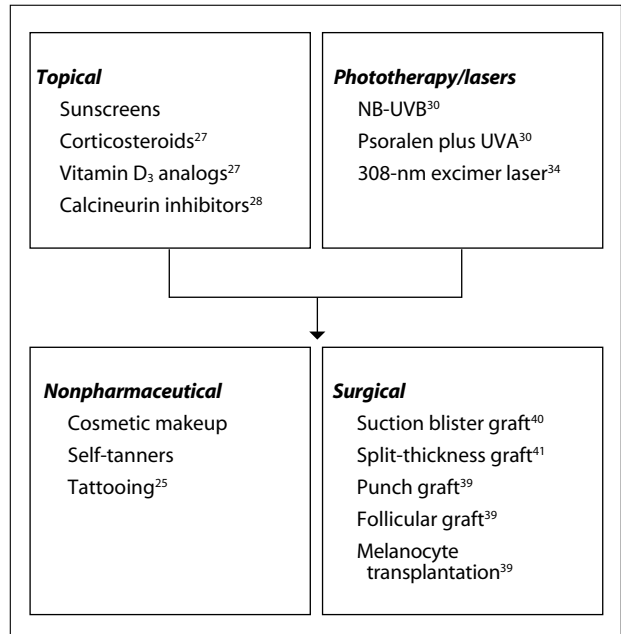
A multicenter, randomized, investigator-blinded study comparing 308-nm monochromatic excimer light and NB-UVB demonstrated that 37.5% (6/16) of the lesions treated with the monochromatic excimer light achieved 76% to 100% repigmentation versus 6% (1/16) treated with NB-UVB after 6 months of twice-weekly treatment.<sup>36</sup> In contrast, a recent randomized comparison of excimer laser versus NB-UVB phototherapy after punch grafting showed no significant difference in repigmentation between the 2 groups after 3 months of therapy. Importantly, excimer laser treatment had a 71.4% lower

cumulative UV dose than NB-UVB.<sup>37</sup> When selecting a treatment modality, not only repigmentation scores but also the possible side effects from cumulative UV dose should be evaluated. Thus patients with substantial sun damage or others at risk can benefit from the more precise delivery and lower cumulative dose of UV light with the excimer laser.

**Surgical**—The goal of surgical approaches is to restore melanocytes in areas affected by vitiligo. These approaches include suction blister grafting, split-thickness grafting, punch grafting, follicular grafting, and cultured and noncultured melanocyte transplantation.<sup>38</sup> Invasive procedures may be limited in patients susceptible to koebnerization, which can lead to scarring, graft failure, and infection. Njoo et al<sup>39</sup> reported in a systematic review of 63 studies that suction blister grafting and split-thickness grafting demonstrated the highest success rates, while punch grafting showed the highest rate of adverse effects, including a cobblestonelike appearance and scar formation at the donor site.

With the suction blister grafting technique, blisters are created at epidermal donor sites and are then grafted to prepared areas of vitiligo-affected skin.<sup>40</sup> The advantages of this technique include a lack of depigmentation and scarring in donor areas. In split-thickness grafting, the donor site is obtained by using a hand dermatome or a shaving blade. Although split-thickness grafting has the highest success rates, limitations include difficulty obtaining

uniform-thickness grafts, resultant stuck-on effects, persistent hyperpigmentation, and scars on donor areas.<sup>41</sup> A summary of therapeutic approaches for the treatment of vitiligo are highlighted in Table 2, and a treatment algorithm is provided in Figure 5.



**Figure 5.** A stepwise approach to the treatment of vitiligo. NB-UVB indicates narrowband UVB.

TABLE 2 Therapeutic Approaches for the Treatment of Vitiligo			
Nonpharmaceutical	Topical	Phototherapy/Lasers	Surgical
Cosmetic makeup	Sunscreens	NB-UVB <sup>30</sup>	Suction blister graft <sup>40</sup>
Self-tanners	Corticosteroids <sup>27</sup>	Psoralen plus UVA <sup>30</sup>	Split-thickness graft <sup>41</sup>
Tattooing <sup>25</sup>	Vitamin D <sub>3</sub> analogs <sup>27</sup>	308-nm excimer laser <sup>34</sup>	Punch graft <sup>39</sup>
	Calcineurin inhibitors <sup>28</sup>		Follicular graft <sup>39</sup>
			Melanocyte transplantation <sup>39</sup>

Abbreviation: NB-UVB, narrowband UVB.

## CONCLUSION

The number of patients with darker skin types who seek treatment of dyschromia will increase as the population with skin of color in the United States continues to grow; therefore, it is essential for the practicing dermatologist to be familiar with the presentation and management of pigmentation disorders in patients with skin of color. Discontinuing offending agents, managing exacerbating conditions, and preventing complications form the foundation for most treatment protocols. Topical agents in conjunction with or followed by procedural approaches such as light therapy and lasers also can be employed and have shown promising results in treating skin discoloration.

## REFERENCES

- Day JC. Population Projections of the United States by Age, Sex, Race, and Hispanic Origin: 1995 to 2050. Washington, DC: US Census Bureau; 1996.
- Hardwick N, Van Gelder LW, Van der Merwe CA, et al. Exogenous ochronosis: an epidemiological study. *Br J Dermatol.* 1989;120:229-328.
- Tan SK, Sim CS, Goh CL. Hydroquinone-induced exogenous ochronosis in Chinese—two case reports and a review. *Int J Dermatol.* 2008;47:639-640.
- Snider RL, Thiers BH. Exogenous ochronosis. *J Am Acad Dermatol.* 1993;28:662-664.
- Williams H. Skin lightening creams containing hydroquinone. *BMJ.* 1992;305:903-904.
- Fisher AA. Tetracycline treatment for sarcoid-like ochronosis due to hydroquinone. *Cutis.* 1988;42:19-20.
- Bellew SG, Alster TS. Treatment of exogenous ochronosis with a Q-switched alexandrite (755 nm) laser. *Dermatol Surg.* 2004;30(4, pt 1):555-558.
- Kramer KE, Lopez A, Stefanato CM, et al. Exogenous ochronosis. *J Am Acad Dermatol.* 2000;42(5, pt 2):869-871.
- Lang PG Jr. Probable coexisting exogenous ochronosis and mercurial pigmentation managed by dermabrasion. *J Am Acad Dermatol.* 1988;19(5, pt 2):942-946.
- Taylor SC, Cook-Bolden F, Rahman Z, et al. Acne vulgaris in skin of color. *J Am Acad Dermatol.* 2002;46(suppl 2 Understanding):S98-S106.
- Cook-Bolden FE, Hamilton SF. An open-label study of the efficacy and tolerability of microencapsulated hydroquinone 4% and retinol 0.15% with antioxidants for the treatment of hyperpigmentation. *Cutis.* 2008;81:365-371.
- Badreshia-Bansal S, Draelos ZD. Insight into skin lightening cosmetics for women of color. *J Drugs Dermatol.* 2007;6:32-39.
- Bulengo-Ransby SM, Griffiths CE, Kimbrough-Green CK, et al. Topical tretinoin (retinoic acid) therapy for hyperpigmented lesions caused by inflammation of the skin in black patients. *N Engl J Med.* 1993;328:1438-1443.
- Grimes P, Callender V. Tazarotene cream for postinflammatory hyperpigmentation and acne vulgaris in darker skin: a double-blind, randomized, vehicle-controlled study. *Cutis.* 2006;77:45-50.
- Jacyk WK, Mpofu P. Adapalene gel 0.1% for topical treatment of acne vulgaris in African patients. *Cutis.* 2001;68(suppl 4):48-54.
- Lowe NJ, Rizk D, Grimes P, et al. Azelaic acid 20% cream in the treatment of facial hyperpigmentation in darker-skinned patients. *Clin Ther.* 1998;20:945-959.
- Kimball AB, Kaczvinsky JR, Li J, et al. Reduction in the appearance of facial hyperpigmentation after use of moisturizers with a combination of topical niacinamide and N-acetyl glucosamine: results of a randomized, double-blind, vehicle-controlled trial [published online ahead of print August 28, 2009]. *Br J Dermatol.* 2010;162:435-441.
- Grimes PE. Management of hyperpigmentation in darker racial ethnic groups. *Semin Cutan Med Surg.* 2009;28:77-85.
- Joshi SS, Boone SL, Alam M, et al. Effectiveness, safety, and effect on quality of life of topical salicylic acid peels for treatment of postinflammatory hyperpigmentation in dark skin. *Dermatol Surg.* 2009;35:638-644; discussion 644.
- Cho SB, Park SJ, Kim JS, et al. Treatment of post-inflammatory hyperpigmentation using 1064-nm Q-switched Nd:YAG laser with low fluence: report of three cases [published online ahead of print April 23, 2009]. *J Eur Acad Dermatol Venereol.* 2009;23:1206-1207.
- Rokhsar CK, Ciocon DH. Fractional photothermolysis for the treatment of postinflammatory hyperpigmentation after carbon dioxide laser resurfacing [published online ahead of print February 22, 2009]. *Dermatol Surg.* 2009;35:535-537.
- Kroon MW, Wind BS, Meesters AA, et al. Non-ablative 1550 nm fractional laser therapy not effective for erythema dyschromicum perstans and postinflammatory hyperpigmentation: a pilot study [published online ahead of print July 14, 2011]. *J Dermatolog Treat.* doi:10.3109/09546634.2011.565016.
- Terrell S, Aires D, Schweiger ES. Treatment of acne vulgaris using blue light photodynamic therapy in an African-American patient. *J Drugs Dermatol.* 2009;8:669-671.
- Yaghoobi R, Omidian M, Bagherani N. Vitiligo: a review of published work. *J Dermatol.* 2011;38:419-431.
- Mahajan BB, Garg G, Gupta RR. Evaluation of cosmetic tattooing in localized stable vitiligo. *J Dermatol.* 2002;29:726-730.
- Martin G, Swannell S, Mill J, et al. Spray on skin improves psychosocial functioning in pediatric burns patients: a randomized controlled trial [published online ahead of print December 20, 2007]. *Burns.* 2008;34:498-504.
- Kumaran MS, Kaur I, Kumar B. Effect of topical calcipotriol, betamethasone dipropionate and their combination in the treatment of localized vitiligo. *J Eur Acad Dermatol Venereol.* 2006;20:269-273.
- Xu AE, Zhang DM, Wei XD, et al. Efficacy and safety of tacrolimus cream 0.1% in the treatment of vitiligo. *Int J Dermatol.* 2009;48:86-90.
- Lepe V, Moncada B, Castaneda-Cazares JP, et al. A double-blind randomized trial of 0.1% tacrolimus vs 0.05% clobetasol for the treatment of childhood vitiligo. *Arch Dermatol.* 2003;139:581-585.
- Yones SS, Palmer RA, Garibaldinos TM, et al. Randomized double-blind trial of treatment of vitiligo: efficacy of psoralen-UV-A therapy vs Narrowband-UV-B therapy. *Arch Dermatol.* 2007;143:578-584.
- Schallreuter KU, Krüger C, Würfel BA, et al. From basic research to the bedside: efficacy of topical treatment with pseudocatalase PC-KUS in 71 children with vitiligo. *Int J Dermatol.* 2008;47:743-753.
- Rath N, Kar HK, Sabhnnani S. An open labeled, comparative clinical study on efficacy and tolerability of oral minipulse of steroid (OMP) alone, OMP with PUVA and broad / narrow band UVB phototherapy in progressive vitiligo. *Indian J Dermatol Venereol Leprol.* 2008;74:357-360.
- Nicolaidou E, Antoniou C, Stratigos AJ, et al. Efficacy, predictors of response, and long-term follow-up in patients with vitiligo treated with narrowband UVB phototherapy. *J Am Acad Dermatol.* 2007;56:274-278.
- Hadi S, Tinio P, Al-Ghaithi K, et al. Treatment of vitiligo using the 308-nm excimer laser. *Photomed Laser Surg.* 2006;24:354-357.

## TREATMENT OF PIGMENTATION DISORDERS

35. Do JE, Shin JY, Kim DY, et al. The effect of 308nm excimer laser on segmental vitiligo: a retrospective study of 80 patients with segmental vitiligo. *Photodermatol Photoimmunol Photomed*. 2011; 27:147-151.
36. Casacci M, Thomas P, Pacifico A, et al. Comparison between 308-nm monochromatic excimer light and narrowband UVB phototherapy (311-313 nm) in the treatment of vitiligo—a multicentre controlled study. *J Eur Acad Dermatol Venereol*. 2007;21: 956-963.
37. Linthorst Homan MW, Spuls PI, Nieuweboer-Krobotova L, et al. A randomized comparison of excimer laser versus narrow-band ultraviolet B phototherapy after punch grafting in stable vitiligo patients [published online ahead of print June 29, 2011]. *J Euro Acad Dermatol Venereol*. doi:10.1111/j.1468-3083.2011.04147.x.
38. Rusfianti M, Wirohadidjodjo YW. Dermatological techniques for repigmentation of vitiligo. *Int J Dermatol*. 2006;45:411-417.
39. Njoo MD, Westerhof W, Bos JD, et al. The development of guidelines for the treatment of vitiligo. Clinical Epidemiology Unit of the Istituto Dermopatico dell'Immacolata-Istituto di Recovero e Cura a Carattere Scientifico (IDI-IRCCS) and the Archives of Dermatology. *Arch Dermatol*. 1999;135:1514-1521.
40. Mutalik S, Ginzburg A. Surgical management of stable vitiligo: a review with personal experience. *Dermatol Surg*. 2000;26:248-254.
41. Ozdemir M, Cetinkale O, Wolf R, et al. Comparison of two surgical approaches for treating vitiligo: a preliminary study. *Int J Dermatol*. 2002;41:135-138. ■