

Traction Alopecia: A Clinical Approach to Diagnosis and Management

Edidiong Celestine Ntuen Kaminska, MD; Shani Francis, MD, MBA; Sarah L. Stein, MD

Traction alopecia (TA) is a form of hair loss that is caused by excessive tension on scalp hair. Hair loss from TA can occur in any area of the scalp where there has been sustained pull on hairs. Various hairstyles and hairstyling techniques frequently have been associated with TA, and patients of any age or race can be affected. We report 2 cases of TA in black females and review the clinical characteristics of TA as well as the challenges that patients and physicians face in managing and treating this condition.

Cosmet Dermatol. 2012;25:118-124.

Cultural, social, and cosmetic practices influence how hair is styled. Grooming practices that traumatize the hair or scalp may result in both temporary and permanent damage or hair loss, which also may cause psychologic distress. Acquired hair injury due to exogenous exposure may contribute to aesthetically displeasing hair texture, color, luster, elasticity, and manageability.¹ Traction alopecia (TA) is a type of acquired hair loss that results from excessive tension on scalp hair. Women are predominantly affected,² and TA is particularly common in black females; however, no gender, race, or age group is spared if hairstyling practices are highly traumatic.

Clinically, patients may present with pruritus, erythema, scaling, or folliculitis, as well as multiple short broken hairs that can progress to thinning and hair loss in affected areas. Patients may develop traction folliculitis without alopecia,³ though it may be a precursor to later alopecia. Initially, the alopecia is noncicatricial, but prolonged and excessive

tension leads to mechanical detachment of the hair shaft from the follicle, ultimately resulting in follicular atrophy and permanent alopecia.⁴

Traction alopecia can be classified as marginal or non-marginal based on the distribution of hair loss. Marginal hair loss occurs along the frontal, temporal, and parietal hairlines and has been associated with continued use of chemical relaxers and rollers or wearing hair in ponytails, tight cornrows, dreadlocks, and weaves.^{2,5-7} Nonmarginal alopecia has been described in foci of tension throughout the scalp.

We report 2 cases of TA and discuss the clinical obstacles that patients and physicians encounter when managing and treating this condition.

CASE REPORTS

Patient 1

An 11-year-old black girl with no notable medical history presented with hair loss of 2 years' duration. The patient's guardians denied using any relaxers or hair straightening techniques on the patient but reported that she frequently wore her hair in braids. The patient complained of an itchy scalp, and her mother noticed frequent scratching. Clinical examination revealed large, irregularly shaped patches of alopecia and decreased hair density along the bilateral temporoparietal scalp (Figure 1). There was no evidence of scaling, crusting, pustules, or excoriations, and no

From the Section of Dermatology, University of Chicago Department of Medicine, Illinois.

The authors report no conflicts of interest in relation to this article.

Correspondence: Sarah L. Stein, MD, University of Chicago Department of Medicine, Section of Dermatology, 5841 S Maryland Ave, Chicago, IL 60637 (sstein@medicine.bsd.uchicago.edu).

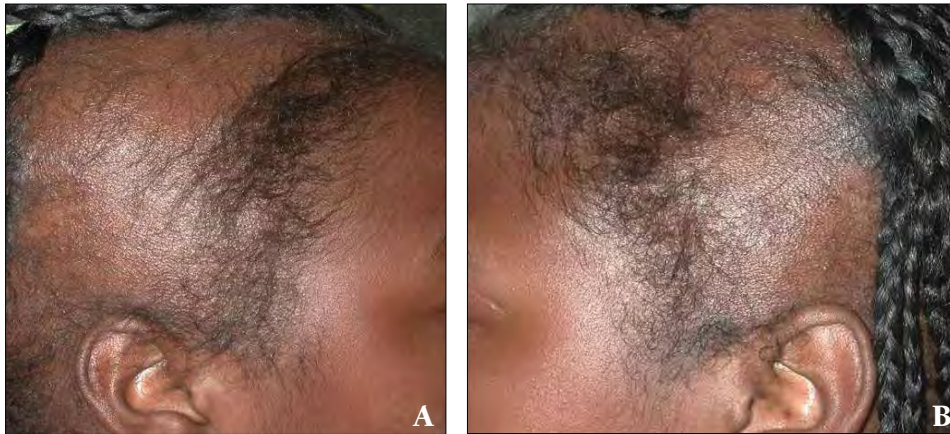


Figure 1. Extensive traction alopecia with temporoparietal scalp involvement in an 11-year-old girl (A and B).

exclamation point hairs were noted. No additional hair loss was observed on any other body sites, and the remaining scalp hairs appeared intact. A diagnosis of TA was suspected based on the patient's history of wearing tight braids and clinical examination of symmetric hair loss in the distribution of the tight braids. The patient was prescribed a regimen of ketoconazole shampoo 2% twice weekly and fluocinolone acetonide oil 0.01% daily to the scalp. Specific instructions for gentle hair care practices, such as avoiding tight braids and chemical relaxers, also were provided. The patient and her guardians were advised that hair regrowth was possible if scarring had not occurred.

Patient 2

A 28-year-old black woman presented for evaluation of hair loss on the scalp (Figure 2). She reported wearing tight microbraids and hair weaves intermittently over the last 15 years. Although she was counseled to discontinue hairstyling practices that contributed to hair loss, the patient continued to wear hair extensions to hide the bald patches on her scalp; she did not feel comfortable wearing her hair naturally and enjoyed the manageability and aesthetic appeal of hair weaves. The patient continues to wear hair weaves, but she tries not to include patches of her natural hair along the frontotemporal hairline to avoid further traction hair loss. The patient was advised that TA may still occur on other scalp sites with continuous use of hair weaves.

COMMENT

Presentation and Diagnosis

Excessive tension on scalp hairs resulting in hair loss is known as TA, which usually is caused by traumatic hairstyling practices. Although TA frequently has been reported in black females, males and other races also have been affected. Samrao et al⁸ reported the case of a white ballerina who developed TA after wearing her hair in tight buns for

several years. To conceal her alopecia, the patient wore a heavy (1.5 lb) hairpiece daily for 2 years, which resulted in patches of alopecia twice as large as the initial lesion.⁸ Traction alopecia caused by hair extensions also has been reported in white patients who were unaware of the ongoing trauma until their extensions were removed with tufts of natural hair still attached.⁹ Certain cultural practices also can lead to traction hair loss; for instance, Sikh patients who regularly wear turbans have been reported to develop TA in a bandlike distribution along the frontal hairline.¹⁰⁻¹³ Occupational hair loss has been described in nurses who developed TA from prolonged traction exerted at the point of attachment of the nurse's cap.¹⁴ Hairpin-induced alopecia also has been described; 3 black adolescent girls with tight hairstyles that were secured with hairpins developed ulcers that healed with scarring due to the tension and trauma.¹⁵

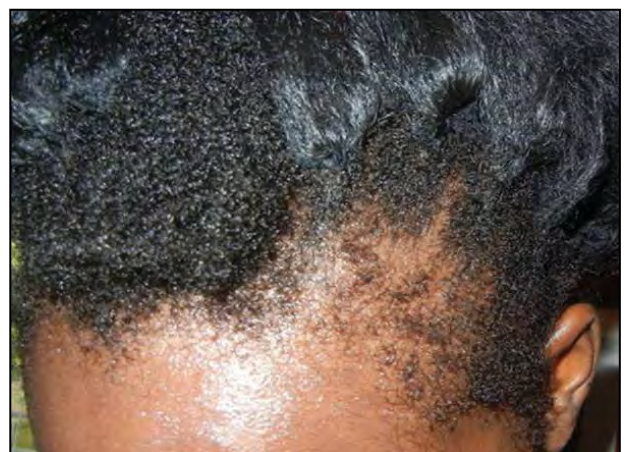


Figure 2. Traction alopecia with temporal scalp involvement in a 28-year-old woman. Despite being advised to discontinue traumatic hairstyling practices, the patient continued to wear hair weaves. She was advised that weaves place tension on the hair and can lead to further instances of hair loss. The patient did not include patches of her natural hair along the frontotemporal hairline, which has been spared from the traction alopecia.

TRACTION ALOPECIA

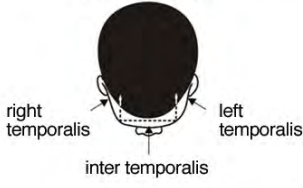
Traction alopecia may be diagnosed by history and clinical examination. A thorough evaluation requires questioning the patient about hair care products, grooming practices, medical disorders, medications, and a relevant family history.¹⁶ Clinical examination may show irregularly shaped patches of alopecia; thinning hair; and scattered broken hairs along tension lines, often in a symmetric pattern. Scaling and folliculitis also may be present. Dermoscopy may reveal clues that indicate TA, such as hair casts that appear as white to brown cylindrical structures with spindled edges that encircle the proximal hair shafts.¹⁷ These signs may indicate that traction is still occurring and is likely to progress. Biopsies demonstrate variable histopathologic findings depending

on the stage of alopecia. In the early stages of TA, there are increased numbers of telogen and catagen hairs; in later stages, terminal follicles are decreased and replaced with fibrous tracts and follicular miniaturization is common. In all stages, sebaceous glands are preserved and inflammation is mild to absent, unlike other cicatricial alopecias in which sebaceous glands typically are absent and inflammation and perifollicular fibrosis are more prominent.⁸

The marginal TA severity score has been proposed as a tool to assess disease severity (Figure 3).^{6,18} The scoring system requires assessment of the anterior and posterior scalp margins, with an imaginary line joining the tips of both ears. The anterior and posterior margins are further

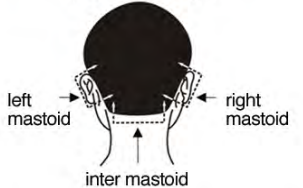
Marginal Traction Alopecia Severity (M-TAS) Score

anterior margin




right temporalis left temporalis
inter temporalis

posterior margin



left mastoid right mastoid
inter mastoid


land marks



point on hair line at edge of temporalis

mastoid process (bony prominence behind ear)

temporalis muscle (prominent with clenched jaw)







point on hair line above tip of ear

point on hair line below mastoid process

left temporalis

lower point on frontal hair line

Each area is demarcated by the distance between arrows as demonstrated. For each area enter 0 for a normal hair line, otherwise match it to one of the pictures below and enter the corresponding number in the table below.

Patient name: _____ **Folder number:** _____

Date																			
Right temporalis																			
Inter temporalis																			
Left temporalis																			
Total anterior score																			
Right mastoid																			
Inter mastoid																			
Left mastoid																			
Total posterior score																			

Figure 3. A grading scale for assessment of traction alopecia severity. Reprinted with permission from the *Journal of the American Academy of Dermatology*, Copyright 2008, with permission from Elsevier.⁶

divided into 3 sections. An examiner evaluates the 6 areas and assigns a severity score based on a photograph scale. The lowest score for any area is 0, which corresponds with a normal hairline, and the highest score is 4, which corresponds with severe alopecia. The highest total score for the anterior or posterior scalp is 12.⁶ The marginal TA severity score may be a useful tool to monitor disease progression and treatment.

The differential diagnosis for TA includes both scarring and nonscarring alopecia. Alopecia areata; central centrifugal cicatricial alopecia; traumatic alopecia from chemical, heat, and/or mechanical trauma; trichotillomania; and connective tissue disorders such as discoid lupus erythematosus should be considered. These conditions may be distinguished from TA based on clinical history, examination, and histopathology. For instance, in alopecia areata, there may be round patches of hair loss without any history of tight hairstyles. Exclamation point hairs may be present and hair casts are not observed with dermoscopy. Additionally, other body sites such as the face, trunk, and extremities may be affected. Perifollicular inflammation is observed on histology. The clinical signs of central centrifugal cicatricial alopecia may overlap with nonmarginal TA; history and biopsy results can distinguish the two. Traumatic alopecia may be clinically similar to TA and can be distinguished by history. Trichotillomania, hair loss from pulling out one's hair, presents as broken hairs of varying lengths from damage inflicted on different days. Connective tissue disorders such as discoid lupus erythematosus characteristically manifest as red inflamed plaques with a scaly and crusty appearance followed by dyspigmentation. Infectious causes of hair loss, such as tinea capitis and bacterial folliculitis, also should be excluded.

Management and Treatment Approaches

Management of TA includes establishing a good rapport with the patient and family members, as the diagnosis often is met with denial and feelings of guilt or regret. The fundamental practices that lead to chronic scalp trauma must be addressed and plans for alternative hair and scalp care should be discussed. Treatment of preexisting alopecia is a difficult process and published recommendations are the result of anecdotal experience, case reports, or small case series. There are several treatment options to consider.

Oral and Topical Antibiotics—Antibiotics may be prescribed in the early stages of TA when folliculitis is predominant. The goal of this treatment method is to prevent superinfection and decrease inflammation.⁵

Minoxidil—Khumalo and Ngwanya¹⁹ described 2 cases in which twice daily use of minoxidil led to hair regrowth in women with substantial and long-standing TA. Minoxidil may be a viable option for many patients;

however, recurrence of hair loss is possible with discontinued use, similar to the results observed when minoxidil treatment is stopped in patients with androgenic alopecia.

Hair Transplant—Ozcelik²⁰ described the case of a 23-year-old Turkish woman who developed symmetric temporal alopecia after wearing a tight ponytail daily for 5 years. Micrografts were obtained from the occipital scalp and were used on the temporal scalp. One year after the procedure, there was 95% graft survival. The primary complication in this case was self-resolving inclusion cysts.²⁰ The use of punch grafts, rotation flaps, and follicular unit transplants also have been reported as effective hair restoration procedures in patients with TA.^{5,21}

Steroids, Antifungals, and Vitamins—Topical or intralesional steroids,^{4,5} topical antifungals, and oral vitamin supplements also have been utilized. Steroids can help to decrease associated inflammation from TA. Some patients with TA may present with features overlapping with seborrheic dermatitis and topical antifungals can be beneficial. Biotin supplementation also can improve hair growth and strength.

Hair Regrowth Products—Some patients may purchase over-the-counter hair care products that promise regrowth. Oftentimes, patients will bring these products with them for physician evaluation. Although there are several concoctions that claim to regrow hair, no large randomized trials have proven their efficacy. Physicians should be prepared to educate patients and family members about the lack of clinical data supporting the use of these often expensive products.

Concealing Hair Loss—Traction alopecia can be devastating for patients. In an attempt to conceal damage to the hair and scalp, patients may continue traumatic practices, causing even more damage. Some of the benefits of hair extensions and weaves are added fullness and length as well as increased manageability of the hair. There are several different ways to apply hair extensions and weaves, and patients may use various terms to describe their hairstyling practices. Some common hairstyling terms are described in the Table and dermatologists should be familiar with these practices.

Many patients wear hair extensions, which are loose strands of synthetic or human hair that are braided into sectioned strands of the patient's natural hair. Each extension may be the same length or the hairstylist may apply varied lengths. Extensions that may be glued directly onto the patient's hair are known as fusion extensions; in this process, either preglued or loose hair extensions are added to strands of the patient's natural hair (Figure 4). These extensions are applied using the hot fusion method (a hot fusion connector is used to melt the bond into the hair until it adheres securely) or the cold fusion method (an ultrasound device and keratin-based polymer are used to

Hairstyling Terms

Term	Explanation
Braids	Hair typically is woven in strands of 3 starting proximally from the scalp down
Cornrows	Braids that lay flat against the scalp; may be worn as its own hairstyle or may be used for weave attachment
Microbraids	Thin braids that include extensions to produce a hairstyle that has a longer length
Do-rag/wave cap	A silky fabric that typically is worn to help relax the natural curl of the hair, resulting in a wavy appearance; also used to keep certain hairstyles in place
Dreadlocks/locks	Sections of hair are allowed to tangle and mat in clusters; when the hair is locked, it can no longer be combed out or picked apart
Greasing the scalp	Applying a moisturizing agent, usually a petrolatum-based ointment, to the scalp and proximal hair shafts to moisturize and/or treat pruritus of the scalp; the entire hair shaft also may be greased to moisturize the hair
Hair extensions	Adding loose strands of synthetic or human hair to sectioned strands of the patient's natural hair; techniques include braiding, fusion, and coiling
Straighten	Curly hair can be straightened by pressing, which involves using heated instruments such as hot combs or flat irons, to produce temporary straightening, or using chemical relaxers, which involves a cream that contains a strong alkali or ammonium thioglycolate active ingredient to irreversibly break the curl pattern of the hair
Weave	Hair is braided into cornrows and then tracks of synthetic or human hair are sewn into the braids; alternatively tracks also can be glued directly onto the scalp
Quick weave	A tight cap is applied to the scalp and the weave is glued onto the cap

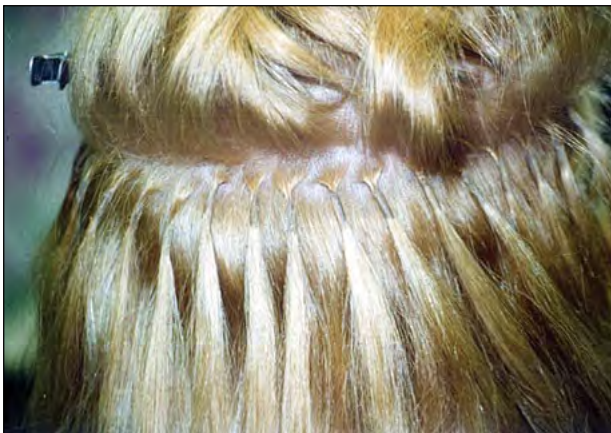

Figure 4. Fusion hair extensions.

attach hair extensions). To remove the glued extensions, an acetone solution often is used. Another method of adding hair extensions involves coiling loops of artificial or human hair into the patient's natural hair. In this process, hair is strung through a tiny copper coil along with the hair extension and then the coil is clamped with a

specialized tool that resembles pliers, thereby securing the extension. Another tool is used to mechanically remove the hair and coils.

Weaves are applied by braiding the patient's scalp hairs into cornrows and then sewing tracks of synthetic or human hair into the patient's hair. Tracks also can be glued directly onto the scalp and the patient's hair may or may not be braided. Another common variant of the glued weave is the quick weave, the process by which a tight cap is applied to the scalp and the weave is glued onto the cap. It functions as a custom-made wig.

Complications associated with extensions and weaves include traction folliculitis and contact dermatitis from chemically applied products such as the glue and acetone solution. If the hair extensions are left on the scalp too long, the patient's hair may become tangled and damaged. Additionally, the weight of the added hair, the tightness from braiding, the injury sustained from gluing and heating, and the mechanical removal process can exacerbate hair damage and tractional hair loss.

Patients may find that certain hairstyles and hairstyling techniques conceal the signs of alopecia, but they may not

realize that these practices may contribute to ongoing hair loss. Even hairstyles that do not involve chemical alteration and are traditionally considered natural, such as locked hair, can make TA symptoms worse. There are several ways to lock the hair, including braiding, twisting, and coiling with or without hair wax to maintain the locked structure. The basic principle of locking the hair is to intertwine or mat hairs together so that they cannot be easily combed or picked apart. Locks are made up of tangled unshed hair. Hair that normally is shed is incorporated into the locks and increases the weight of the hair and tension on the hairs. From our experience, patients with heavy locks often have a difficult time acknowledging that the increased weight of the hair causes TA.

Patient Education—One of the challenges of managing TA is that patients want to wear hairstyles that reflect their personal aesthetic preferences. Occupational, religious, and cultural customs may make it difficult for patients to change their hair care routines; therefore, it is imperative that physicians be sensitive to these pressures when discussing management options with patients. Patient education regarding the risks of their hairstyling practices must be emphasized. To encourage patient compliance, it often is helpful for the dermatologist to recommend alternatives to the patient's current practices. In our practice, patients are given a healthy hair care handout that addresses various types of alopecia and makes specific recommendations for patients, such as spacing out treatment with chemical relaxers, avoiding traumatic hairstyling practices, and maintaining an adequate and balanced nutritional diet. Specific signs of early scalp trauma, such as bumps around the hairline when hair is being pulled too tightly, also are described, as many patients are unaware that certain practices are traumatic and painful. Other specific suggestions may include wearing loose ponytails or braids, alternating the frequency or duration of hairstyles,⁷ and limiting use of heavy extensions. Hair extensions should be no longer than twice the length of a patient's natural hair at the time of placement,⁹ which should decrease the tension caused by the weight of extensions on the natural scalp hairs to which they are attached. It is important to realize that many patients will often find themselves in a downward spiral, as hair loss often triggers increasingly traumatic practices to camouflage the alopecia (Figure 5). Thus patients should be instructed to share their dermatologist's instructions with hairstylists.

CONCLUSION

In summary, damaging hairstyles often are driven by cultural and societal standards. Traction alopecia can be prevented and treated by alleviating tension on scalp hairs.

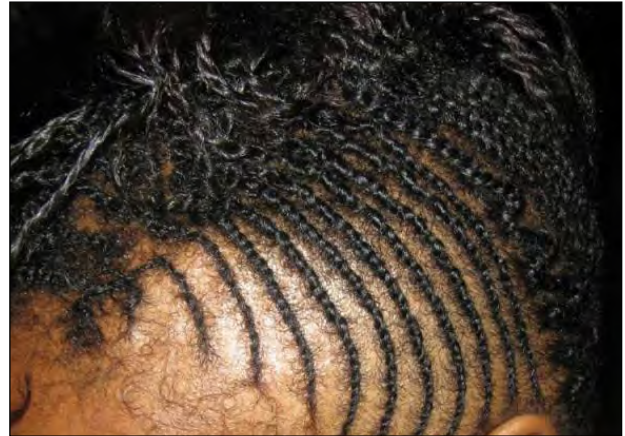

Figure 5. Traction alopecia in a female patient who did not realize that wearing cornrows to conceal hair loss could potentially make her condition worse. Note the widened parts between the anterior braids.

Physicians should be able to promptly recognize and counsel patients with TA. Emphasis on prompt correction and avoidance of ongoing traumatic hairstyling practices in a culturally sensitive fashion is paramount in managing patients with TA.

REFERENCES

- Horev L. Environmental and cosmetic factors in hair loss and destruction. *Curr Probl Dermatol.* 2007;35:103-117.
- Whiting DA. Traumatic alopecia. *Int J Dermatol.* 1999;38 (suppl 1):34-44.
- Urbina F, Sudy E, Barrios M. Traction folliculitis: 6 cases caused by different types of hairstyle that pull on the hair [in Spanish]. *Actas Dermosifiliogr.* 2009;100:503-506.
- Pourciau CY. Alopecias. In: Taylor S, Badreshia-Bansal S, Callender VD, et al, eds. *Treatments for Skin of Color.* Philadelphia, PA: Saunders Elsevier; 2011:242-244.
- Callender VD, McMichael AJ, Cohen GF. Medical and surgical therapies for alopecias in black women. *Dermatol Ther.* 2004;17: 164-176.
- Khumalo NP, Jessop S, Gumedze F, et al. Determinants of marginal traction alopecia in African girls and women. *J Am Acad Dermatol.* 2008;59:432-438.
- Rucker Wright D, Gathers R, Kapke A, et al. Hair care practices and their association with scalp and hair disorders in African American girls [published online ahead of print August 21, 2010]. *J Am Acad Dermatol.* 2011;64:253-262.
- Samrao A, Chen C, Zedek D, et al. Traction alopecia in a ballerina: clinicopathologic features. *Arch Dermatol.* 2010;146: 930-931.
- Yang A, Iorizzo M, Vincenzi C, et al. Hair extensions: a concerning cause of hair disorders [published online ahead of print November 11, 2008]. *Br J Dermatol.* 2009;160:207-209.
- James J, Saladi RN, Fox JL. Traction alopecia in Sikh male patients. *J Am Board Fam Med.* 2007;20:497-498.
- Kanwar AJ, Kaur S, Basak P, et al. Traction alopecia in Sikh males. *Arch Dermatol.* 1989;125:1587.

12. Karimian-Teherani D, El Shabrawi-Caelen L, Tanew A. Traction alopecia in two adolescent Sikh brothers-an under recognized problem unmasked by migration [published online ahead of print March 3, 2011]. *Pediatr Dermatol*. 2011;28:336-338.
13. Singh G. Letter: Traction alopecia in Sikh boys. *Br J Dermatol*. 1975;92:232-233.
14. Hwang SM, Lee WS, Choi EH, et al. Nurse's cap alopecia. *Int J Dermatol*. 1999;38:187-191.
15. Ntuen E, Stein SL. Hairpin-induced alopecia: case reports and a review of the literature. *Cutis*. 2010;85:242-245.
16. McMichael AJ. Ethnic hair update: past and present. *J Am Acad Dermatol*. 2003;48(suppl 6):S127-S133.
17. Tosti A, Miteva M, Torres F, et al. Hair casts are a dermoscopic clue for the diagnosis of traction alopecia [published online ahead of print November 4, 2010]. *Br J Dermatol*. 2010;163:1353-1355.
18. Khumalo NP, Ngwanya RM, Jessop S, et al. Marginal traction alopecia severity score: development and test of reliability. *J Cosmet Dermatol*. 2007;6:262-269.
19. Khumalo NP, Ngwanya RM. Traction alopecia: 2% topical minoxidil shows promise. report of two cases. *J Eur Acad Dermatol Venerol*. 2007;21:433-434.
20. Özçelik D. Extensive traction alopecia attributable to ponytail hairstyle and its treatment with hair transplantation. *Aesthetic Plast Surg*. 2005;29:325-327.
21. Earles RM. Surgical correction of traumatic alopecia marginalis or traction alopecia in black women. *J Dermatol Surg Oncol*. 1986;12:78-82. ■