

A Novel Pixilated Serial Puncture Technique for Forehead Recontouring Using Poly-L-lactic Acid

Yen-Yu Chao, MD; Hui-Hsien Chiu, MD

Volume loss is a major change that occurs to the aging face. Volume changes may originate in both soft and bony tissue. At present, there has been limited discussion in the literature on forehead recontouring and the application of fillers in this area. We present a case report of the off-label use of injectable poly-L-lactic acid (PLLA)(Sculptra Aesthetic, sanofi-aventis US LLC) for forehead recontouring using a novel serial puncture technique in pixilated patterns. Pixelated targeting provides a safe, easy, and effective method for utilizing PLLA to treat volume loss in the forehead.

Cosmet Dermatol. 2012;25:235-238.

Facial attractiveness is a cross-cultural concept that is measured by the appearance of youth, averageness, and symmetry.¹ The forehead curve, contiguous with the convexity of the eyebrow and glabella, is 1 of 3 primary arcs that are believed to define a youthful face.² The anterior protruding curve of the forehead and the convexity of the bilateral temples also are important in the constitution of a symmetrical and balanced face.

We describe a simple and effective method for addressing the shape of the forehead using a pixilated serial puncture technique to administer poly-L-lactic acid (PLLA)(Sculptra Aesthetic, sanofi-aventis US LLC)

injections, which represents the off-label use of PLLA. We report a case in which the procedure was performed in supraorbital areas to refine the contour of the forehead. We also discuss other instances in which recontouring was performed in different parts of the forehead from the superciliary arches to the hairlines.

CASE REPORT

A 39-year-old woman presented with a prominent supraorbital ridge and depressed temporal fossa; she was identified as a candidate for treatment with PLLA injections using the pixilated serial puncture technique (Figure 1A). A topical anesthetic containing lidocaine and prilocaine was applied to the treatment area on the forehead. The area also was cleansed with a disinfectant before injection. The PLLA was reconstituted with 6 mL of distilled water 3 days prior to injection. One milliliter of lidocaine 2% was added to the reconstituted PLLA suspension just before injection. The amount per aliquot (injection) was 0.05 to 0.2 mL of reconstituted PLLA suspension (6 mL of

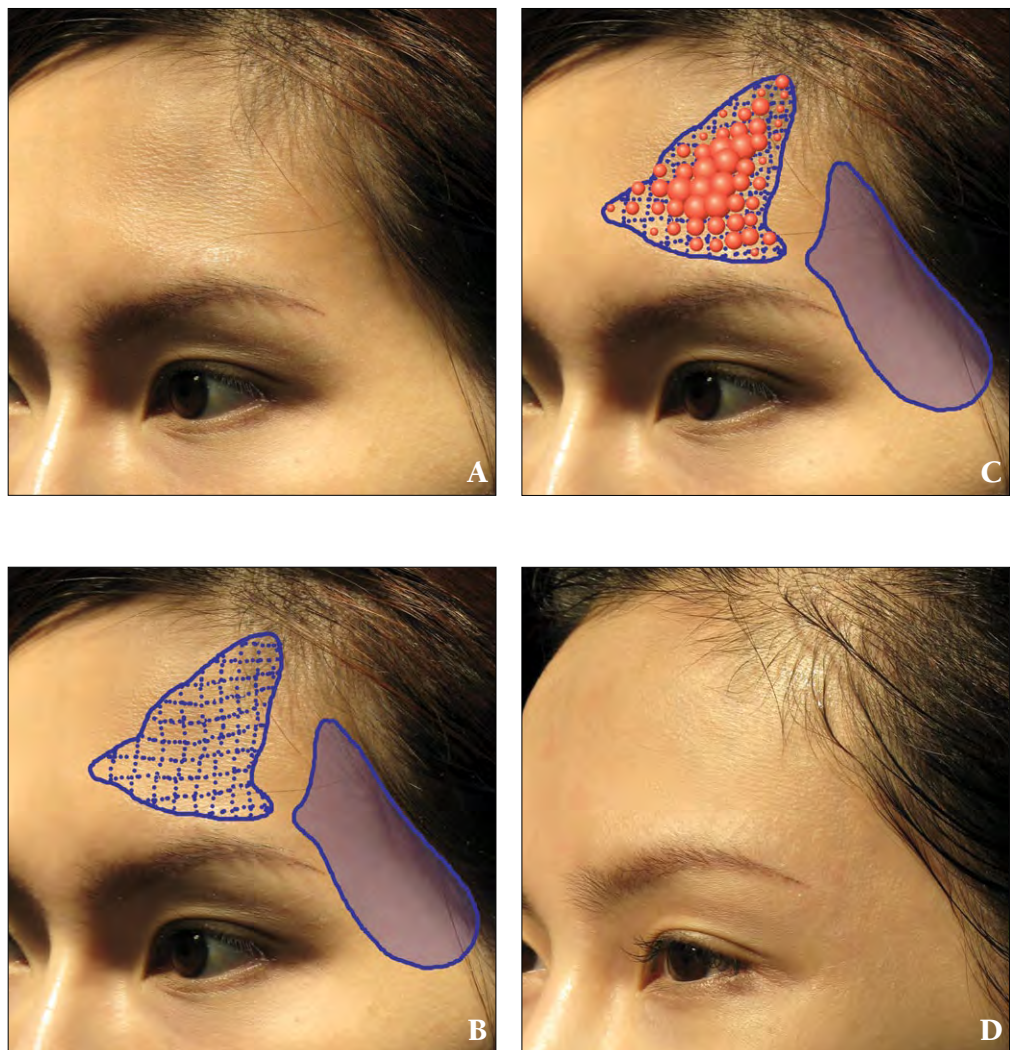
From L1 Cosmetic Surgery and Laser Center, Taipei, Taiwan. Dr. Chao is a member of the medical education faculty of sanofi-aventis. Dr. Chiu reports no conflicts of interest in relation to this article. Correspondence: Yen-Yu Chao, MD, L1 Cosmetic Surgery and Laser Center, 3/F, No. 8-1 Chin-Chen St, Taipei 105, Taiwan ROC (yateschao@yahoo.com).

FOREHEAD RECONTOURING WITH PLLA

distilled water and 1 mL of lidocaine 2% per vial). The total amount of PLLA suspension that typically is used for treatment of the forehead is 1 to 3.5 mL (half vial). One-milliliter single-use syringes with 1-inch, 25-gauge needles were used to administer the PLLA injections. Concave areas to be filled were marked out on the forehead. Before PLLA injections were administered, marked areas were viewed as pixilated figures. In different imaginary pixels of the marked area, there should be different gaps between the concave contour and the desired convexity (Figure 1B). This technique allows the injector to visualize the volume deficit of a 3-dimensional space and view posttreatment results that can be achieved when the space is filled with a liquid implant. Following the pixilated pattern, the implant can be divided into multiple areas of different volumes.

Using serial depot injections, small boluses of varying sizes were placed approximately 0.7 cm apart to accommodate the different gaps indicated by the pixels (Figures 1B and 1C). The treatment areas were molded immediately after injection to smooth out any lumps and to produce smooth feathered ends at the borders (Figure 1C). Only mild swelling was observed in the areas where PLLA had been deposited. Posttreatment care included the application of ice and gentle massage of the injection area for 3 days following the procedure if the patient noticed any lumps during self-examination. The patient returned for follow-up visits 1 week, 1 month, 2 months, and 6 months following the procedure. No posttreatment medication was administered. Positive clinical effects were observed 11 months after treatment (the final time point discussed in this article).

Figure 1. A 39-year-old woman prior to forehead recontouring with poly-L-lactic acid (PLLA) injections (A). Pixilated analysis of the concave target area of the forehead helped to determine the appropriate amount of injectable PLLA to be administered (B). The gaps between concave contours and the desired convexity may vary in different pixels (dotted line lattice). The temporal area (blue hue) could be filled with large boluses of injectable PLLA. Different-sized aliquots of PLLA can be placed in different pixels (C). The forehead contour was stabilized 6 months after treatment (D).



The forehead contour continued to improve in the first 5 months and gradually stabilized 6 months after the procedure (Figure 1D).

COMMENT

Volume loss is one of the most prevalent changes related to facial aging. Soft tissue replenishment of the forehead can improve brow elevation, create a more open appearance of the palpebral apertures, and restore a more relaxed countenance of the periorbital area^{3,4}; however, it also is important to address the bony components of the face for facial contouring and soft tissue suspension.⁵ In a study of skulls from 60 white patients utilizing 3-dimensional computed tomography, Shaw and Kahn⁵ found that facial aging was related to a decrease in the glabellar angle, along with recession of the nasion and supraorbital bar. These structural changes contributed to the appearance of brow ptosis and lateral orbital hooding.⁵ Our experience echoed the findings of this study. The forehead width narrows and temporal lines move inward with age; the frontal eminence also decreases in anterior projection and the frontal curve flattens. The orbital shape changes from round to rhombic with the lateral superciliary arches tilted downward. Therefore, rejuvenation of the forehead should always include the reshaping of frontal bony elements.

From an anatomical perspective, a tight frontalis muscle beneath the skin of the forehead and scanty galeal fat intervention may constitute difficulties for general filler volumization and provide little room to camouflage. There is limited discussion in the literature on topics related to forehead recontouring.^{3,4} Poly-L-lactic acid is a synthetic, biodegradable, biocompatible, and immunologically inert polymer⁶ that is used in a wide range of medical and surgical procedures.⁷⁻¹⁰ Injectable PLLA was approved for cosmetic use by the US Food and Drug Administration in 2009.¹¹ Compared with hyaluronic acid and calcium hydroxylapatite, the feasibility of supra-periosteal injection, the high spreadability after being mixed with water, and immobilization following water reabsorption make PLLA a suitable material for forehead reshaping.⁴ The similarity in texture of the induced neocollagen and the skin of the forehead is another advantage of using PLLA in forehead recontouring.

For the suprapariosteal placement of PLLA, pixilated serial puncture was found to be an easy, safe, and flexible technique that can be used for different types of forehead contour defects. Immediate molding and massaging after the injection was important. After the massage, the digitized aliquots fused together. Poly-L-lactic acid particles were estimated to be deposited in different amounts throughout the filled space after water

reabsorption and were shown to induce different amounts of collagen formation.

Our clinical experience with the off-label use of PLLA for the treatment of forehead recontouring in approximately 100 patients has led to satisfactory results (Figures 2 and 3). The recontouring effect 6 months after the injections had a positive correlation to the initial molds with smooth surfaces and good feathering ends. No papules, nodules, or other side effects were detected within 1 year posttreatment. Most of the patients received 1 treatment session on the forehead (Figure 3), while some received treatment of 2 to 3 sessions to achieve the desired level of correction (Figure 2). To prevent the risk for intravascular injection, reflux maneuvers were performed for each needle insertion. Keeping the supraorbital foramen pressed during injections was

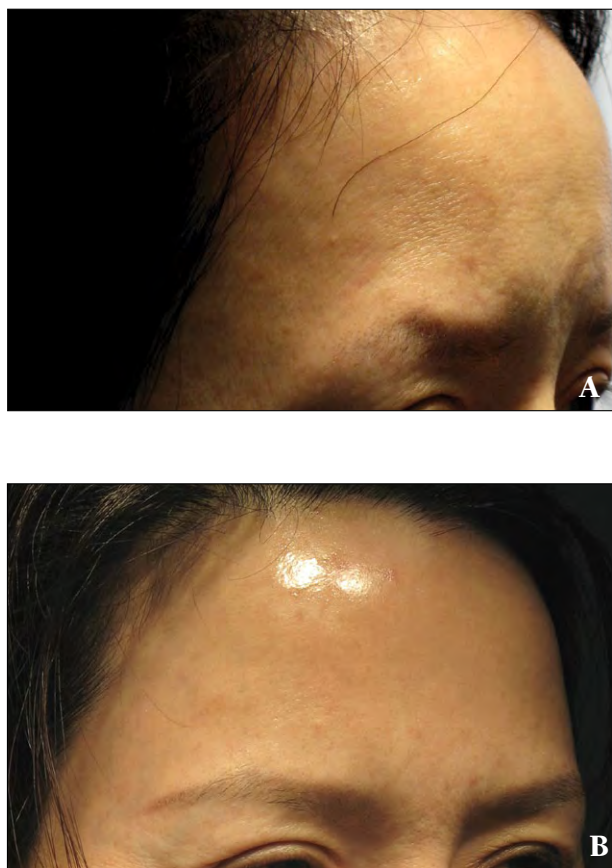


Figure 2. A 48-year-old woman prior to forehead recontouring with poly-L-lactic acid (PLLA) injections (A). The patient received treatment in 3 sections; each section was treated 1 month apart. Half vials of suspended PLLA were employed in each section of injection. Pixilated deposition of PLLA suspension in 0.05- to 0.2-mL aliquots was done using the serial puncture technique. Four months after the third section of treatment (6 months after initial treatment), improvement stabilized (B).

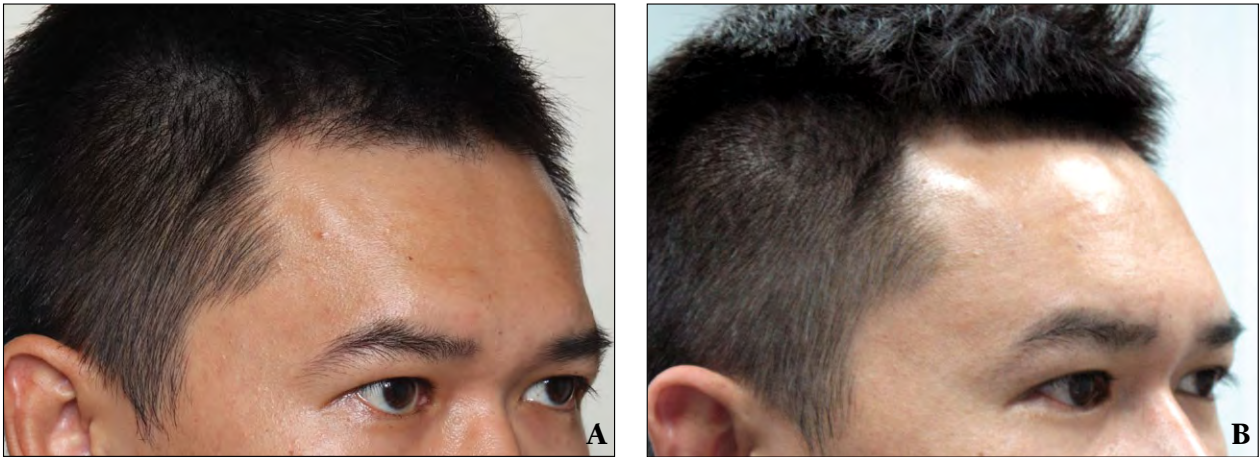

Figure 3. A 35-year-old man prior to forehead recontouring with poly-L-lactic acid (PLLA) injections (A). Only 1 section of PLLA injection was performed. Five milliliters of PLLA suspension (6 mL distilled water with 1 mL of lidocaine 2% [total 7 mL in 1 vial]) was injected into the forehead area using the pixilated serial puncture technique. The remaining 2 mL and another 2 vials of PLLA were injected into other facial areas. Improvement stabilized 7 months posttreatment (B).

recommended to prevent injury of the supraorbital nerve. The supratrochlear and supraorbital neurovascular bundles are located 17 to 22 mm lateral to the midline. Avoiding injection of the supraorbital notch or foramen and elevation of the skin when injecting the glabella region can limit the potential risk for nerve and vessel injury.^{3,4} Poly-L-lactic acid frequently is administered by bolus deposition above the periosteum. In general, small aliquots of 0.05 to 0.2 mL are safe with minimal risk for papule or nodule formation.¹²

CONCLUSION

The curvature of the forehead with convexity of the eyebrow and glabella is essential for an average and youthful-looking face. The pixilated serial puncture technique is suitable for forehead recontouring with injectable PLLA.

REFERENCES

1. Vleggaar D, Fitzgerald R. Dermatological implications of skeletal aging: a focus on suprapariosteal volumization for perioral rejuvenation. *J Drugs Dermatol*. 2008;7:209-220.
2. Donofrio LM. Fat distribution: a morphologic study of the aging face. *Dermatol Surg*. 2000;26:1107-1112.
3. Carruthers J, Carruthers A. Volumizing the glabella and forehead. *Dermatol Surg*. 2010;36(suppl 3):1905-1909.
4. Busso M, Howell DJ. Forehead recontouring using calcium hydroxylapatite. *Dermatol Surg*. 2010;36(suppl 3):1910-1913.
5. Shaw RB Jr, Kahn DM. Aging of the midface bony elements: a three-dimensional computed tomographic study. *Plast Reconstr Surg*. 2007;119:675-681; discussion 682-683.
6. Sculptra [package insert]. Bridgewater, NJ: sanofi-aventis US LLC; 2009.
7. Kronenthal RL. Biodegradable polymers in medicine and surgery. In: Kronenthal RL, Oser Z, Martin E, eds. *Polymers in Medicine and Surgery*. New York, NY: Plenum Publishing; 1975:119-135.
8. Kulkarni RK, Pani KC, Neuman C, et al. Poly-lactic acid for surgical implants. *Arch Surg*. 1966;93:839-843.
9. Moran JM, Pazzano D, Bonassar LJ. Characterization of poly-lactic acid-polyglycolic acid composites for cartilage tissue engineering. *Tissue Eng*. 2003;9:63-70.
10. Robert P, Mauduit J, Frank RM, et al. Biocompatibility and resorbability of a poly-lactic acid membrane for periodontal guided tissue regeneration. *Biomaterials*. 1993;14:353-358.
11. Sculptra Aesthetic P030050/S002. US Food and Drug Administration Web site. <http://www.fda.gov/MedicalDevices/ProductsandMedicalProcedures/DeviceApprovalsandClearances/Recently-ApprovedDevices/ucm176124.htm>. Updated August 6, 2009. Accessed December 6, 2011.
12. Vleggaar D. Soft-tissue augmentation and the role of poly-L-lactic acid. *Plast Reconstr Surg*. 2006;118(suppl 3):46S-54S. ■