

Use of a Bovine-Based Collagen Ointment in the Treatment of Plaque Psoriasis: An Open-Label, Pilot, Observational Clinical Study of 12 Patients

Montserrat Pérez, MD, PhD; Marta Alegre Fernández, MD, PhD; José M. de Moragas, MD, PhD; Beatriz de Moragas, RN

We describe the clinical results of psoriatic skin lesions in 12 adult patients with long-standing mild to moderate plaque psoriasis resistant to treatment with various topical and systemic therapies that were treated with a bovine-based collagen ointment (20% collagen powder of bovine origin in a petrolatum base) for 4 to 6 weeks. The product was applied once every evening, with enough to cover the lesion, and spread by gentle massage until the ointment was fully absorbed. One localized plaque per participant was selected for treatment. Response to treatment was assessed by changes in the signs and symptoms of plaque psoriasis in the target lesions (ie, erythema, desquamation, hyperkeratosis, itching, fissures/cracks) rated on a scale from 0 (not present) to 4 (severe/intense) as well as physician global assessment (PGA) with scores from 1 (unchanged/worse) to 6 (cleared [100% improvement]). The treatment group included 4 men and 8 women with a mean age (standard deviation [SD]) of 45.9 (12.6) years (range, 26–61 years). Psoriasis had been present for a mean (SD) of 20.7 (9.4) years. The mean duration of treatment was 40 days (range, 30–45 days). The median interquartile range PGA score of 1.50 (range, 0–2.75) at baseline increased to 4.5 (range, 4–5) at the end of treatment ($P=.002$). There was a statistically significant improvement of erythema (63.9%), desquamation (63.9%), hyperkeratosis (77.8%), itching (82.6%), and fissures/cracks (91.2%) at the end of the study compared to baseline values (all $P<.05$). The cosmetic characteristics (eg, appearance, texture, aroma, softness, odor, consistency, ease of application) of the product were well-accepted. No side effects or adverse reactions were observed. The

Drs. Pérez and de Moragas and Ms. de Moragas are from the Dermatologic Ambulatory Clinic de Moragas, Barcelona, Spain. Dr. Fernández is from the Hospital de la Santa Creu i Sant Pau, Universitat Autònoma de Barcelona.

The authors report no conflicts of interest in relation to this article.

Correspondence: Montserrat Pérez, MD, PhD, Dermatologic Ambulatory Clinic de Moragas, Balmes 195, E-08006 Barcelona, Spain (10630mpl@com.cat).

confirmation of these findings in a larger number of patients, particularly in controlled prospective studies, could represent an important advance in the therapeutic armamentarium for patients with plaque psoriasis given the excellent safety profile of this nonsteroidal collagen-based ointment.

Cosmet Dermatol. 2012;25:364-371.

Psoriasis is one of the most common chronic inflammatory disorders. Its cause is unknown, but data from a large number of studies indicate that the disease results from a complex and dynamic interplay between genetic and environmental factors that trigger an excessive inflammatory response in the skin.¹ Dendritic cells and effector T cells are central in the development of psoriatic lesions, and cytokines produced by these cells stimulate keratinocytes to proliferate and increase the migration of inflammatory cells into the skin, promoting epidermal hyperplasia and inflammation.^{2,3} A better understanding of psoriasis as a T cell-mediated autoimmune disease and of the pathophysiology of psoriasis plaques has led to the development of new systemic immunomodulatory therapies.^{4,5} Although these newer approaches have changed the ways psoriatic patients are managed, the majority of patients with psoriasis can be safely and effectively treated with topical agents.

Plaque psoriasis is the most common form of the disease, affecting approximately 80% to 90% of patients; among patients with plaque psoriasis, the majority (80%) have mild to moderate symptoms. Topical therapies form the cornerstone in the management of mild to moderate psoriasis^{6,7} and also are used as adjunctives to systemic therapy in patients with moderate and severe symptoms. Over the last decade, topical treatment of psoriasis has evolved from the age-old application of tar and dithranol to the more acceptable and efficacious options of topical corticosteroids, retinoids, and vitamin D analogues, with the advent of a wide range of vehicles and delivery modes.^{8,9} However, treatment should be tailored to meet individual patient needs, which vary depending on body location and characteristics of the psoriasis being treated, including lesion thickness, degree of erythema, amount of scaling and pruritus, and patient preferences.¹⁰ Furthermore, when choosing a treatment strategy, the clinician should be aware that the ultimate goal of therapy is to gain rapid control of the disease; decrease erythema, scaling, and duration of individual plaques; maintain long-term remission and avoid relapse; avoid adverse effects; and improve the patient's quality of life.¹¹ For practical considerations, there is no single ideal topical

agent or sequence of agents that meets all these expectations; therefore, there is a need for new highly effective and safe therapy options for topical use.

Clinical observation of a dramatic improvement of plaque psoriasis lesions with the use of a bovine-based collagen ointment prompted us to perform an open-label, pilot, observational study to evaluate the clinical response of patients with mild to moderate plaque psoriasis treated with this bovine-based collagen product.

METHODS

The study group consisted of 12 consecutive plaque psoriasis patients attending control visits at a private dermatology clinic in Barcelona, Spain. Inclusion criteria were mild to moderate plaque-type psoriasis, long-standing disease, and skin lesions that were difficult to control despite treatment with various systemic and topical therapies. All participants were fully aware of the investigational nature of the topical product and provided written informed consent to participate in the study.

Participants were treated with a new formulation of 20% bovine-based collagen powder in a petrolatum base and were instructed to apply the product once every evening, to use enough to cover the lesion, and to spread the ointment by gentle massage until it was fully absorbed. One localized plaque per participant was selected for treatment. The duration of treatment was 4 to 6 weeks. Participants were directed to stop treatment and contact the investigator if any adverse reactions or side effects occurred.

Treatment response was assessed by observing changes in the signs and symptoms of plaque psoriasis in the target lesions (ie, erythema, desquamation, hyperkeratosis, itching, fissures/cracks). Symptoms were rated on a scale of 0 to 4 (0=not present; 1=very mild; 2=mild; 3=moderate; 4=severe/intense) and according to the physician global assessment (PGA),¹² with scores ranging from 1 to 6 (1=unchanged/worse; 2=slight [1%–24% improvement]; 3=fair [25%–49% improvement]; 4=good [50%–74% improvement]; 5=excellent [75%–99% improvement]; 6=cleared [100% improvement]). Participants were assessed monthly as well as at the end of the observational period, which was approximately

6 weeks unless full improvement was observed before. All clinical examinations were conducted by one of the authors (M.P.). Photographs of the treated lesions also were analyzed before and after the treatment period.

Statistical Analysis

Data analysis was conducted using SPSS statistics software for Windows (Version 9.0). The Kolmogorov-Smirnov test was used to assess normal distribution of data. Differences in the signs and symptoms of the study lesions as well as changes in PGA scores before and after at least 4 weeks of treatment with the bovine-based collagen ointment were analyzed with the Wilcoxon signed rank test. Results are expressed as mean (standard deviation [SD]) for normally distributed variables and as median and interquartile range (25th–75th percentiles) for variables whose distribution departed from normality. $P < .05$ was considered statistically significant.

RESULTS

The study group included 4 men and 8 women, with a mean age (SD) of 45.9 (12.6) years (range 26–61 years). Psoriasis had been present for a mean (SD) of 20.7 (9.4) years (range, 7–36 years). All participants presented with mild to moderate plaque psoriasis; none had psoriatic arthritis. Psoriasis triggers among the treatment group included recurrent pharyngotonsillitis in 2 participants and emotional stress in 1 participant. Demographic and clinical data are summarized in Table 1. The mean duration of treatment was 40 days (range, 30–45 days).

With the use of the bovine-based collagen ointment, all of the participants reported a dramatic increase in the hydration of the treated lesions; a decrease in the flare and burning sensation; disappearance of pruritus; and a marked improvement in the erythematous, desquamative, and hyperkeratotic components of the lesions. In most of the participants, clinical improvement became evident after a few days of treatment, particularly the alleviation of itching, which practically disappeared immediately after the first application of the product. Clinical changes associated with the use of the topical treatment are detailed in Table 1. None of the participants experienced worsening of the psoriatic lesions. Figures 1 to 4 illustrate skin changes before and after treatment in 4 participants.

As shown in Table 2, signs and symptoms of the treated lesions changed significantly (all $P < .05$), with marked improvements in erythema (63.9%), desquamation (63.9%), hyperkeratosis (77.8%), itching (82.6%), and fissures/cracks (91.2%) at the end of the study compared to baseline values (Figure 5). The median interquartile range PGA score increased from 1.50 (range, 0–2.75) at baseline to 4.5 (range, 4–5) at the end of treatment ($P = .002$),

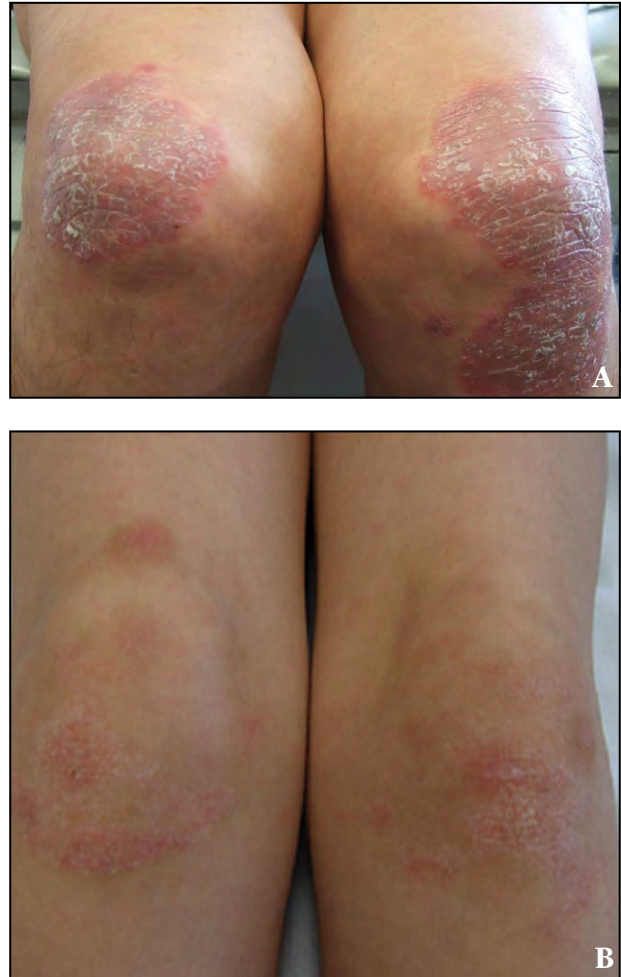

Figure 1. Participant 1 with erythematous and desquamative plaques on both knees that caused intense itching (A). Following treatment with a bovine-based collagen ointment, desquamation and itching disappeared (B).

with improvement rates ranging from 50% to 74% (score 4) and 75% to 99% (score 5) (Figure 6).

The cosmetic characteristics (eg, appearance, texture, aroma, softness, odor, consistency, ease of application) of the bovine-based collagen ointment were well-accepted by all participants. Moreover, all participants were satisfied with this new treatment, which largely contributed to a reduction in the use of complementary treatments (eg, hydration creams), reducing the standard monthly expenses of this kind of product. At the end of the study, several participants decided to continue use of the bovine-based collagen ointment, and further improvement of the lesions was noted.

Tolerability of the bovine-based collagen ointment was excellent and none of the participants reported any adverse events.

TABLE 1

Clinical Features of Participants Treated With a Bovine-Based Collagen Ointment

Participant No.	Age, y	Sex	Age at Onset, y	Fitzpatrick Skin Type	Clinical Data	Predominant Location of Lesions	Prior Treatment	Results of Treatment With Study Ointment
1	26	F	18	III	Large erythematous scaly plaques, some highly hyperkeratotic plaques	Elbows, knees, upper and lower extremities	Methotrexate, cyclosporine, isotretinoin, PUVA, multiple topical treatments	Almost complete disappearance of erythema, marked skin comfort, less desquamation and hyperkeratosis
2	50	F	20	III	Metabolic syndrome	Generalized psoriasis	No systemic treatments	Marked improvement, disappearance of itching
3	46	M	39	III	Large psoriatic plaques in extension areas with marked hyperkeratosis	Elbows, knees, central part of the chest	No systemic treatments	Outstanding improvement of hyperkeratosis
4	44	M	17	III	Plaques limited to typical zones with marked hyperkeratosis	Elbows, knees	No systemic treatments, poor adherence	Marked improvement of hyperkeratosis
5	42	M	24	III	Medium-sized erythematous and desquamative plaques	Upper and lower extremities	Numerous topical therapies, no systemic treatments	Marked improvement of erythema and itching
6	60	M	30	III	Well-circumscribed hyperkeratotic plaques	Elbows, knees	Topical corticosteroids, poor adherence	Excellent results with clearance of erythema, desquamation, and hyperkeratosis; disappearance of itching

Table continued on page 368

TABLE 1 (CONTINUED)

Participant No.	Age, y	Sex	Age at Onset, y	Fitzpatrick Skin Type	Clinical Data	Predominant Location of Lesions	Prior Treatment	Results of Treatment With Study Ointment
7	56	F	35	III	Fissures and cracks on hyperkeratotic lesions	Soles	Topical corticosteroids	Disappearance of fissures/cracks and itching
8	29	F	17	III	Erythematous and desquamative plaques of small size	Upper extremities	Hydration creams	Improvement of desquamation, erythema, and itching
9	51	F	18	III	Small, confluent, erythematous and desquamative plaques	Whole tegument	Methotrexate, cyclosporine A, PUVA, multiple topical agents	Improvement of erythema and desquamation, relief of itching
10	61	F	25	III	Painful fissures/cracks	Fingertips	Topical corticosteroids	Excellent resolution of fissures/cracks, disappearance of symptoms
11	58	F	45	III	Hyperkeratosis with severe itching	Palms	Oral isotretinoin	Disappearance of itching, improvement of hyperkeratosis
12	28	F	15	III	Erythematous and desquamative plaques of small diameter with peripheral hyperkeratosis	Trunk, abdomen	Topical corticosteroids, oral antimicrobials	Clearance of lesions, disappearance of itching

Abbreviations: F, female; PUVA, psoralen plus UVA; M, male.

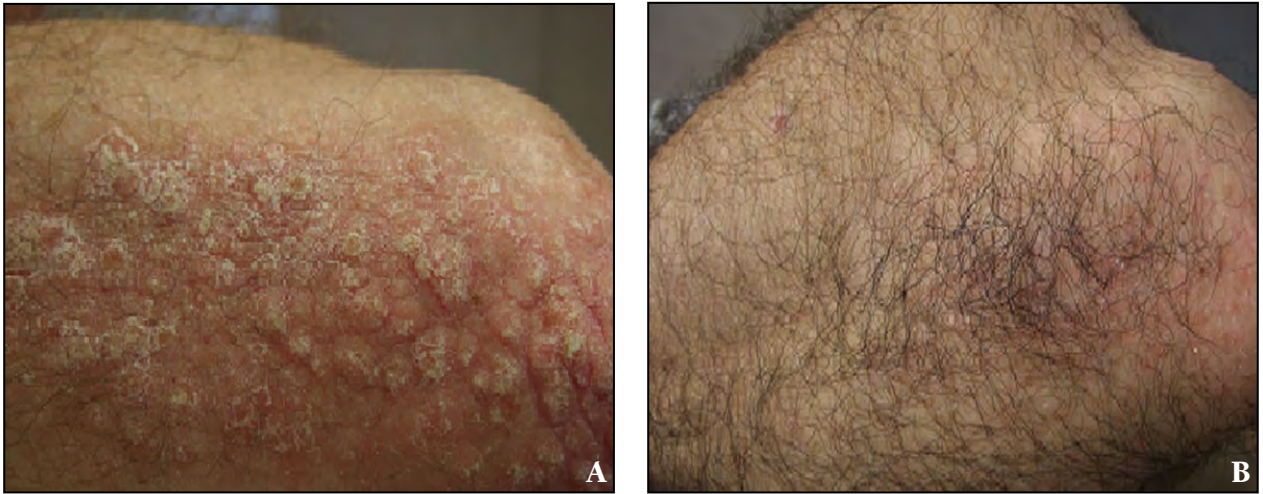


Figure 2. Participant 6 with hyperkeratotic and highly pruriginous plaques on the elbow (A). Following treatment with a bovine-based collagen ointment, hyperkeratosis and itching disappeared with restoration of hair growth (B).

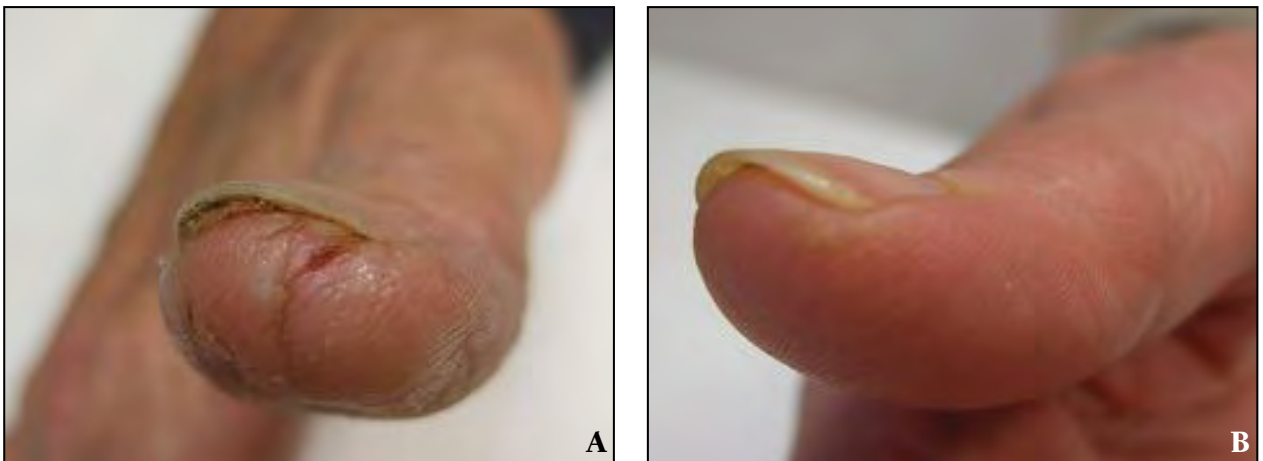


Figure 3. Participant 10 with painful fissures/cracks on the tip of the thumb (A). The lesions resolved after treatment with a bovine-based collagen ointment (B).

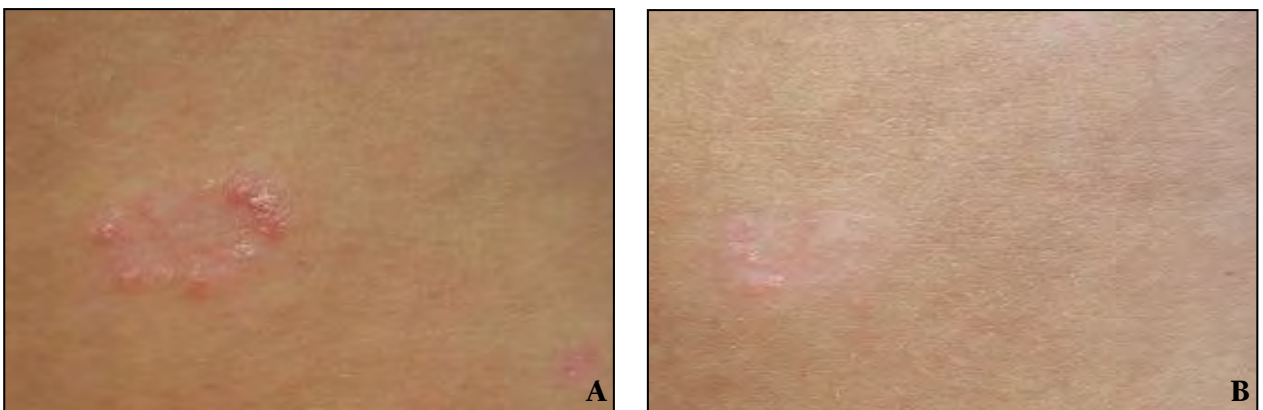


Figure 4. Participant 12 with an erythematous and desquamative plaque with peripheral hyperkeratosis on the anterior part of the chest (A). Treatment with a bovine-based collagen ointment led to clearance of clinical signs (B).

TABLE 2

Changes in the Signs and Symptoms of the Target Lesions After Treatment With the Bovine-Based Collagen Ointment^a

Characteristic	Topical Treatment With the Study Ointment		
	Baseline Score, median (IQR)	End of Study Score, median (IQR)	P Value ^b
Erythema	3 (3–30)	1 (0–2)	.003
Desquamation	3.5 (2.25–4)	1 (0.25–2)	.002
Hyperkeratosis	3 (3–3.75)	0 (0–1.75)	.002
Itching	3 (2.25–4)	0 (0–1)	.002
Fissures/cracks	0 (0–1.75)	0 (0–0)	.039

Abbreviation: IQR, interquartile range (25th–75th percentiles).
^aAssessed on a 5-point scale (0 = not present; 4 = severe/intense).
^bWilcoxon signed rank test.

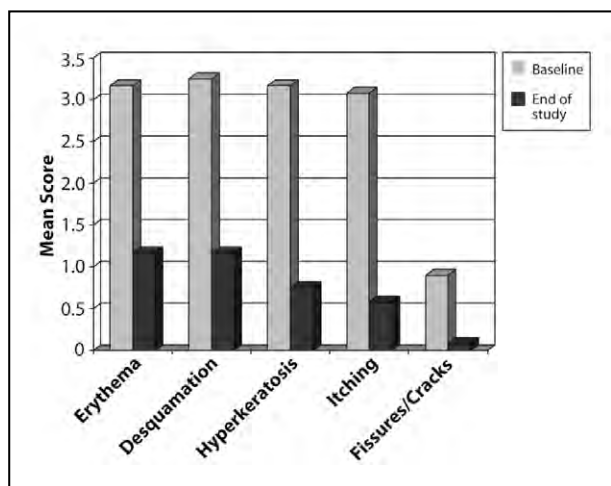


Figure 5. Comparison of the mean scores of psoriatic signs and symptoms before and after treatment with a bovine-based collagen ointment. Symptoms were rated on a scale of 0 (not present) to 4 (severe/intense).

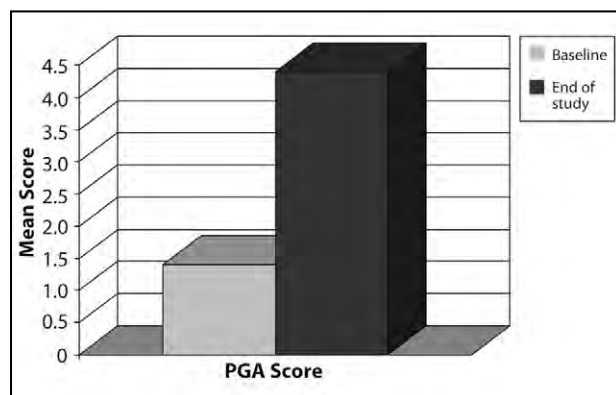

Figure 6. Changes in the mean physician global assessment (PGA) score after treatment with a bovine-based collagen ointment. Scores ranged from 1 (unchanged/worse) to 6 (cleared [100% improvement]).

COMMENT

In our study of 12 plaque psoriasis patients with long-standing psoriasis in which different therapeutic modalities including systemic medications and multiple topical treatments had not been completely effective, daily application of a bovine-based collagen ointment for 4 to 6 weeks was associated with a marked and statistically

significant ($P < .05$) improvement of the psoriatic lesions with a reduction of erythema, desquamation, hyperkeratosis, and fissures/cracks, as well as disappearance of itching. All participants reported increased hydration and softening of the skin as well as amelioration of scaling; they also reported satisfaction with the treatment results. Along with improvement of the clinical signs and

symptoms of plaque psoriasis, a statistically significant increase in the PGA score also was observed ($P=.002$).

Although the precise mechanism of action of the bovine-based collagen ointment is still unknown, improvement was observed in our study group with complete clearance in some participants achieved by once-daily application of the study product without any adverse effects. It has been shown that an acidic mucopolysaccharide complex obtained from bovine tracheal cartilage that contains glycosaminoglycans, including chondroitin sulfate, has immunoregulatory effects and plays a major role in wound healing by promoting the growth of fibroblasts and keratinocytes.^{13,14} Bovine collagen has a beneficial and healing effect on the extracellular matrix that results in positive benefits for patients with a variety of conditions, including difficult-to-heal wounds and psoriasis.¹⁵ Restoration of chondroitin sulfate alterations in the papillary dermis and basal keratinocytes¹⁶ may be consistent with the favorable effect of the bovine-based collagen powder in the treatment of psoriasis.

Our treatment group included participants with a mean 20-year history of plaque psoriasis; shortly after topical treatment with the study ointment, their lesions dramatically improved in appearance. Moreover, participants who decided to continue treatment after the study period also experienced further clinical improvement of psoriatic plaques. To our knowledge, this study is the first reported finding of successful bovine-based collagen topical therapy in psoriasis. Our preliminary observation has the clear limit of the small sample of patients.

Given the potential interest in bovine-based collagen ointment for the topical treatment of plaque psoriasis, controlled studies (eg, using the vehicle as a control) in patients with psoriasis should be performed to confirm the encouraging results obtained in this pilot study.

Acknowledgment—We thank Marta Pulido, MD, Barcelona, Spain, for editing the manuscript and providing editorial assistance.

REFERENCES

1. Roberson ED, Bowcock AM. Psoriasis genetics: breaking the barrier. *Trends Genet.* 2010;26:415-423.
2. Monteleone G, Pallone F, MacDonald TT, et al. Psoriasis: from pathogenesis to novel therapeutic approaches. *Clin Sci (Lond).* 2011;120:1-11.
3. Chamian F, Krueger JG. Psoriasis vulgaris: an interplay of T lymphocytes, dendritic cells, and inflammatory cytokines in pathogenesis. *Curr Opin Rheumatol.* 2004;16:331-337.
4. Ferrándiz C, Carrascosa JM, Boada A. A new era in the management of psoriasis? the biologics: facts and controversies. *Clin Dermatol.* 2010;28:81-87.
5. Boehncke WH, Prinz J, Gottlieb AB. **Biologic therapies for psoriasis. a systematic review.** *J Rheumatol.* 2006;33:1447-1451.
6. Mason AR, Mason J, Cork M, et al. Topical treatments for chronic plaque psoriasis. *Cochrane Database Syst Rev.* 2009;(2): CD005028.
7. Laws PM, Young HS. Topical treatment of psoriasis. *Expert Opin Pharmacother.* 2010;11:1999-2009.
8. Bagel J. Topical therapies for the treatment of plaque psoriasis. *Cutis.* 2009;84(suppl 4):3-13.
9. Kamili QU, Menter A. Topical treatment of psoriasis. *Curr Probl Dermatol.* 2009;38:37-58.
10. Zeichner JA, Lebwohl MG, Menter A, et al. Optimizing topical therapies for treating psoriasis: a consensus conference. *Cutis.* 2010;86(suppl 3):5-31; quiz 32.
11. Menter A, Korman NJ, Elmets CA, et al. Guidelines of care for the management of psoriasis and psoriatic arthritis. section 3. guidelines of care for the management and treatment of psoriasis with topical therapies. *J Am Acad Dermatol.* 2009;60:643-659.
12. Feldman SR, Krueger GG. Psoriasis assessment tools in clinical trials. *Ann Rheum Dis.* 2005;64(suppl 2):ii65-ii68; discussion ii69-ii73.
13. King S. Catrix: an easy-to-use collagen treatment for wound healing. *Br J Commun Nurs.* 2005;10:S31-S34.
14. Rosen J, Sherman WT, Prudden JF, et al. Immunoregulatory effects of catrix. *J Biol Response Mod.* 1988;7:498-512.
15. Prudden JF, Balassa LL. The biological activity of bovine cartilage preparations. clinical demonstration of their potent anti-inflammatory capacity with supplementary notes on certain relevant fundamental supportive studies. *Semin Arthritis Rheum.* 1974;3:287-321.
16. Smetsers TF, van de Westerlo EM, ten Dam GB, et al. Human single-chain antibodies reactive with native chondroitin sulfate detect chondroitin sulfate alterations in melanoma and psoriasis. *J Invest Dermatol.* 2004;122:707-716. ■