

What's Your Diagnosis?

Acute Upper Abdominal Pain in Early Pregnancy

Richard Temple, MD; and Michael Rosedale, DO

What could be the cause of abdominal pain in a 32-year-old pregnant woman?

A 32-year-old G1P0 woman at 7 4/7 weeks' gestation (intrauterine pregnancy confirmed by ultrasound) with a history of hypertension and anxiety presented to the emergency department reporting right upper quadrant and right flank pain. The patient did not report taking any medications. Her symptoms had begun about 6 hours prior to presentation. She did not report fever, chills, nausea, vomiting, anorexia, or urinary or bowel symptoms. She was afebrile, and her initial blood pressure was 174/84 mm Hg, but within an hour of presentation had decreased to 137/82 mm Hg.

On exam she was in moderate-to-severe discomfort. She was tender to palpation in the right flank as well as the right upper quadrant and had a positive Murphy sign. Her white blood cell (WBC) count was 18,800/ μ L, hemoglobin and hematocrit were normal, liver function tests were within normal limits, and sodium was 133 mmol/L; oth-

erwise, electrolytes were normal. The urinalysis showed a specific gravity of 1.022 with 3 red blood cells per high powered field, but was otherwise normal. A right upper quadrant ultrasound showed a normal gallbladder without cholelithiasis. Subsequently, a magnetic resonance imaging (MRI) of the abdomen was obtained (Figure 1).

- What is your diagnosis?
- How would you treat this patient?

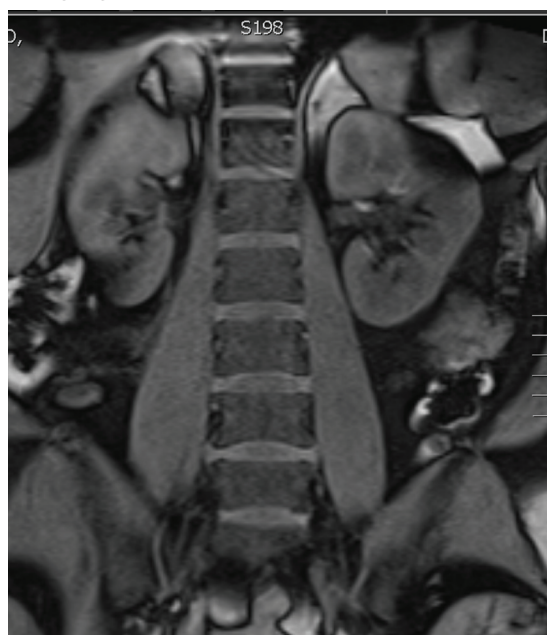
OUR TREATMENT

An MRI of the abdomen revealed a right adrenal hematoma (Figure 2). This diagnosis was made after common causes of the right upper quadrant and right flank pain were excluded and was confirmed with an MRI of the abdomen.

Discussion

Common causes of right flank and right upper quadrant pain include urolithiasis, pyelonephritis, and

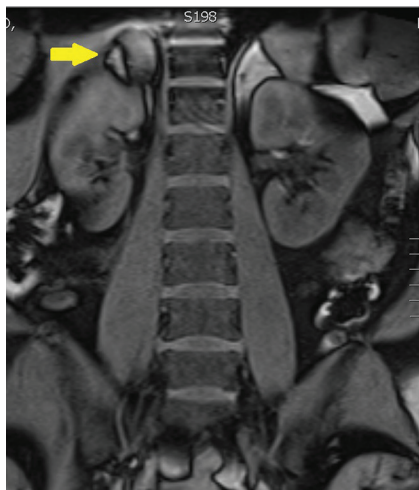
Figure 1. Abdominal Magnetic Resonance Imaging—Coronal View



acute cholecystitis (Table). Patients with urolithiasis will typically present with sudden onset of colicky flank pain, which may radiate to the inguinal region, with or without nausea and vomiting.^{1,2} Microhematuria may be absent in as many as 10% to 20% of patients.² Computed tomography is nearly 97% sensitive and 96% specific for urolithiasis.² Although only 37% to 64% sensitive in detecting urolithiasis, abdominal

Dr. Temple is a faculty physician at the Naval Hospital Camp Lejeune Family Medicine Residency Program in North Carolina. **Dr. Rosedale** is an attending physician at Naval Hospital Lemoore in California. Previously, he was a resident physician at Naval Hospital Camp Lejeune Family Medicine Residency Program.

Figure 2. Abdominal Magnetic Resonance Imaging Showing Abnormality—Coronal View



ultrasound is 85% to 94% specific for detecting hydronephrosis.²

Symptoms of pyelonephritis range from mild to severe costovertebral angle pain with or without fever and/or lower urinary tract symptoms to sepsis.³ Urinalysis typically shows leukocyte esterase (72%-97% sensitive, 41%-86% specific for culture-confirmed urinary tract infection) and microscopic pyuria (90%-96% sensitive, 47%-50% specific for culture-confirmed urinary tract infection).^{3,4} Urine culture will reveal 10⁵ colony-forming units in 95% of patients with acute uncomplicated pyelonephritis.³ Imaging is typically reserved for atypical presentations or in cases of nonresolution of symptoms despite treatment in order to rule out structural anomalies, an obstructive process, or abscess formation.³

Acute cholecystitis is suggested by right upper quadrant pain, often following a meal. Symptoms include fever, leukocytosis, and an elevated serum bilirubin level.⁵ Ultrasound findings of acute cholecystitis are gallbladder wall thickening, pericho-

Table. Selected Differential Diagnosis of Acute Upper Abdominal/Flank Pain

Condition	Characteristics
Spontaneous adrenal hemorrhage	Abdominal and/or flank pain; diagnosis requires high index of suspicion and radiologic study; abdominal magnetic resonance imaging most sensitive for detecting adrenal anomalies
Perinephric abscess	Abdominal and/or flank pain with fever; as many as 30% have a normal urinalysis, and 40% have sterile urine; diagnosis requires renal imaging (CT scan or ultrasound)
Urolithiasis	Colicky flank pain that may radiate to the groin; hematuria on urinalysis (absent in 10-20% of cases); noncontrast CT scan of urogenital tract both sensitive (97%) and specific (96%)
Pyelonephritis	Fever, flank, and/or abdominal pain, lower urinary tract symptoms; urinalysis typically contains leukocyte esterase and microscopic pyuria; imaging reserved for atypical or non-resolving symptoms
Acute cholecystitis	Fever, right upper quadrant pain, leukocytosis, and jaundice; right upper quadrant ultrasound has a 92% to 95% positive predictive value

CT = computed tomography.

lecystic fluid, or sonographic Murphy sign.⁶ Ultrasound has a sensitivity of 81% and a specificity of 83% for detecting acute cholecystitis, whereas hepatobiliary iminodiacetic acid scan (cholescintigraphy) is 96% sensitive and 90% specific and is used in cases where ultrasound is indeterminate.⁶

Spontaneous adrenal hemorrhage (SAH) typically presents with symptoms of upper abdominal pain and/or flank pain. If hemorrhage is significant, hypotension and a drop in hematocrit may occur. Alternatively, if SAH is bilateral and results in a deficiency of adrenal hormones, hypotension may be secondary to adrenal insufficiency. Due to its ready availability, most SAHs are diagnosed by CT scan ordered for alternate reasons.⁷

In the pregnant patient, to avoid

exposing the developing fetus to radiation, ultrasound is typically the first imaging modality to investigate right upper quadrant or flank pain. However, ultrasound is less sensitive for evaluating anomalies of the adrenal gland.⁸ An MRI is the most accurate imaging modality for diagnosing adrenal hemorrhage and avoids exposing the developing fetus to radiation.⁹ In this case, the absence of an etiology of the patient's symptoms on right upper quadrant ultrasound led to further evaluation, with abdominal MRI revealing the diagnosis.

In a review of 141 cases of adrenal hemorrhage at the Mayo Clinic in Rochester, Minnesota, 16 patients had a spontaneous adrenal hemorrhage, which presented with severe abdominal and flank pain of sudden onset.⁷

Seven of these patients required surgery to control the bleeding.⁷ None of the 13 patients with a functioning contralateral adrenal gland required adrenal replacement therapy.⁷ Gavrilova-Jordan and colleagues reported a case of a spontaneous unilateral adrenal hemorrhage in the third trimester of pregnancy that was managed conservatively with favorable outcomes.¹⁰ Potential causes of spontaneous adrenal hemorrhage include:

- Antiphospholipid antibody syndrome
- Heparin-induced thrombocytopenia
- Trauma
- Physiologic stress (eg, sepsis)
- Adrenal mass (pheochromocytoma, angiomyolipoma, or metastatic cancer).^{6,11}

Case Outcome

Initial right upper quadrant ultrasound in this patient revealed a normal gallbladder and a small amount of perinephric fluid surrounding the right kidney. On the night of admission she experienced an elevated temperature of 101.9°F. Due to the fever and leukocytosis, she was initiated on antibiotics (ampicillin-sulbactam 3 g IV every 6 hours) covering a urinary source. On hospital day 2, right lower quadrant and right upper quadrant ultrasounds were performed, revealing decreased fluid surrounding her right kidney

and without evidence of appendicitis. Due to persistent leukocytosis (WBC count peaked at 26,400/μL), essentially normal urinalysis, and negative urine culture, an abdominal MRI was obtained to evaluate for a perinephric abscess. The MRI revealed the spontaneous adrenal hemorrhage.

The patient was observed as an inpatient for the following 48 hours. Her electrolytes remained normal and hemoglobin decreased to 9.5 g/dL. She remained hemodynamically stable. Serum cortisol and angiotensin levels were normal, antibiotics were discontinued, and the patient was discharged to outpatient follow-up.

A repeat MRI of the abdomen obtained 6 weeks later revealed a resolving right adrenal hematoma. At 39 weeks' gestation, she delivered a vigorous female infant weighing 3,200 g (7 lb 1 oz) with an Apgar score at birth of 8/9. ●

Author disclosures

The authors report no actual or potential conflicts of interest with regard to this article.

Disclaimer

The opinions expressed herein are those of the authors and do not necessarily reflect those of Federal Practitioner, Frontline Medical Communications Inc., the U.S. Government, or any of its agencies. This article may discuss un-

labeled or investigational use of certain drugs. Please review complete prescribing information for specific drugs or drug combinations—including indications, contraindications, warnings, and adverse effects—before administering pharmacologic therapy to patients.

REFERENCES

1. Wasserstein AG. Nephrolithiasis. *Am J Kidney Dis.* 2005;45(2):422-428.
2. Ban KM, Easter JS. Selected urologic problems. In: Marx JA, Hockberger RS, Walls, RM, eds. *Rosen's Emergency Medicine: Concepts and Clinical Practice.* 7th ed. Philadelphia, PA: Elsevier; 2010:1297-1324.
3. Colgan R, Williams M, Johnson JR. Diagnosis and treatment of acute pyelonephritis in women. *Am Fam Physician.* 2011;84(5):519-526.
4. Simerville JA, Maxted WC, Pahira JJ. Urinalysis: A comprehensive review. *Am Fam Physician.* 2005;71(6):1153-1162.
5. Friedman LS. Liver, biliary tract & pancreas disorders. In: McPhee SJ, Papadakis MA, eds. *Current Medical Diagnosis and Treatment,* 2012. 51st ed. New York, NY: Lange Medical Books/McGraw-Hill; 2012:644-698.
6. Kiewiet JJ, Leeuwenburgh MM, Bipat S, Bossuyt PM, Stoker J, Boermeester MA. A systematic review and meta-analysis of diagnostic performance of imaging in acute cholecystitis. *Radiology.* 2012;264(3):708-720.
7. Vella A, Nippoldt TB, Morris JC 3rd. Adrenal hemorrhage: A 25-year experience at the Mayo Clinic. *Mayo Clin Proc.* 2001;76(2):161-168.
8. Kawashima A, Sandler CM, Ernst RD, et al. Imaging of nontraumatic hemorrhage of the adrenal gland. *Radiographics.* 1999;19(4):949-963.
9. Hoeffel C, Legmann P, Luton JP, Chapuis Y, Fayet-Bonnin P. Spontaneous unilateral adrenal hemorrhage: Computerized tomography and magnetic resonance imaging findings in 8 cases. *J Urol.* 1995;154(5):1647-1651.
10. Gavrilova-Jordan L, Edmister WB, Farrell MA, Watson WJ. Spontaneous adrenal hemorrhage during pregnancy: A review of the literature and a case report of successful conservative management. *Obstet Gynecol Surv.* 2005;60(3):191-195.
11. Marti JL, Millet J, Sosa JA, Roman SA, Carling T, Udelsman R. Spontaneous adrenal hemorrhage with associated masses: Etiology and management in 6 cases and a review of 133 reported cases. *World J Surg.* 2012;36(1):75-82.