

Ipsilateral Intertrochanteric and Pipkin Fractures: An Unusual Case

Mustafa H. Khan, MD, Vonda J. Wright, MD, and Michael J. Prayson, MD

Fracture-dislocation of the femoral head most commonly results from high-energy trauma, such as that sustained in falls and motor vehicle accidents. This injury may be associated with ipsilateral femoral neck and acetabular fractures. However, femoral head fracture-dislocation with an ipsilateral intertrochanteric fracture is an extremely rare injury, with only 2 previous cases reported in the literature.^{1,2}

In the present report, we describe a case of this unusual fracture pattern and briefly review the relevant literature, anatomy, and treatment options.

CASE REPORT

A man in his early 40s sustained injuries in a car accident. At presentation he was awake and alert and complained of pain in the chest, right hip, and right leg. The evaluation and treatment of his orthopedic injuries are described in this case report.

Orthopedic evaluation revealed a right posterior hip dislocation with an associated femoral head fracture, a right femoral intertrochanteric fracture, right superior and inferior pelvic rami fractures (Figure 1), and an open type IIIA right tibia fracture. The patient was taken emergently to the operating room. Irrigation, débridement, and then intramedullary nailing of the open tibia fracture were performed. Next, closed reduction of the right hip was done using intraoperative fluoroscopy, which showed that the femoral head fracture was reduced. Last, a cephalomedullary Gamma nail (Stryker Orthopaedics, Kalamazoo, Mich) was used to stabilize the intertrochanteric fracture. The patient was successfully extubated and taken to the postanesthesia care unit.

A postoperative computed tomography (CT) scan obtained to assess hip reduction showed that the femoral head fracture fragment was flipped 180° in the acetabulum (Figure 2). The patient was made non-weight-bearing and was placed in Buck's traction in anticipation of definitive open reduction

Dr. Khan is Clinical Instructor, and Dr. Wright is Assistant Professor, Department of Orthopedic Surgery, University of Pittsburgh Medical Center, Pittsburgh, Pennsylvania.

Dr. Prayson is Associate Professor, Department of Orthopaedic Surgery, Wright State University School of Medicine, Dayton, Ohio.

Requests for reprints: Mustafa H. Khan, MD, 5471 Fifth Avenue, Suite 1010, Pittsburgh, PA 15213 (tel, 412-605-3262; fax, 412-687-3724; e-mail, kxanm2@upmc.edu).

Am J Orthop. 2007;36(4):E53-E55. Copyright 2007, Quadrant HealthCom Inc.

and internal fixation (ORIF). He was returned to the operating room on postoperative day 5. The anterior approach was used to remove several small loose osteochondral fragments from the hip, and the femoral head fracture fragment was reduced and fixed with 2 countersunk 4.0-mm cancellous screws. Intraoperative fluoroscopy showed that the hip had full, smooth range of motion without fracture displacement. Postoperative x-rays showed successful reduction and fixation of the fracture (Figure 3).

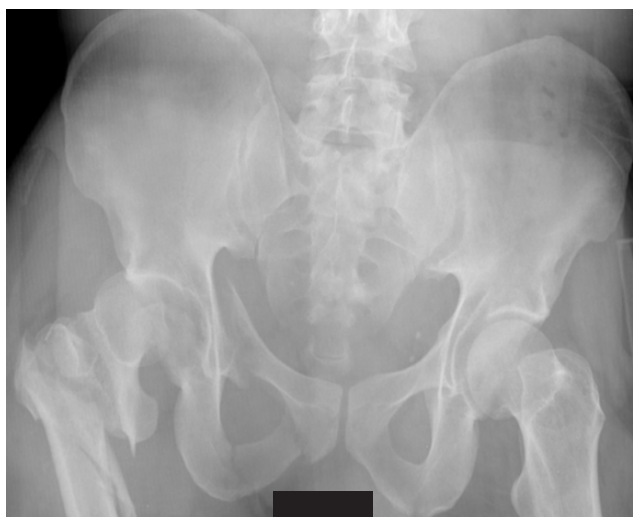

Figure 1. Anteroposterior pelvis plain film shows right femoral head fracture-dislocation with intertrochanteric femur fracture as well as right superior and inferior pelvic rami fractures.

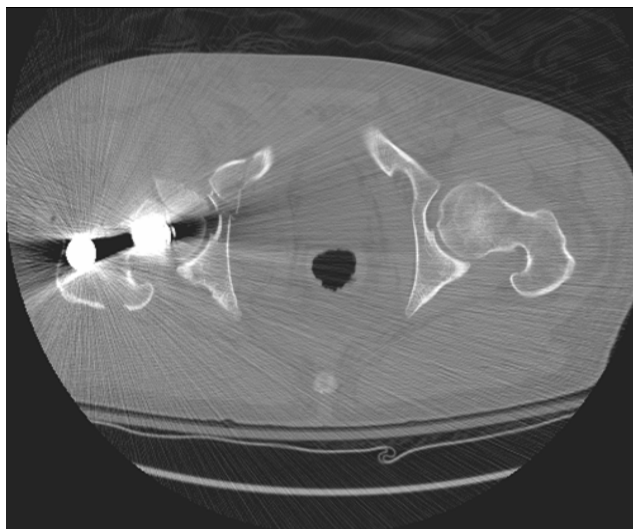


Figure 2. Computed tomography scan shows the right femoral head fracture flipped 180° in the acetabulum.

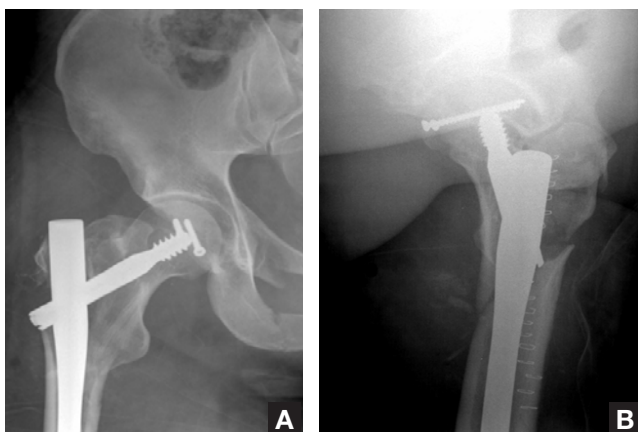


Figure 3. (A) Anteroposterior and (B) lateral postoperative plain films show anatomic reduction of the femoral head fracture with two 4.0-mm screws. The intertrochanteric femur fracture was stabilized with a cephalomedullary nail.

The patient was made non-weight-bearing with crutches and was placed in a hip abduction brace. He had an uneventful hospital stay and was discharged to a rehabilitation facility on hospital day 8. At 10-week follow-up, he was made 25% weight-bearing, and the hip brace was discontinued. He was made partial weight-bearing at 4-month follow-up and was advanced to weight-bearing as tolerated at 6-month follow-up. Although he complained mildly of minor aches, he was ambulating and climbing stairs with ease. Final plain films obtained 7 months after trauma showed that the femoral head fracture and the intertrochanteric fracture had healed (Figure 4). Clinically asymptomatic heterotopic ossification (HO) in the quadriceps muscles was noted on plain films.

“Small fragments with concentric reduction and a step-off of less than 1 mm may be treated nonoperatively with closed reduction and traction.”

DISCUSSION

Femoral head fractures are usually the result of high-energy trauma, such as that sustained in motor vehicle accidents, and occur in 7% to 13% of posterior hip dislocations.³ Well-known sequelae of femoral head fractures include HO, avascular necrosis (AVN), and posttraumatic arthritis.^{4,5} Despite advances in diagnostic and surgical techniques, treatment outcomes are fraught with complications, and treatment options remain the subject of debate.³

The Pipkin classification of femoral head fractures is a useful predictor of outcomes.^{3,4} As Pipkin indicated, type I fractures occur caudad to the fovea, type II occur cephalad to the fovea, type III have an associated femoral neck fracture, and type IV have an associated acetabular fracture.

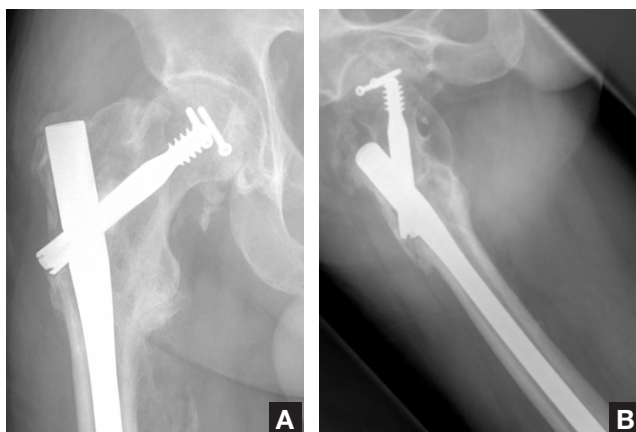

Figure 4. Final anteroposterior (A) and lateral (B) plain films obtained 7 months after trauma show healed fractures. Heterotopic ossification in the quadriceps muscles is also noted.

Small fragments with concentric reduction and a step-off of less than 1 mm may be treated nonoperatively with closed reduction and traction. However, if the reduction is nonconcentric, or if the closed reduction is nonanatomic, then ORIF is indicated. Femoral head fractures associated with femoral neck/acetabular fractures require ORIF. Outcomes are better with type I and type II fractures than with types III and IV (indicating worse outcome with more severe injury), whereas time to fixation appears not to affect long-term functional results.³

In the literature, ORIF has been recommended for Pipkin fractures with a large fragment.^{3,6} Surgical options include fixation with Herbert screws or countersunk 4.0-mm cancellous screws (for reducible fractures) and hemiarthroplasty (for early postoperative mobility in elderly patients). Cannulated 3-mm screws with washers are contraindicated because screw-washer dissociation can lead to articular cartilage damage and loss of fixation.⁵ Fragment excision, though controversial, may be performed if the fragment is less than a third the size of the head.^{3,7,8} However, there may not be a statistically significant difference in outcomes when excision is compared with fixation of the fractured fragment.^{3,9}

The optimal surgical approach for femoral head fractures is debated, with disagreements centering on the potential for increased AVN and HO. Epstein^{10,11} believed that using the anterior approach for open reduction of Pipkin fractures may compromise the remaining anterior vessels and potentially increase the risk for AVN; on the other hand, the posterior approach makes optimal visualization and treatment of the fracture fragment more difficult. Swiontkowski and colleagues⁶ found that using the anterior approach significantly decreased operative time and blood loss while improving visualization. They also found that, though HO was higher in patients treated with a posterior approach compared with an anterior approach, the 2 groups did not differ in long-term functional outcomes and AVN rates. Radiotherapy (single 800-cGy dose) and indomethacin have both been shown to be of benefit for HO prophylaxis.^{12,13}

Our patient's injury pattern is extremely rare. Although the literature includes reports of femoral neck fracture associated with femoral head fracture-dislocation,¹⁴ to our knowledge only 2 cases of ipsilateral Pipkin fracture plus an intertrochanteric fracture have been reported.^{1,2} It is thought that, if the forces leading to hip dislocation and femoral head fractures are not entirely dissipated at the moment of impact, then residual energy may lead to femoral neck fracture.⁴ It is possible that a similar mechanism may be responsible for the extremely rare associated intertrochanteric femur fracture in the setting of a femoral head fracture.

Our patient's case shows that careful vigilance is required to ensure that the femoral head fracture fragment is reduced within the acetabulum when closed reduction is attempted. A preoperative CT scan could have assisted us in determining the congruency and reduction of the femoral head fracture so that malreduced fragments could have been treated definitively at the time of the index procedure.

Our patient had a favorable functional outcome with no evidence of AVN (according to plain films) at the 7-month follow-up. Although HO was present, it was asymptomatic and did not cause any functional disability. The ipsilateral tibia fracture healed successfully and without further sequelae.

CONCLUSIONS

Concentric anatomic reduction with rigid fixation is important for the successful treatment of femoral head fractures. Associated injuries (eg, acetabular and femoral neck fractures) may occur, but an ipsilateral intertrochanteric fracture such as the one described is extremely rare. An anterior approach for ORIF of the femoral head fracture allows excellent visualization and treatment. HO may develop postoperatively, but it appears not to be of clinical significance.

AUTHOR'S DISCLOSURE STATEMENT AND ACKNOWLEDGEMENT

The authors report no actual or potential conflict of interest in relation to this article. No benefits have been or will be received as a result of the publication of this report.

REFERENCES

1. Mostafa MM. Femoral head fractures. *Int Orthop*. 2001;25:51-54.
2. Barquet A, Mussio A. Fracture dislocation of the femoral head with associated ipsilateral trochanteric and shaft fracture of the femur. *Arch Orthop Trauma Surg*. 1983;102:61-63.
3. Marchetti ME, Steinberg GG, Coumas JM. Intermediate-term experience of Pipkin fracture-dislocations of the hip. *J Orthop Trauma*. 1996;10:455-461.
4. Pipkin G. Treatment of grade IV fracture-dislocation of the hip. A review. *J Bone Joint Surg Am*. 1957;39:1027-1042.
5. Stannard JP, Harris HW, Volgas DA, Alonso JE. Functional outcome of patients with femoral head fractures associated with hip dislocations. *Clin Orthop*. 2000;377:44-56.
6. Swiontkowski MF, Thorpe M, Seiler JG, Hansen ST. Operative management of displaced femoral head fractures: case-matched comparison of anterior versus posterior approaches for Pipkin I and Pipkin II fractures. *J Orthop Trauma*. 1992;6:437-442.
7. Epstein HC, Wiss DA, Cozen L. Posterior fracture dislocation of the hip with fractures of the femoral head. *Clin Orthop*. 1985;201:9-17.
8. Roeder LF, DeLee JC. Femoral head fractures associated with posterior hip dislocations. *Clin Orthop*. 1980;147:121-130.
9. Brumback RJ, Kenzora JE, Levitt LE, Burgess AR, Poka A. Fractures of the femoral head. In: *Proceedings of the Hip Society, 1986*. St. Louis, Mo: Mosby; 1987:181-206.
10. Epstein H. Posterior fracture-dislocation of the hip: comparison of open and closed methods of treatment in certain types. *J Bone Joint Surg Am*. 1961;43:1079-1098.
11. Epstein HC. Posterior fracture dislocations of the hip. *J Bone Joint Surg Am*. 1974;56:1103-1127.
12. Healy WL, Lo TC, DeSimone AA, Rask B, Pfeifer BA. Single-dose irradiation for the prevention of heterotopic ossification after total hip arthroplasty. *J Bone Joint Surg Am*. 1988;70:233-239.
13. Moed B, Maxey J. The effect of indomethacin on heterotopic ossification following acetabular fracture surgery. *Orthop Trans*. 1989;13:759-760.
14. Mehara AK, Ramchandani GD, Sharma CS, Bhardwaj V, Gupta RG. Unusual posterior hip dislocation with ipsilateral fractures of the femoral neck and head. *J Trauma*. 1995;38:658-659.