

Reduction of High-Grade Isthmic and Dysplastic Spondylolisthesis in 5 Adolescents

Baron S. Lonner, MD, Edward W. Song, MD, Carrie L. Scharf, BA, and Jeff Yao, MD

Abstract

Treatment of high-grade isthmic and dysplastic spondylolisthesis in children and adolescents remains a challenge. Surgical treatment of spondylolisthesis has been recommended in adolescents with pain refractory to nonoperative modalities, slippage progression, or >50% slippage on presentation. Controversy exists as to the optimal surgical approach for high-grade spondylolisthesis. In this report, we describe 5 cases of high-grade isthmic and dysplastic spondylolisthesis in adolescents and review the literature on surgical treatment for this entity. Operative records, charts, x-rays, and Scoliosis Research Society outcome questionnaires (SRS-22) were retrospectively evaluated for 5 consecutive patients diagnosed with and treated for high-grade spondylolisthesis. Each patient received treatment consisting of decompression, reduction, and circumferential fusion with transpedicular and segmental fixation from a posterior approach. Two patients had transient L5 nerve root deficit, which resolved within 3 months. Reduction benefits include a decrease in shear stresses (and resulting decreased rates of postoperative pseudarthrosis and slip progression), restoration of sagittal alignment and lumbosacral spine balance, and improvement in clinical deformity.

Treatment of high-grade isthmic and dysplastic spondylolisthesis in children and adolescents remains a challenge. Newman¹ classified spondylolisthesis into 5 types, with I (dysplastic or congenital) and II (isthmic) being most commonly ascribed to children and adolescents. The etiology of dysplastic or congenital (type I) spondylolisthesis is a congenital anomaly of the lumbosacral articulation. The facet joints are often hypoplastic and sagittally oriented, making these joints incompetent to prevent forward

translation of L5 on S1. Isthmic spondylolisthesis (type II) may be caused by stress fracture from repetitive microtrauma to the pars interarticularis or by acute pars interarticularis fracture, most commonly of the fifth lumbar vertebra.¹

Surgical treatment of spondylolisthesis has been recommended in adolescents with pain refractory to nonoperative modalities, slippage progression, or slippage of >50% on presentation (Meyerding grade 3 or 4).² High-grade slips can be treated with various surgical procedures, including decompression and circumferential arthrodesis with interbody grafting or transvertebral fibular grafting.³⁻⁹ Gaines¹⁰ recommended L5 vertebrectomy with circumferential fusion of L4 to the sacrum for spondyloptosis. Reduction and fusion to correct both deformity and sagittal alignment have also been advocated.¹¹

The idea of using reduction for high-grade spondylolisthesis has been received with tepid enthusiasm because of the association of this procedure with iatrogenic neurologic deficits.¹²⁻¹⁵ Some authors have advocated a partial reduction of translation with particular attention directed to slip-angle reduction to minimize this risk.¹⁶⁻¹⁸ Others have noted that, even with minimal or no reduction, preoperative neurologic deficits, including cauda equina syndrome, often resolve, and gait and hamstring tightness improve with fusion.¹⁹⁻²² Still, in situ fusion has been associated with new-onset cauda equina in high-grade spondylolisthesis in the absence of preoperative deficits.^{12,14,19} Despite the debate in the literature, it can be extrapolated from experience with sagittal imbalance disorders (eg, flat-back syndrome) that at least partial reduction and correction of the underlying lumbosacral kyphosis should be achieved whenever possible, as long as the operative risks are acceptable.

In this report, we describe 5 cases of high-grade (Meyerding 3 or 4) isthmic and dysplastic spondylolisthesis in adolescents treated by Dr. Baron Lonner. Each patient received treatment consisting of decompression, reduction, and circumferential fusion with transpedicular, segmental fixation from a posterior approach. We also assess these adolescents' clinical, radiographic, and patient-based outcomes and review the literature on surgical treatment of high-grade spondylolisthesis.

Dr. Lonner is Clinical Assistant Professor of Orthopaedic Surgery, and Dr. Song is Spine Fellow, Hospital for Joint Diseases—New York University Medical Center, New York, New York.

Ms. Scharf is Medical Student, New York University School of Medicine, New York, New York.

Dr. Yao is Resident, Long Island Jewish Medical Center, New Hyde Park, New York.

Requests for reprints: Baron S. Lonner, MD, 212 E 69th St, New York NY 10021 (tel, 212-737-5540; fax, 212-737-1369; e-mail, blonner@nyc.rr.com).

Am J Orthop. 2007;36(7):367-373. Copyright Quadrant HealthCom Inc. 2007. All rights reserved.

Table I. Radiographic Parameters*

Case	Type of Spondylolisthesis	Grade	Time of Assessment	Slip (%)	Slip Angle	Sagittal Balance (°)	Scoliosis (°)
1	Dysplastic	III	Preoperative	67	44	+5.6	54
		0	Postoperative	0	13	+2.7	45
		I	Follow-up (4 y)	13	20	+3.7	80
2	Dysplastic	IV	Preoperative	88	64	+8.5	70
		II	Postoperative	30	36	+7.0	54
		II	Follow-up (24 mo)	31	40	+7.0	19
3	Isthmic	IV	Preoperative	83	30	+5.0	NA
		II	Postoperative	25	15	+0.9	NA
		I	Follow-up (3y 7mo)	30	10	-2.1	NA
4	Isthmic	IV	Preoperative	76	19	+5.0	16
		II	Postoperative	31	3	0	10
		II	Follow-up (2y 7mo)	28	5	1.7	8
5	Dysplastic	IV	Preoperative	88	40	-1.3	61
		II	Postoperative	27	3	-3.2	53
		I	Follow-up (28 mo)	25	4	0	8

*NA indicates not applicable.

Table II. Clinical Findings

Case	Time of Assessment	Age (y, mo)	Back Pain	Leg Pain	Bladder Function	Hamstrings	Neurologic Findings
1	Preoperative	12, 7	Y	Y	Stress incontinence	Tight	Bilateral 4/5 EHL
	Postoperative	12, 11	N	N	Continent	Supple	4/5 left EHL, 5/5 right EHL;
	Follow-up	6, 3	Y	N	Continent	Supple	L5 dysesthesia resolved 5/5 throughout
2	Preoperative	12, 5	Y	Y	Stress incontinence	Supple	5/5 throughout
	Postoperative	12, 10	N	N	Continent	Supple	Intact
	Follow-up	13, 10	N	N	Continent	Supple	Intact
3	Preoperative	14, 9	Y	Y	Continent	Tight	5/5 throughout
	Postoperative	15, 1	N	N	Continent	Supple	Intact
	Follow-up	18, 7	N	N	Continent	Supple	Intact
4	Preoperative	13, 10	N	N	Continent	Tight	Intact
	Postoperative	14	N	N	Continent	Supple	Resolution of postoperative 3/5 right EHL weakness; bilateral 5/5 EHL
	Follow-up	16, 10	N	N	Continent	Supple	Intact
5	Preoperative	12, 0	N	N	Urinary frequency	Supple	5/5 throughout
	Postoperative	12, 7	N	N	Resolved/continent	Supple	5/5
	Follow-up	14, 11	N	N	Continent	Supple	Intact

*EHL indicates extensor hallucis longus.

MATERIALS AND METHODS

Patients

All 5 patients were referred to Dr. Lonner and underwent surgery between March 2001 and April 2002. We retrospectively reviewed these patients' office charts, plain films, and Scoliosis Research Society outcome questionnaires (SRS-22). Four of the 5 patients also had scoliosis, which was treated. Three of these 4 patients subsequently had scoliosis treated surgically after successful healing of spondylolisthesis correction. All patients underwent the same procedure, but, for the case 5 patient, who also had Marfan syndrome and small pedicles at L4 associated with dural ectasia, the procedure was

modified (the L4 vertebra was not instrumented, but posterolateral fusion was extended to L4).

Operative Technique

For each patient, general endotracheal anesthesia was administered, and the patient was placed on a 4-poster spinal frame in the prone position. Subperiosteal dissection of the posterior spinal elements out to the tips of the transverse processes of L4 and L5 and to the sacral alae was done for exposure. In a case of isthmic spondylolisthesis, the L5 lamina was removed through the pars interarticularis defect, and fibrocartilaginous tissue was excised, thereby decompressing the fifth lumbar nerve root bilaterally. In

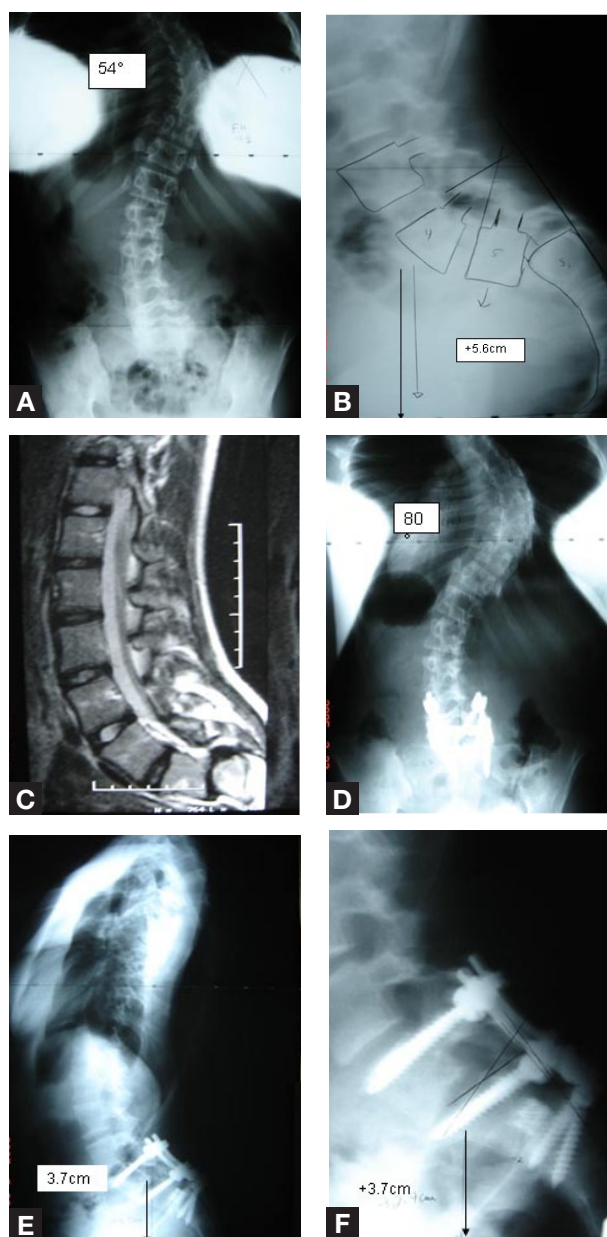


Figure 1. (A,B) Preoperative anteroposterior (AP) and lateral plain films show high-grade spondylolisthesis associated with scoliosis with significant sagittal imbalance. (C) Preoperative magnetic resonance image. (D) Postoperative AP film shows lack of correction of scoliosis, which was treated later with combined thoracoscopic anterior release and fusion and posterior instrumented fusion. (E,F) Lateral films show improved sagittal balance.

a case of dysplastic spondylolisthesis in which the neural arch was intact, the lamina was removed by osteotomizing the pars region and removing the entire inferior (medial) facet. The superior and medial edges of the sacral facet were removed with an osteome and Kerrison rongeur.

Both L5 and S1 nerve roots were clearly visible and widely decompressed. The S1 roots appeared ribbonlike because of stretching over the sacrum, and the L5 foraminal height was shortened. Fixed-angle pedicle screws were placed into the S1 pedicles to achieve bicortical fixation in a convergent screw pattern using the largest possible screw

diameter. Bilateral L4 reduction screws were placed, and 2 rods were fashioned with appropriate degrees of lordosis contoured into the rods. The rods were fixed at the sacrum, and gentle bilateral distraction was performed as the set screws for the L4 pedicle screws were gradually advanced to bring the fifth lumbar vertebrae out of the pelvis and into a partially reduced position. In this series, 1 patient with Marfan syndrome and small dysplastic pedicles at L4 had instrumentation only from L5–S1 and therefore required initial instrumentation of the L5 pedicles. Posterolateral fusion was extended to L4 in that patient. Distraction was performed gradually with the force of the index and middle fingers against the thumb on a distractor so as to minimize nerve root stretch.

The L5 and S1 nerve roots were visible during reduction. After the set screws were maximally tightened, 1 rod was removed, and a reduction pedicle screw was placed into the L5 pedicle, which was now more accessible. The rod and set screws were then replaced, and the same steps were taken on the contralateral side. Further reduction was done by tightening the set screws on the L5 reduction screws under gentle distraction. The L4 set screws were not fully tightened at that point. The L5–S1 annulus was left intact so it would act as a ligamentous restraint to overdistraction.

After reduction was achieved, complete L5–S1 discectomy was performed. The sacral dome was osteotomized, with bone (5–10 mm) removed to create a flat surface and to allow for shortening of the vertebral column. In addition, the posterior overhang of the L5 vertebral body was osteotomized to create a flat fusion surface. Titanium mesh cages (8 mm in height), packed with local bone and iliac crest autogenous graft, were placed bilaterally at the posterior third of the disc space, and additional bone was packed around the cages. Distraction was removed from the L4–L5 segment, and compression across the L5–S1 segment was then performed. The L5 and S1 nerve roots were then carefully checked for compression and adequate mobility. A wakeup test was then performed. Transverse processes and posterior elements were decorticated. Posterolateral bone grafting from L4 to the sacrum was then done.

RESULTS

Case Histories

Radiographic data and clinical findings are summarized in Tables I and II.

Case 1. The patient was a girl (age, 12 years, 7 months) with back and leg pain and stress incontinence. On examination, she had a crouched gait and stood with hips and knees flexed with a hyperlordotic lumbar spine. Adams forward-bend test showed a right thoracic rib prominence. Other details are listed in Tables I and II. The postoperative course was complicated by left foot (L5) dysesthesias, which were treated with gabapentin and oral steroids. Symptoms resolved within 2 months after surgery. Solid

arthrodesis was noted at follow-up. Thoracic curvature increased from 54° to 80° . Scoliosis was subsequently treated with combined thoracoscopic anterior release and posterior instrumentation fusion (Figures 1A-1F).

Case 2. The patient, a girl (age, 12 years, 5 months), had back and leg pain and urinary stress incontinence. Results from neurologic testing in both lower extremities were normal, and the hamstrings were supple. Other details are listed in Tables I and II. Three months after surgery, back and leg pain and urinary incontinence were resolved. Eleven months after index surgery, posterior spinal fusion was performed for scoliosis. On final follow-up, scoliosis was 19° . Solid arthrodesis was noted.

Case 3. The patient, a girl (age, 14 years, 9 months), presented with back and leg pain and tight hamstrings. Bowel function and bladder function were intact. Examination showed tight hamstrings but no neurologic abnormalities. Other details are listed in Tables I and II. The patient reported complete resolution of back and leg pain after surgery. Solid arthrodesis was noted at final follow-up (Figures 2A-2E).

Case 4. The patient was a boy (age, 13 years, 10 months) presented for evaluation of asymptomatic scoliosis. He had no bowel or bladder dysfunction. Physical examination showed tight hamstrings but normal neurologic function of both lower extremities. Other details are listed in Tables I and II. Spondylolisthesis was treated surgically. The postoperative course was complicated by 3/5 right extensor hallucis longus (EHL) weakness (it resolved completely within 3 months after surgery). Scoliosis resolved within 3 months after surgery; at final follow-up (30 months after surgery), it was 8° . Solid arthrodesis was noted.

Case 5. The patient, a girl (age, 12 years, 0 month), had Marfan syndrome and presented for scoliosis evaluation. She had no bowel dysfunction but admitted to urinary frequency. On physical examination, Marfanoid features were noted, neurologic findings in both lower extremities were normal, and hamstrings were supple. Other details are listed in Tables I and II. Surgery was performed for spondylolisthesis. One year 9 months after index surgery, she underwent anterior-posterior spinal fusion for scoliosis. Solid arthrodesis was noted at final follow-up.

SRS Data

Two of the 5 patients had both preoperative and follow-up SRS-22 data. For case 1, mean overall outcome score improved from a mean of 2.1 before surgery to 3.1 at last follow-up, and satisfaction score increased from 3 to 4 (1 = poorest outcome, 5 = best possible outcome). For case 2, overall outcome improved from 3.3 to 4.4 at last follow-up, but the patient did not answer the satisfaction questions at follow-up.

The other 3 patients lacked preoperative data but had follow-up data: For case 2, overall outcome was 4.4, and

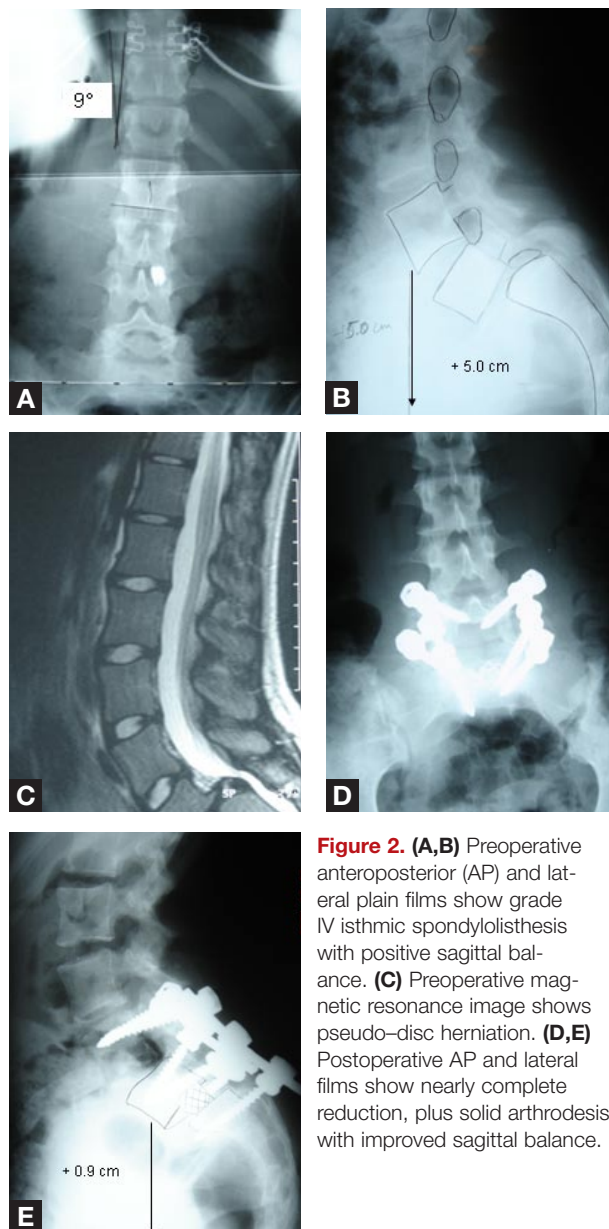


Figure 2. (A,B) Preoperative anteroposterior (AP) and lateral plain films show grade IV isthmic spondylolisthesis with positive sagittal balance. (C) Preoperative magnetic resonance image shows pseudo-disc herniation. (D,E) Postoperative AP and lateral films show nearly complete reduction, plus solid arthrodesis with improved sagittal balance.

satisfaction was 4.4; for case 4, overall outcome was 4.3, and satisfaction was 4.5; for case 5, overall outcome was 3.3, and satisfaction was 3. The less satisfactory outcome in case 5 may have been related to the patient's having Marfan syndrome as well as scoliosis that required additional surgery.

DISCUSSION

Surgical treatment of high-grade isthmic and dysplastic spondylolisthesis in adolescents is controversial. In situ fusion for high-grade spondylolisthesis is associated with a high rate of postoperative progression and worsening deformity.²³ Schoenecker and colleagues²⁴ reported a 6% rate of new-onset cauda equina syndrome after posterolateral fusion, with higher incidence in patients having more residual deformity and a slip angle of more than 45° after fusion.

Reduction has been suggested for patients with objective preoperative neurologic findings, poor sagittal balance,

and unacceptable clinical deformity. Reduction reduces shear stresses on the fusion mass and thus decreases the rate of postoperative pseudarthrosis and slip progression. Correction of the sagittal contour of the lumbosacral spine and improvement in clinical deformity are benefits of reduction.²⁵

High pelvic incidence, hyperlordosis, forward lumbar tilt, and positive sagittal balance are associated with high-grade spondylolisthesis.^{26,27} The superior endplate of L5, L4, and often L3 is inclined toward the floor, and marked lumbosacral kyphosis (indicated by positive slip angle) occurs.²⁸ If these relationships are left uncorrected, segmental hyperlordosis proximal to the fusion results as a compensatory mechanism to restore sagittal balance. As in the analogous flatback syndrome, adjacent unfused segments are likely to fail (eventually) so as to compensate for residual sagittal imbalance over time and may result in adjacent segment disk degeneration and back pain.^{20,29} Ideally, monosegmental fusion and instrumentation should be considered if the L5–S1 segment can be anatomically aligned, as described by Harms and colleagues³⁰ and recently reported by Shufflebarger and Geck.³¹ This may minimize the problem of transitional syndromes resulting from multiple fused segments over the long term.²⁹

Instrumented reduction makes the L5 nerve root vulnerable to traction injury. Results from a cadaveric study have shown increases in L5 tension occurring with L5 vertebral body reductions of more than 50%.¹⁸ Shufflebarger,³² using a technique similar to that reported here, had no cases of postoperative nerve root deficit. Despite posterior decompression and bilateral L5 foraminal decompressions, 2 of the 5 cases in our small series had transient nerve root symptoms after surgery. Several authors^{16,33} noted several cases of neurologic worsening in a series in which slip-angle reduction was obtained without significantly improving translation.

Techniques have evolved to minimize complication rates. In our approach, evolved from Edwards and Harms, reduction is done gradually, with gentle distraction between L4 and the sacrum.^{25,34} Spinal shortening is done by resecting the sacral dome and part of the inferior endplate of L5. Although a spacer (cage) is placed in the disc space, it does not make up for the total resection achieved, thus allowing for shortening of the spinal column. In our case 4, transient EHL weakness occurred unilaterally (it resolved completely within 3 months). No patient experienced permanent neurologic deterioration. There was a case of severe leg dysesthesias, which resolved within 2 months, in the 1 patient in whom annulectomy and disc excision were performed before the distraction maneuver. Perhaps this allowed overdistracted and excessive traction on the L5 nerve root as a result of lack of ligamentous restraint of the posterior longitudinal ligament and annulus. Molinari and colleagues¹⁷ found a 15% incidence of transient neurologic deficits in patients with high-grade spondylolisthesis treated with reduction, fusion, and decompression. Gaines¹¹ reported a high rate of transient L5 nerve root deficits after

L5 vertebrectomy, with the majority of patients fully recovering within 6 months after the procedure.

Continuous intraoperative electromyography and somatosensory evoked potentials (SSEP) monitoring did not detect abnormalities in the patient with transient EHL weakness or in the patient with dysesthetic pain. Although wakeup tests are recommended for such patients, these tests are unlikely to elucidate subtle L5 distribution weakness. If gross motor deficits are encountered, the reduction should be lessened and L5 and S1 nerve roots reexplored.⁹

Factors associated with pseudarthrosis include high postoperative slip angle, small L5 transverse process area, lack of spinal instrumentation, and lack of interbody fusion.³⁵ Pseudarthrosis rates up to 25% have been reported with posterolateral fusions for spondylolisthesis, and the rate of this complication increases with slip grade.^{34,36,37} Molinari and colleagues¹⁷ found a 45% incidence of pseudarthrosis in patients with high-grade slips treated with in situ posterolateral fusion. The authors¹⁷ recommended use of reduction and posterior circumferential fusion with autogenous bone graft. A transforaminal approach avoids undue nerve root retraction and potential nerve root injury or dural tear. Furthermore, a single posterior approach avoids the morbidity of an anterior approach, including the potential for retrograde ejaculation (male patients) and vessel injury.³⁸⁻⁴¹ Moreover, both dysplastic spondylolisthesis and isthmic spondylolisthesis have their genesis in failure of posterior elements, with secondary changes occurring in the sacrum and the L5 vertebral body—a problem that can be fully addressed with a posterior approach. That is, deficient posterior elements are removed, L5 and S1 nerve roots are decompressed, alignment is gradually restored, and sacral dome and L5 inferior endplate dysplasia is addressed with osteotomies that plane the abnormal surfaces all from a single approach.⁴²

Adolescents vary in their clinical presentations of high-grade isthmic and dysplastic spondylolisthesis.⁴³⁻⁴⁷ Patients may be asymptomatic or may have back or leg pain, neurologic deficits typically involving the fifth lumbar nerve root (resulting in EHL weakness and sensory loss), or urinary abnormalities. High-grade slips have been associated with bladder dysfunction in up to 28% in some series.^{23,25} Urinary dysfunction may be subtle and may not be discovered without pointed questioning. Three of the 5 patients in our series had urinary dysfunction. None of the patients or their families reported these symptoms, perhaps out of embarrassment. One patient had stress incontinence with coughing or sneezing, another had new-onset bed-wetting, and a third patient had urinary frequency. Thus, 3 of 5 patients had some degree of preoperative neurologic involvement, which in all cases resolved shortly after surgery. Some have suggested that neurologic symptoms, particularly L5 radicular symptoms, resolve when solid fusion is achieved, and reduction is not necessary.¹⁹⁻²² Resolution of bladder dysfunction with in situ fusion has not been reported. Therefore, we recommend careful questioning of patient and family members regarding urinary function.

Urometric evaluation may also be useful.

Patients may also present with the stereotypical Phalen-Dickson sign (ie, crouched gait, hip and knee flexion contractures). A stepoff at the lumbosacral junction may also be noted. Some patients have few or no symptoms and few physical findings. Two of our 5 patients were referred for scoliosis evaluation and presented with an anteroposterior plain film. Only after lateral films were obtained was the defect noted. Thus, vigilance for spondylolisthesis is required for anyone who presents with scoliosis.

Scoliosis is often associated with spondylolisthesis in the pediatric population.⁴⁸⁻⁵² As mentioned, 2 of our 5 patients presented for scoliosis evaluation, with spondylolisthesis noted incidentally on radiographic evaluation. Four of the 5 patients in this series had scoliosis. Scoliosis in patients with spondylolisthesis may be idiopathic (ie, not directly related to the former condition) or a so-called olisthetic type (resulting from rotatory subluxation of the spine). In the latter curve type, which typically emanates from the lumbosacral region and encompasses a long section of the spine, partial resolution of scoliosis may occur after successful arthrodesis for spondylolisthesis. In our series, resolution occurred in the patient with 16° olisthetic scoliosis (case 4). In the other patient (case 2), the curvature initially improved from 70° to 54° but subsequently progressed and required surgery (an initial curvature of that magnitude is unlikely to resolve). Thus, in our series, 3 of the 4 patients with scoliosis required surgery for the curvature.

Some Additional Recommendations

- In all our cases, there were at least 2 unfused motion segments between scoliosis and spondylolisthesis fusions. If only 1 unfused segment is expected to remain, we recommend including both segments in a long fusion.
- We also recommend doing spondylolisthesis surgery first, as spondylolisthesis should be stabilized to avoid further slip progression and/or neurologic deterioration, particularly with a patient undergoing general anesthesia.
- Furthermore, as the curvature may improve or its end vertebrae change as a result of the spondylolisthesis surgery, scoliosis surgery should be delayed.

CONCLUSIONS

Decompression, reduction, and circumferential fusion with transpedicular, segmental fixation from a posterior approach constitute effective surgery for adolescent patients with high-grade isthmic or dysplastic spondylolisthesis. This treatment is best applied to patients with preoperative neurologic deficit, marked sagittal imbalance, and unacceptable deformity. A significant risk for postoperative L5 nerve root deficit exists, but this deficit is transient for most patients.

AUTHORS' DISCLOSURE STATEMENT

The authors report no actual or potential conflict of interest in relation to this article.

REFERENCES

1. Newman PH. A clinical syndrome associated with severe lumbosacral subluxation. *J Bone Joint Surg Br.* 1965;47:472-481.
2. Wiltse LL, Jackson DW. Treatment of spondylolisthesis and spondylolysis in children. *Clin Orthop.* 1976;117:92-100.
3. Lonstein JE. Spondylolisthesis in children. *Spine.* 1999;24:2640-2648.
4. Amuso SJ, Neff RS, Coulson DB, et al. The surgical treatment of spondylolisthesis by posterior element resection. *J Bone Joint Surg Am.* 1970;52:529-536.
5. Lafond G. Surgical treatment of spondylolisthesis. *Clin Orthop.* 1962;22:175-179.
6. Pizzutillo PD, Miranda W, MacEwen GW. Posterolateral fusion of spondylolysis or spondylolisthesis. *J Pediatr Orthop.* 1986;9:538-540.
7. Smith MD, Bohlman HH. Spondylolisthesis treated by a single-stage operation combining decompression with in situ posterolateral and anterior fusion. *J Bone Joint Surg Am.* 1990;72:415-420.
8. Hanson DS, Bridwell KH, Rhee JM, Lenke LG. Dowel fibular strut grafts for high-grade dysplastic isthmic spondylolisthesis. *Spine.* 2002;27:1982-1988.
9. Lenke LG, Bridwell KH. Evaluation and surgical treatment of high-grade isthmic dysplastic spondylolisthesis. *Instr Course Lect.* 2003;52:525-532.
10. Gaines RW, Nichols WK. Treatment of spondylolysis by two stage L5 vertebratomy and reduction of L4 to sacrum. *Spine.* 1985;10:680-685.
11. Boos N, Marchesi D, Zuber K, Aebi M. Treatment of severe spondylolisthesis by reduction and pedicular fixation. *Spine.* 1993;12:1655-1661.
12. Bradford DS. Treatment of severe spondylolisthesis. *Spine.* 1979;4:423-429.
13. DeWald RL, Faut MM, Taddonio RF, Neuwirth MG. Severe lumbosacral spondylolisthesis in adolescents and children. Reduction and staged circumferential fusion. *J Bone Joint Surg Am.* 1981;63:619-626.
14. Matthias H, Heine J. The surgical reduction of spondylolisthesis. *Clin Orthop.* 1986;203:34-44.
15. Amundson GE, Garfin SR. *Spondylolisthesis.* Philadelphia, Pa: Saunders; 1992.
16. Bradford DS, Boachie-Adjei O. Treatment of severe spondylolisthesis by anterior and posterior reduction and stabilization. *J Bone Joint Surg Am.* 1990;72:1060-1065.
17. Molinari RW, Bridwell KH, Lenke LG, Ungacta FF, Riew KD. Complications of the surgical treatment of pediatric high-grade, isthmic dysplastic spondylolisthesis. *Spine.* 1999;24:1701-1711.
18. Petraco DM, Spivak JM, Cappadona JG, Kummer FJ, Neuwirth MG. An anatomic evaluation of L5 nerve stretch in spondylolisthesis reduction. *Spine.* 1996;21:1133-1138.
19. Wiltse LL, Rothman LG. Spondylolisthesis: classification, diagnosis, and natural history. *Semin Spine Surg.* 1989;1:78-94.
20. Boxall D, Bradford DS, Winter RB, Moe JH. Management of severe spondylolisthesis in children and adolescents. *J Bone Joint Surg Am.* 1979;61:479-495.
21. Hensinger RN, Lang JR, MacEwen GD. Surgical management of spondylolisthesis in children and adolescents. *Spine.* 1976;1:207-216.
22. Newton P, Johnston C. Analysis and treatment of poor outcomes following in situ arthrodesis in adolescent spondylolisthesis. *J Pediatr Orthop.* 1997;17:754-761.
23. Seitsalo S, Osterman K, Hyvarinen H, Schlenzka D, Poussa M. Severe spondylolisthesis in children and adolescents. *J Bone Joint Surg Br.* 1990;72:259-265.
24. Schoenecker PL, Cole HO, Herring JA, Capelli AM, Bradford DS. Cauda equina syndrome after in situ arthrodesis for severe spondylolisthesis at the lumbosacral junction. *J Bone Joint Surg Am.* 1990;72:369-377.
25. Hu SS, Bradford DS, Transfeldt EE, Cohen M. Reduction of high-grade spondylolisthesis using Edwards instrumentation. *Spine.* 1996;21:367-371.
26. Duval-Beaupere G, Boisauvert B, Hecquet J, Lagaye J, Marty C, Montigny JP. Sagittal profile of normal spine changes in spondylolisthesis. In: Harms J, Stürz H, eds. *Severe Spondylolisthesis: Pathology-Diagnosis-Therapy.* Darmstadt, Germany: Steinkopff; 2002:21-32.
27. Hanson DS, Bridwell KH, Rhee JM, Lenke LG. Correlation of pelvic incidence with low- and high-grade isthmic spondylolisthesis. *Spine.* 2002;27:2026-2029.
28. Rajnics P, Templier A, Skalli W, Lavaste F, Illes T. The association of sagittal spinal and pelvic parameters in asymptomatic persons and patients with isthmic spondylolisthesis. *J Spinal Disord Tech.* 2002;15:24-30.
29. Schlegel JD, Smith J, Schleusener RL. Lumbar motion segment pathology adjacent to thoracolumbar, lumbar, and lumbosacral fusions. *Spine.* 1996;21:970-981.
30. Harms J, Jeszensky D, Stoltze D, Böhm H. True spondylolisthesis reduction and monosegmental fusion in spondylolisthesis. In: Bridwell KH, DeWald RL, eds. *Textbook of Spinal Surgery.* 2nd ed. Philadelphia, Pa: Lippincott; 1997:1337-1347.
31. Shufflebarger HL, Geck MJ. High grade isthmic and dysplastic spondylolisthesis: monosegmental surgical treatment. *Spine.* 2005;30:S42-S48.
32. Shufflebarger HL. High grade isthmic spondylolisthesis: monosegmental surgical treatment. Paper presented at: Annual Meeting of the Scoliosis Research Society; 1998; New York, NY.
33. Smith JA, Deviren V, Berven S, Kleinstueck F, Bradford DS. Clinical outcome of trans-sacral interbody fusion after partial reduction for high-grade spondylolisthesis. *Spine.* 2001;26:2227-2234.
34. Edwards CC. Reduction of spondylolisthesis. In: Bridwell KH, DeWald RL, eds. *Textbook of Spinal Surgery.* Philadelphia, Pa: Lippincott; 1991:605-634.

35. Harrington PR, Tullos HS. Spondylolisthesis in children: observations and surgical treatment. *Clin Orthop*. 1971;79:75-84.
36. Ishikawa S, Kumar SJ, Torres BC. Surgical treatment of dysplastic spondylolisthesis: results after in situ fusion. *Spine*. 1994;19:1961-1966.
37. Frennered AK, Danielson BI, Nachemson AL, Nordwall AB. Midterm follow-up of young patients fused in situ for spondylolisthesis. *Spine*. 1991;16:409-416.
38. Lehmer SM, Steffee AD, Gaines RW. Treatment of L5-S1 spondyloptosis by staged L5 resection with reduction and fusion of L4 onto S1. *Spine*. 1994;19:1916-1925.
39. Ishihara H, Osada R, Kanamori M, et al. Minimum 10-year follow-up study of anterior lumbar interbody fusion for isthmic spondylolisthesis. *J Spinal Disord*. 2001;14:91-99.
40. Zelle B, König F, Enderle A, Bertagnoli R, Dörner J. Circumferential fusion of the lumbar and lumbosacral spine using a carbon fiber ALIF cage implant versus autogenous bone graft: a comparative study. *J Spinal Disord Tech*. 2002;15:369-376.
41. Madan SS, Boeree NR. Comparison of instrumented anterior interbody fusion with instrumented circumferential lumbar fusion. *Eur Spine J*. 2003;12:567-575.
42. Oxland TR. Biomechanics of the L5/S1 junction and the effect of spondylolisthesis and spondyloptosis. In: Harms J, Stürz H, eds. *Severe Spondylolisthesis: Pathology-Diagnosis-Therapy*. Darmstadt, Germany: Steinkopff; 2002:53-66.
43. Haraldsson S, Willner S. A comparative study of spondylolisthesis in operations on adolescents and adults. *Arch Orthop Trauma Surg*. 1983;101:101-105.
44. Lusskin R. Pain patterns in spondylolisthesis. A correlation of symptoms, local pathology and therapy. *Clin Orthop*. 1965;40:123-136.
45. Meyerding HW. Low backache and sciatic pain associated with spondylolisthesis and protruded intervertebral disc: incidence, significance and treatment. *J Bone Joint Surg Am*. 1941;23:461-470.
46. Percy M, Shepherd J. Is there instability in spondylolisthesis? *Spine*. 1985;10:175-177.
47. Sherman FC, Rosenthal RK, Hall JE. Spine fusion for spondylolysis and spondylolisthesis in children. *Spine*. 1979;4:59-67.
48. Bradford DS. Spondylolysis and spondylolisthesis. *Curr Pract Orthop*. 1979;8:12-37.
49. Laurent LE, Einola S. Spondylolisthesis in children and adolescents. *Acta Orthop Scand*. 1961;31:45-64.
50. Libson E, Bloom RA, Shapiro Y. Scoliosis in young men with spondylolysis or spondylolisthesis. *Spine*. 1984;9:445-447.
51. Lindholm TS, Ragni P, Ylikoski M, Poussa M. Lumbar isthmic spondylolisthesis in children and adolescents. Radiologic evaluation and results of operative treatment. *Spine*. 1990;15:1350-1355.
52. McCarroll JR, Miller JM, Ritter MA. Lumbar spondylolysis and spondylolisthesis in college football players. *Am J Sports Med*. 1986;14:404-406.

*Annual Indexes
 for the years
 2001-2006
 are archived on
 the AJO Website.
 www.amjorthopedics.com*



Orthopaedic Trauma Association
23rd Annual Meeting
October 17 – 20, 2007
Boston, Massachusetts, USA

OTA President: Jeffrey O. Angles, MD
Annual Meeting Program Chair: Andrew H. Schmidt, MD
Annual Meeting Program Committee:

Victor A. delBichle, MD Bruce G. French, MD Stephan L. Harwin, MD Thomas A. Miceli, III, MD	Peter J. O'Brien, MD William T. Owsen, MD William M. Steele, MD David S. Rock, MD Paul Tompkins, III, MD
--	---

Meeting Highlights
SYMPOSIA:
 Current Trends in Pediatric Fracture Management;
 Fractures in the Developing World; Evidence-Based
 Approach to Bringing New Orthopaedic Devices to Market;
 Complications of Trauma; High-Energy Knee Dislocation;
OVER 70 SCIENTIFIC TRILUMINA PODIUM PRESENTATIONS
OVER 200 SCIENTIFIC POSTERS & TECHNICAL EXHIBITS
HANDS-ON SKILLS LABS:
 Metadiaphyseal Tibial Nailing;
 Nailing Proximal Femur Fractures;
 ORIF Proximal Femur Fractures and Locking Plate;
 ORIF Tibial Plated Fractures; IM Nailing Proximal Humerus;
 ORIF Distal Humeral Fractures
MINI-SYMPOSIA:
 Amputations; Study Design; Ankle Fractures; Misapplication of
 Technology; Changing Management of Open Fractures;
 The Business of Orthopaedic Trauma
CASE PRESENTATIONS:
 Breakfast with the Experts – Bring Your Difficult Cases;
 Coding in Orthopaedic Trauma: Case-based Examples;
 Upper Extremity Fractures Part I (Clavicle, Shoulder & Humeral
 Shaft) & Part II (Forearm, Wrist & Elbow); Management of
 Diaphyseal Infections and Non-unions of Long Bones;
 Ankle Complications with IM Nailing; Pelvis and Acetabular
 Fractures; New Alternatives to Bone Grafting;
 Mis-use of New Technology; Damage Control Orthopaedics
Pre-Annual Meeting Opportunities
 Basic Science Focus Forum
 Master's Level Trauma Coding & Reimbursement
 Mass Casualty Management: Principles & Practice
 Young Practitioner's Forum

21 Category I CME Credits Available

Visit <http://www.ota.org> for Preliminary Program
 and On-line Registration or contact

Orthopaedic Trauma Association
 6300 N. River Rd., #727 Rosemont, IL 60018
 Phone: (847) 698-1631 Fax: (847) 823-0536
 E-mail: OTA@aotc.org