

# Clinical Results of Minimal Screw Plate Fixation of Forearm Fractures

Bradley D. Crow, MD, Gregory Mundis, MD, and Jeffrey O. Anglen, MD

## Abstract

Traditional plating technique for forearm fractures specifies implant selection based on achieving a minimum number of "cortices" of screw fixation on either side of the fracture. Recent biomechanical data suggest that plates with fewer screws provide equivalent strength of fixation compared with standard compression plating techniques in forearm fractures. As described in this article, we retrospectively reviewed a surgeon's experience at a regional level I trauma center to evaluate the clinical outcome of this newer fixation strategy. Seventy-eight fractured bones were plated using "minimal" screw technique—less than the traditionally recommended 6 cortices of screw purchase. Nonunion or fixation failure occurred in 7 fractures (5 patients), producing a union rate of 91% (71/78). All nonunions were atrophic and occurred in open fractures with bone loss. No construct failed because of fixation loss caused by having too few screws. Minimal screw plate technique was stable fixation, despite not having 6 cortices on both sides of the fracture. Technical emphasis should be on adequate plate length rather than number of cortices of fixation in each segment.

Conventional teaching is that adequate plate fixation of a forearm fracture requires at least 6 cortices or 3 bicortical screws on either side of the fracture.<sup>1,2</sup> This guideline apparently was developed from clinical experience rather than controlled experimentation. Recent biomechanical studies using cadaveric or synthetic bones in material testing machines have not confirmed the need to use 6 screws for stability,<sup>3-5</sup> and many surgeons have modified their practice accordingly. The "minimal screw plating technique" uses fewer screws (fewer cortices) spaced wider in a longer plate. Although the effect of drilling and screw insertion

on bone biology has, to our knowledge, not been investigated in detail, it is reasonable to believe that fixation with fewer screws would be less damaging to the bone and its endosteal blood supply but would still be biomechanically sound.

However, clinical settings differ from laboratories, and models do not always accurately reflect reality. In the retrospective study described in this article, we evaluated the clinical results of minimal screw plating in treating forearm diaphyseal fractures at a single institution. Our hypothesis was that fractures treated with the minimal plating technique would have union and complication rates similar to those reported in the literature for standard plating techniques, indicating adequate stability without additional screws.

## MATERIALS AND METHODS

After obtaining institutional review board approval, we reviewed all forearm fractures treated under supervision of Dr. Anglen at a level I trauma center between September 1992 and October 2002. Single- and both-bone forearm fractures were included, as were Monteggia and Galeazzi injuries. One hundred patients were identified through a search of the Orthopaedic Trauma Service database for Orthopaedic Trauma Association (OTA) type 22 fractures. Thirteen were treated by methods other than compression plate fixation, and 26 were lost to follow-up before healing or failure—leaving 61 patients with 101 diaphyseal radius and ulna fractures treated using limited-contact dynamic compression plates. Mean patient follow-up was 11.5 months (range, 38 days to 5 years 1 month).

At time of review, the 101 fractures were categorized into 2 groups, minimal screw plate fixation (78 fractures) and standard plate fixation (23 fractures). Minimally plated fractures were defined as those having at least 1 segment with fewer than 6 cortices of screw purchase, but with a typical or longer plate length—for example, at least 3 plate holes with 2 screws on one side of the fracture. Standard plate fixation was defined as those with 6 cortices of screw purchase or more in each segment of fractured bone (Figure 1). Lag screws were used when possible, with either technique. Mean ratios of screws to plate holes were 0.63 (minimally plated fractures) and 0.88 (standard plating). The most commonly used plate configuration in minimally plated fractures was a 7-hole plate with 4 screws (Figure 2). The surgical technique was chosen at time of surgery

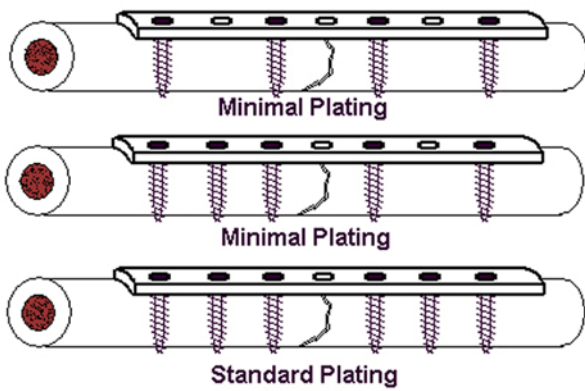
Dr. Crow is Fellow, Department of Orthopaedics, Scripps Clinic, La Jolla, California. He was Resident Physician, Department of Orthopaedics, University of Missouri-Columbia, Columbia, Missouri, at the time the article was written.

Dr. Mundis is Resident Physician, Department of Orthopaedics, University of Oklahoma, Oklahoma City, Oklahoma.

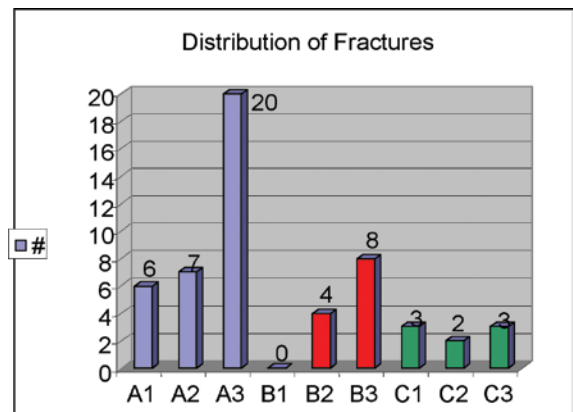
Dr. Anglen is Professor and Chairman, Department of Orthopaedics, Indiana University, Indianapolis, Indiana.

Requests for reprints: Jeff Anglen, MD, 541 Clinical Drive, Suite 600, Indianapolis, IN, 46202 (tel, 317-274-7913; fax, 317-274-3702; e-mail, janglen@iupui.edu).

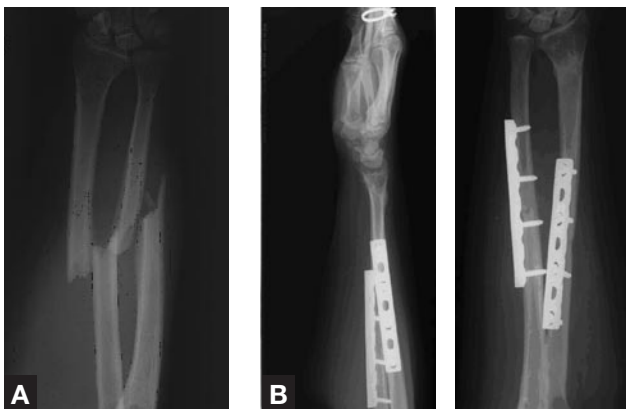*Am J Orthop.* 2007;36(9):477-480. Copyright Quadrant HealthCom Inc. 2007. All rights reserved.



**Figure 1.** Examples of minimal and standard plate fixation.



**Figure 3.** Distribution of fracture types (OTA Classification) in 53 patients treated with minimal plate fixation.

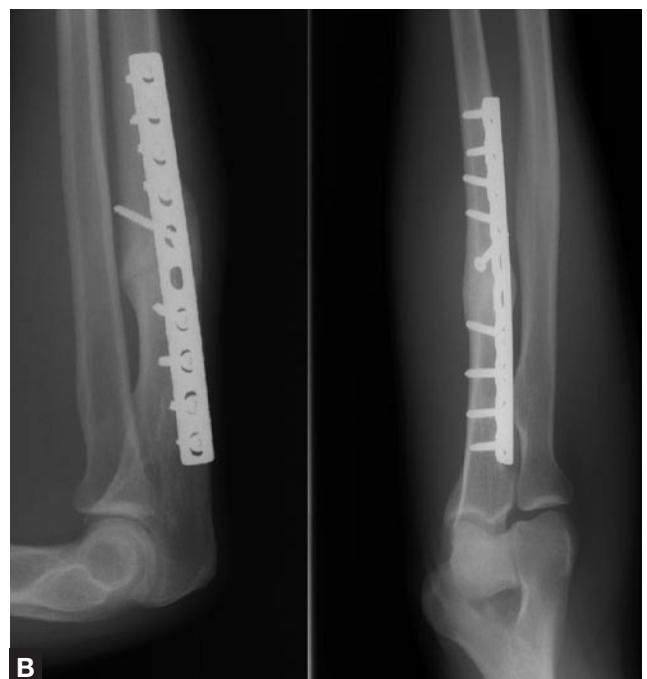
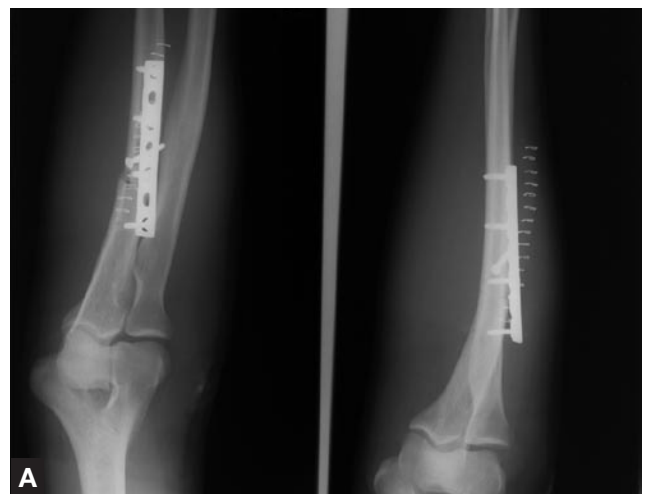
**Figure 2.** (A) Injury film of a 58-year-old woman with a left forearm fracture of both bones. (B) Three-month follow-up radiographs of healed fractures using minimal fixation.

by the operating surgeon (Dr. Anglen), without protocol and before the issue was the object of a study. There were no clearly identified reasons for choosing between the techniques; at that time, the preferred technique was evolving toward minimal plate fixation.

The OTA/OA (Arbeitsgemeinschaft für Osteosynthesefragen) system<sup>6</sup> was used to classify all fracture patterns. Figure 3 shows the distribution of fracture types in the 53 patients (27 males, 26 females) treated with minimal plate fixation. Of the 78 fractured bones treated with minimal screw plating, 22 (28%) were open, and 56 (72%) were closed. The Gustilo-Anderson system<sup>7</sup> was used to classify the open fractures; 4 were grade I fractures, 10 were grade II fractures, 2 were grade IIIA fractures, 3 were grade IIIB fractures, and 3 were grade IIIC fractures. Mean age was 32 years (range, 12-79 years).

Fractures were evaluated for union and complications, type of nonunion, hardware or fixation failure, infection, neurovascular injury caused by surgery, and radioulnar synostosis. Nonunion was defined as any fracture that failed to unite by 6 months without additional surgical intervention.



**Figure 4.** (A) Immediate hardware failure due to inadequate plate length in an isolated ulna fracture. (B) Radiographs 10 months after revision to a longer plate reveal a united fracture.

## RESULTS

Fixation failure occurred in 1 fracture, and nonunion occurred in 6 open fractures. The fixation failure occurred early because of a technical error: inadequate plate length (2 holes) on one side of the fracture (Figure 4A). The patient did well after revision to a longer plate spanning the fracture (Figure 4B). The 6 nonunions (4 patients) were atrophic nonunions caused by bone loss. Of the 4 patients, 1 had a grade II injury, 1 had a grade IIIB near-complete amputation, and 2 had grade IIIC injuries. One of the nonunions was associated with hardware failure: Both screws on one side of the fracture broke. There were no cases of fixation loss caused by screw pullout or loosening in these nonunions. The 2 grade IIIC injuries that failed to unite initially were successfully treated with autologous iliac crest bone grafting procedures alone; the grade II injury that initially failed to unite was successfully treated with a Suave-Kapandji procedure; and the patient with the grade IIIB injury refused revision surgery.

fixation requires attachment of the plate to the major bone segments with at least 6 “cortices,” usually taken to mean 3 or 4 bicortical screws.<sup>1,2,10</sup> This dictum focuses attention on splint (plate) coupling rather than on plate length.

Results from a recent biomechanical study, in which Sanders and colleagues<sup>4</sup> used cadaveric ulnae, suggest that this teaching is incorrect or at least incomplete. The authors found that fixation constructs using 8- and 10-hole plates with 4 screws were at least as strong as, or stronger than, a 6-hole plate with 6 screws. They concluded that plate length, not number of screws, was the most important factor in stability. In our laboratory, similar experiments using cadaveric tibiae had the same results (unpublished data). Based on biomechanical investigations, Törnkvist and colleagues<sup>5</sup> concluded that “wider spacing of bone screws increases the bending strength of screw-plate fixation and can be more effective than increasing the number of screws.”

**“The emphasis should be on adequate plate length and sufficient screw fixation, not on a predetermined number of cortices of fixation in each segment.”**

Complications also included 3 implant infections (2 patients), 1 radioulnar synostosis, and 1 minor postoperative sensory nerve deficit in the thumb tip. The synostosis was taken down with no long-term sequelae. One infection occurred after surgical treatment of a closed ulnar fracture. The fracture healed and the infection was successfully treated with plate removal and antibiotics. The other infection occurred shortly after the initial operation in the grade IIIB near-amputation injury and was treated with multiple irrigations, intravenous antibiotics, antibiotic beads, and hardware retention. The overall union rate in fractures treated with minimal plate fixation was 91% (71/78).

## DISCUSSION

Options for fixation of diaphyseal radius and ulna fractures include casting, external fixation, and internal fixation with intramedullary nails or plates.<sup>1,2,8-10</sup> Plate-and-screw fixation has proved to be the most reliable and successful strategy and is widely used. Clinical results in plating fractures of the forearm bones have been excellent (union rates,  $\geq 90\%$ ).<sup>11-14</sup> Successful plate fixation of these fractures allows for early return to function of the upper extremity.

The plate functions as a nongliding splint to protect lag screws (neutralization), to provide dynamic compression, or to bridge comminuted segments. The plate maintains the position of the bones against deforming forces (primarily muscle contraction) to allow early function and healing without deformity. The efficacy of mechanical function for a splint depends on splint length and security of splint–bone coupling. When the technique of plate fixation of forearm fractures is taught, it is often stated that stable

Drilling screw holes in cortical bone mechanically weakens the bone.<sup>15-17</sup> There may also be detrimental biological effects, through interruption of the endosteal blood supply, generation of drilling heat, and alteration of bone structure. Each screw placement poses some small risk to the bone—comminution, malpositioning, stripping, broken drill bit—and some cost. Therefore, unnecessary screw placement should be avoided. Mast<sup>18</sup> made the analogy that, just as the internist should prescribe the correct dose of a medication, the orthopedist should prescribe the correct “dose” of screws for stable fixation (adverse effects can result from using either too few or too many screws).

In the present study, we found that minimal screw plate fixation (<6 cortices on both sides of the fracture) was adequate fixation when adequate plate length was obtained. More than three fourths of the radius and ulna fractures treated at our institution during this period were fixed with the minimal screw technique, which by old measures would have been considered inadequate. Few of these procedures failed in the sense of nonunion or fixation failure, and none of the failures resulted from using too few screws. All 6 nonunions (4 grade III) were in open fractures with bone loss. These nonunions were atrophic, indicating an etiology of deficient vascularity, rather than hypertrophic, which would have indicated insufficient stability. The healing rate was similar to that found in other series using 6 cortices on both sides of the fracture, which suggests that adding screws to the cases in our series would not have improved outcomes. These nonunions resulted from biological compromise associated with soft-tissue injury rather than from mechanical deficiencies. One fixation loss in this series occurred in

a proximal ulna fracture early after surgery—the cause being a technical error, using a plate that was too short. In 1 nonunion, 2 screws failed from fatigue after 9 months; it is unlikely that adding another screw would have prevented this failure. The emphasis should be on adequate plate length and sufficient screw fixation, not on a predetermined number of cortices of fixation in each segment.

The present study has several weaknesses. The most obvious are its retrospective design and its lack of a control or comparison group. In addition, many useful parameters, such as functional outcomes and ability to return to work or school, could not be reliably assessed. Nonetheless, we believe that this study provides clinical verification that a minimal plate technique—using fewer, more widely spaced screws in plates of adequate length—is stable fixation for radius and ulna diaphyseal fractures.

### AUTHORS' DISCLOSURE STATEMENT

The authors report no actual or potential conflict of interest in relation to this article.

### REFERENCES

1. Heim D. Forearm shaft fractures. In: Ruedi TP, Murphy WM, eds. *AO Principles of Fracture Management*. New York, NY: Thieme; 2000:341-355.
2. Jupiter JB, Kellam JF. Diaphyseal fractures of the forearm. In: Browner BD, Jupiter JB, Levine AM, Trafton PG, eds. *Skeletal Trauma: Fractures, Dislocations, and Ligamentous Injuries*. Philadelphia, Pa: Saunders; 2003:1363-1403.
3. ElMaraghy AQ, ElMaraghy MW, Nousiainen M, Richards RR, Schemitsch EH. Influence of the number of cortices on the stiffness of plate fixation of diaphyseal fractures. *J Orthop Trauma*. 2001;15:186-191.
4. Sanders R, Haidukewych GJ, Milne T, Dennis J, Latta LL. Minimal versus maximal plate fixation techniques of the ulna: the biomechanical effect of number of screws and plate length. *J Orthop Trauma*. 2002;16:166-171.
5. Törnkvist H, Hearn TC, Schatzker J. The strength of plate fixation in relation to the number and spacing of bone screws. *J Orthop Trauma*. 1996;10:204-208.
6. Müller ME, Nazarian S, Koch P, Schatzker J. *The Comprehensive Classification of Fractures of Long Bones*. New York, NY: Springer-Verlag; 1990.
7. Gustilo RB, Merkow RL, Templeman DC. Current concepts review: the management of open fractures. *J Bone Joint Surg Am*. 1990;72:299-303.
8. Richards RR. Fractures of the shafts of the radius and ulna. In: Buchholz RW, Heckman JD, eds. *Rockwood and Green's Fractures in Adults*. Philadelphia, Pa: Lippincott Williams & Wilkins; 2002:869-920.
9. Sarmiento A, Latta LL. Fractures of the forearm. In: Sarmiento A, Latta LL, eds. *Closed Functional Treatment of Fractures*. Berlin, Germany: Springer-Verlag; 1981:381-495.
10. Schemitsch EH. Forearm fractures. In: Kellam JF, Fischer TJ, Tornetta P, Bosse MJ, Harris MB, eds. *Orthopaedic Knowledge Update: Trauma 2*. Rosemont, Ill: American Academy of Orthopaedic Surgeons; 2000:53-63.
11. Anderson LD, Sisk TD, Tooms RE, Park WI. Compression-plate fixation in acute diaphyseal fractures of the radius and ulna. *J Bone Joint Surg Am*. 1975;57:287-296.
12. Chapman MW, Gordon JE, Zissimos AG. Compression-plate fixation of acute fractures of the diaphyses of the radius and ulna. *J Bone Joint Surg Am*. 1989;71:159-169.
13. Hertel R, Pisan M, Lambert S, Ballmer FT. Plate osteosynthesis of diaphyseal fractures of the radius and ulna. *Injury*. 1996;27:545-548.
14. Stern PJ, Drury WJ. Complications of plate fixation of forearm fractures. *Clin Orthop*. 1983;175:25-29.
15. Brooks DB, Burstein AH, Frankel VH. The biomechanics of torsional fractures: the stress concentration effect of a drill hole. *J Bone Joint Surg Am*. 1970;52:507-514.
16. Burstein AH, Currey J, Frankel VH, Heiple KG, Lunseth P, Vessely JC. Bone strength: the effect of screw holes. *J Bone Joint Surg Am*. 1972;54:1143-1156.
17. Laurence M, Freeman MAR, Swanson SAV. Engineering considerations in the internal fixation of fractures of the tibial shaft. *J Bone Joint Surg Br*. 1969;51:754-768.
18. Mast J. Preoperative planning. Excerpt from special guest lecture presented at: AO Principles of Fracture Management Resident Course; January 2003; Reno, Nevada.

## 2007 Resident Writer's Award

The 2007 Resident Writer's Award competition is sponsored through an unrestricted grant provided by DePuy, a Johnson & Johnson company. Orthopedic residents are invited to submit original studies, reviews, or case studies for publication. Papers published in 2007 will be judged by *The American Journal of Orthopedics* Editorial Board. Honoraria will be presented to the winners at the 2008 AAOS annual meeting.

\$1,500 for the First-Place Award

\$1,000 for the Second-Place Award

\$500 for the Third-Place Award

To qualify for consideration, papers must have the resident as the first-listed author and must be accepted through the journal's standard blinded-review process.

Papers submitted in 2007 but not published until 2008 will automatically qualify for the 2008 competition.

Manuscripts should be prepared according to our Information for Authors and submitted via our online submission system, Editorial Manager®, at [www.editorialmanager.com/AmJOrthop](http://www.editorialmanager.com/AmJOrthop).

Through an unrestricted grant provided by

