

The Acorn Beath Couple: Articular Salvation for Double-Bundle Femoral Tunnels in Cruciate Ligament Reconstruction

Yuri M. Lewicky, MD

Abstract

With the recent increase in interest in arthroscopic double-bundle cruciate reconstructions, efficient, safe, and reproducible techniques are needed.

This technical trick is applicable to both arthroscopic anterior cruciate ligament (ACL) and posterior cruciate ligament (PCL) reconstruction when double-bundle femoral tunnels are performed through an accessory far lateral or far medial incision as with the all-inside femoral tunnel drilling approach.

A standard double-bundle cruciate reconstruction technique is applied until placement of the femoral footprint Beath pins in anticipation of tunnel drilling. Femoral footprint targeting with a Beath pin requires use of a far accessory portal. Before the long Beath pin is introduced into the joint, an acorn reamer is placed over the Beath pin to within 5 mm of the pin tip, thus creating an acorn Beath couple. The eyelet pin end is loaded onto a quick-release pin collet driver, leaving the acorn reamer free to turn. The acorn Beath couple is then introduced into the appropriate accessory portal and positioned in the center of the desired femoral footprint. An assistant holds the acorn reamer shaft while the Beath pin is advanced. The collet driver is then disengaged from the pin and replaced with an adjustable chuck and secured to the acorn reamer shaft of the acorn Beath couple.

The femoral tunnel is drilled to the appropriate depth, and the Beath pin is pulled out the anterior thigh. Doing so disengages the acorn reamer and allows for safe removal of the reamer from the notch. The technique is then repeated with the coupling of a 4.5 Endobutton reamer and the Beath pin.

Recent literature supports the finding that long-term outcomes after anterior cruciate ligament (ACL) reconstruction are less successful than previously thought. Some patients develop significant arthritic changes after 10 years.¹⁻⁴ Because of less than perfect results, the single-bundle ACL reconstruction has been called into question. Whether the arthritic changes are caused by the initial injury itself or by partial restoration of normal knee kinematics as occurs with single-bundle reconstruction is a matter of debate.

Therefore, researchers have begun to focus on cartilage preservation and anatomical reconstruction of the native 2 bundles in the ACL. Although no long-term clinical data support better results with double-bundle ACL reconstruction, biomechanical data have shown that double-bundle reconstruction more closely recreates

“...double-bundle reconstruction more closely recreates normal knee kinematics with respect to translation and rotation.^{5,6}”

normal knee kinematics with respect to translation and rotation.^{5,6} In addition, it is well known that iatrogenic cartilage lesions are a frequent complication of knee arthroscopy and that simple grade II lesions (International Cartilage Research Society)⁷ never go away.⁸

The technique described here is useful for both ACL and posterior cruciate ligament (PCL) double-bundle reconstruction with proximal Endobutton CL (Smith & Nephew Inc, Andover, MA) fixation. The focus of this technique is on allowing for proper footprint targeting while protecting the articular surfaces of the femoral condyles. Lack of intraoperative articular surface protection may further lead to poorer long-term results after ACL and PCL reconstruction. In addition, less experienced surgeons may sacrifice the desired footprint of the bundle for fear of causing iatrogenic harm to the cartilage surface. The acorn Beath couple minimizes this possibility.

Dr. Yuri Lewicky is an Orthopaedic Surgeon specializing in arthroscopy and reconstruction of the shoulder and knee at Summit Center Sports Medicine and Northern Arizona Orthopaedics, Flagstaff, Arizona.

Requests for reprints: Yuri M. Lewicky MD, Summit Center Northern Arizona Orthopaedics, 1485 N Turquoise Dr, Suite 200, Flagstaff, AZ 86001 (tel, 800-773-2553; fax, 928-226-3083; e-mail, lewickyy@summitctr.net).

Am J Orthop. 2007;36(12):648-651. Copyright Quadrant HealthCom Inc. 2007. All rights reserved.

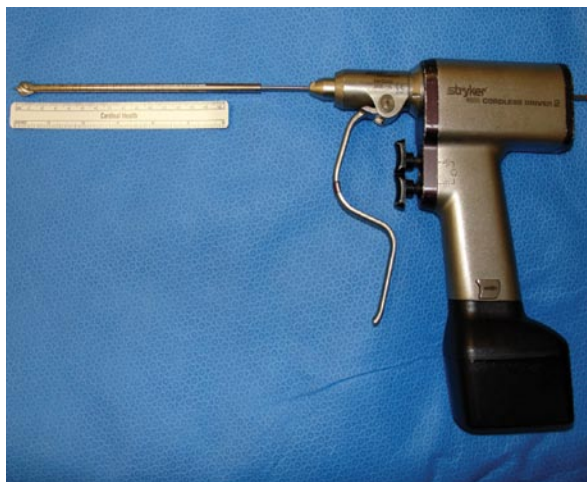

Figure 1. The acorn Beath couple, composed of an acorn reamer placed over a long Beath pin to within 5 mm of the pin tip and attached to a quick-release driver.

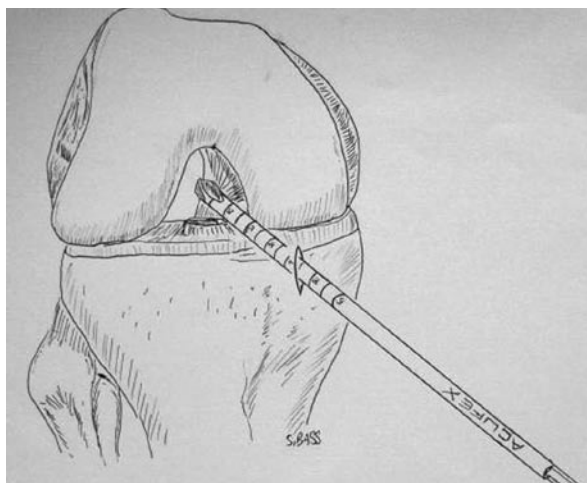


Figure 2. Artistic rendition of the acorn Beath couple placed into the joint as a unit through the accessory portal (posterolateral bundle in anterior cruciate ligament reconstruction, as depicted).

TECHNIQUE

This technique is applicable to both arthroscopic ACL and PCL reconstruction when double-bundle femoral tunnels are performed through a single medial incision, as with the all-inside femoral tunnel drilling approach. A standard double-bundle cruciate reconstruction technique is applied until placement of the femoral footprint Beath pins in anticipation of tunnel drilling.⁹⁻¹² Footprint targeting with a Beath pin in cruciate double-bundle reconstruction requires use of the far accessory medial portal for posterolateral bundle creation in ACL reconstruction and of the accessory lateral portal for posteromedial and anterolateral bundle creation in PCL reconstruction.

Before the Beath pin is introduced into the joint, a graft-sized acorn reamer is placed over a long Beath pin to within 5 mm of the pin tip, thus creating an acorn Beath couple (Figure 1). Note that the Beath pin allows for reamer insertion from the eyelet end only. Last, the

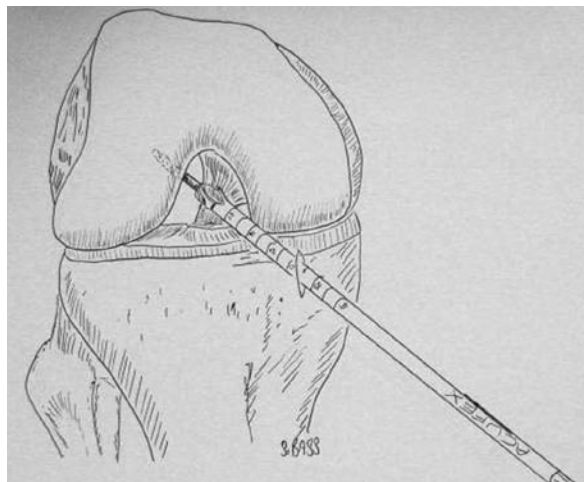


Figure 3. Artistic rendition of advancement of the Beath pin into the center of the femoral footprint with the acorn reamer free and its tip pulled back 5 mm.

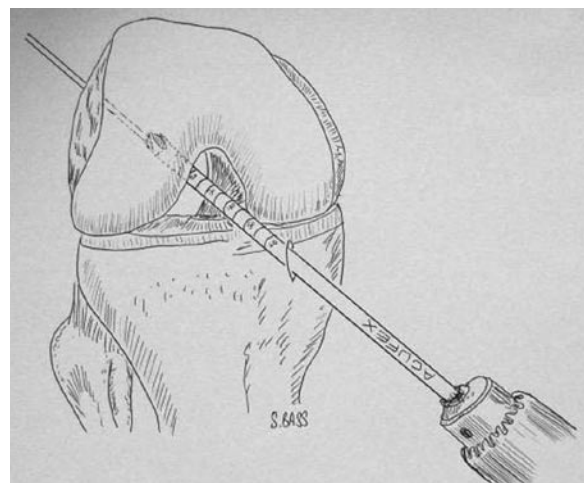


Figure 4. The collet driver is replaced with an adjustable chuck, secured to the acorn reamer, and the femoral tunnel is drilled to the appropriate depth.

eyelet pin end is loaded onto a quick-release pin collet driver, leaving the acorn reamer free to turn between the Beath pin tip and the driver. The acorn Beath couple is introduced into the far medial or lateral accessory portal, depending on the procedure being performed (Figure 2). The Beath pin tip is then positioned in the center of the properly selected femoral footprint. For posterolateral bundle placement in ACL reconstruction, this corresponds to the 3:15 position and just anterior to the anteromedial bundle tunnel (left knee).¹³⁻¹⁵ For PCL reconstruction, the anterolateral and posteromedial bundles have the center of their footprints 7 mm and 14 mm inferior to the intercondylar roof and 7 mm and 4 mm posterior to the anterior articular margin, respectively.¹⁶ Before pin advancement, care is taken to ensure that the acorn reamer is not against the footprint or the articular cartilage of the contralateral femoral condyle. An assistant holds the interposed acorn reamer shaft with a wet Ray-Tec sponge or sterile towel to prevent

inadvertent reamer spin and possible PCL or ACL damage with Beath pin drilling. The Beath pin is advanced into the femoral footprint with the knee hyperflexed to allow for anterior pin exit in the coronal plane (Figure 3). The collet driver is then disengaged from the pin and replaced with an adjustable chuck and secured to the acorn reamer shaft of the acorn Beath couple. The femoral tunnel is then drilled to the appropriate depth to allow for Endobutton deployment and at least 20 mm of residual graft in the tunnel (Figure 4). Care should be taken not to blow out the distal femoral cortex. The pin is then pulled out the anterior thigh, thus disengaging the acorn reamer and allowing for safe removal of the reamer from the notch. Alternatively, initial advancement of the Beath pin to the limit of the far distal femoral cortex can be performed with subsequent removal of the acorn Beath couple in a distal fashion after proper acorn

cartilage of the medial femoral condyle at significant risk. A far medial portal is required to obtain correct footprint placement at the expense of placing the Beath pin tangential to, and almost juxtaposed with, the articular surface of the condyle. The reverse is true for double-bundle PCL reconstruction, in which drilling both the posteromedial and anterolateral bundle femoral tunnels places the articular cartilage of the lateral femoral condyle at significant risk. The acorn Beath couple minimizes this risk by entering the far accessory portal already coupled. In doing so, the reamer tip is not placed over a Beath pin that is already fixed in place and tangential to the articular surface. This allows for less cartilage damage and more consistent footprint targeting. In addition, the shaft of the free acorn reamer coupled to the Beath pin prevents damage caused by small surface area contact forces and chondral thermal changes seen with a fast-spinning pin.

“...the importance of iatrogenic cartilage damage prevention has become clearer, as our ability to restore damaged cartilage to normal has proved more difficult.”

reaming. This decreases the risk for additional anterior skin pin punctures. A 4.5 Endobutton reamer Beath pin couple is then placed into the far accessory portal and associated tunnel, with the pin exiting the previous skin puncture. The tunnel is completed with bicortical drilling of the condyle with the 4.5 reamer. Before the reamer is removed from the intercondylar notch, a doubled-over No. 1 polydioxanone suture is inserted into the Beath pin eyelet, and the pin is pulled out the anterior thigh, leaving a graft suture shuttle in place. The reamer, now free, allows for safe removal from the joint.

In double-bundle PCL reconstruction, this procedure is repeated for the femoral tunnel of the second bundle. After the femoral tunnel or tunnels are created, a standard technique for completing the double-bundle ACL reconstruction⁹⁻¹¹ or PCL reconstruction¹² is used.

DISCUSSION

Preservation of the articular surface of the knee is paramount as the population continues to express a desire to remain physically active longer, even after injury. The effect of having less than normal knee kinematics on the ability to remain osteoarthritic free and thus physically active is now being elucidated.¹⁻⁴ Furthermore, the importance of iatrogenic cartilage damage prevention has become clearer, as our ability to restore damaged cartilage to normal has proved more difficult. Double-bundle cruciate reconstruction techniques are an attempt to more closely reapproximate normal knee ligament anatomy and kinematics when dealing with cruciate tears.^{9-12,16}

For double-bundle ACL reconstructions, drilling the posterolateral bundle femoral tunnel places the articular

For an all-inside femoral tunnel double-bundle technique, the Endobutton provides excellent fixation. Studies have shown that the Endobutton has equivalent outcome scores when tested against other femoral fixation devices as well as near superior fixation biomechanics with respect to ultimate load to failure and construct slippage.¹⁶⁻¹⁸ Its size and maneuverability obviate the need for angled screwdrivers and avoid traumatic insertion of screw threads past the articular surfaces of the femoral condyles.

CONCLUSIONS

The acorn Beath couple is a safe and effective way to protect articular surfaces from iatrogenic harm while allowing for footprint targeting. This technique has been perfected in the laboratory with cadaver double-bundle cruciate reconstructions and has been applied in the clinical setting as well, without complication. I have been quite pleased with the resulting lack of articular surface damage.

AUTHOR'S DISCLOSURE STATEMENT AND ACKNOWLEDGMENTS

The author reports no actual or potential conflict of interest in relation to this article.

A special thank you to Shane Bass for his artistic renditions and technical assistance. Thanks also to the San Diego Sports Medicine and Arthroscopy fellowship mentors who instilled in me a new appreciation for the fragility of articular cartilage and for the lasting trail that an inexperienced arthroscopist can leave. The signature of the best surgeons is written with invisible ink.

REFERENCES

- Ristanis S, Stergiou N, Patras K, Vasiliadis HS, Giakas G, Georgoulis AD. Excessive tibial rotation during high-demand activities is not restored by anterior cruciate ligament reconstruction. *Arthroscopy*. 2005;21(11):1323-1329.
- Leitze Z, Losee RE, Jokl P, Johnson TR, Feagin JA. Implications of the pivot shift in the ACL-deficient knee. *Clin Orthop*. 2005;(436):229-236.
- Jonsson H, Riklund-Ahlstrom K, Lind J. Positive pivot shift after ACL reconstruction predicts later osteoarthritis: 63 patients followed 5-9 years after surgery. *Acta Orthop Scand*. 2004;75(5):594-599.
- Andriacchi TP, Briant PL, Beville SL, Koo S. Rotational changes at the knee after ACL injury cause cartilage thinning. *Clin Orthop*. 2006;(442):39-44.
- Amis AA, Bull AM, Lie DT. Biomechanics of rotational instability and anatomic anterior cruciate ligament reconstruction. *Oper Tech Orthop*. 2005;15:29-35.
- Yasuda K, Kondo E, Ichiyama H, Tanabe Y, Tohyama H. Clinical evaluation of anatomic double-bundle anterior cruciate ligament reconstruction procedure using hamstring tendon grafts: comparisons among 3 different procedures. *Arthroscopy*. 2006;22(3):240-251.
- Farr J, Lewis P, Cole BJ. Patient evaluation and surgical decision making. *J Knee Surg*. 2004;17(4):219-228.
- Klein W, Kurze V. Arthroscopic arthropathy: iatrogenic arthroscopic joint lesions in animals. *Arthroscopy*. 1986;2(3):163-168.
- Zelle BA, Brucker PU, Feng MT, Fu FH. Anatomical double-bundle anterior cruciate ligament reconstruction. *Sports Med*. 2006;36(2):99-108.
- Yasuda K, Kondo E, Ichiyama H, Tanabe Y, Tohyama H. Surgical and biomechanical concepts of anatomic anterior cruciate ligament reconstruction. *Oper Tech Orthop*. 2005;15:96-102.
- Vidal AF, Brucker PU, Fu FH. Anatomic double-bundle anterior cruciate ligament reconstruction using tibialis anterior tendon allografts. *Oper Tech Orthop*. 2005;15:140-145.
- Yoon KH, Bae DK, Song SJ, Lim CT. Arthroscopic double-bundle augmentation of posterior cruciate ligament using split Achilles allograft. *Arthroscopy*. 2005;21(2):1436-1442.
- Mochizuki T, Muneta T, Nagase T, Shirasawa S, Akita K, Sekiya I. Cadaveric knee observation study for describing anatomic femoral tunnel placement for two-bundle anterior cruciate ligament reconstruction. *Arthroscopy*. 2006;22(4):356-361.
- Harner CD, Baek GH, Vogrin TM, Carlin GJ, Kashiwaguchi S, Woo SL. Quantitative analysis of human cruciate ligament insertions. *Arthroscopy*. 1999;15(7):741-749.
- Zantop T, Petersen W, Fu FH. Anatomy of the anterior cruciate ligament. *Oper Tech Orthop*. 2005;15:20-28.
- Petersen W, Lenschow S, Weimann A, Strobel MJ, Raschke MJ, Zantop T. Importance of femoral tunnel placement in double-bundle posterior cruciate ligament reconstruction biomechanical analysis using a robotic/universal force-moment sensor testing system. *Am J Sports Med*. 2006;34(3):456-463.
- Ahmad CS, Gardner TR, Groh M, Arnouk J, Levine WN. Mechanical properties of soft tissue femoral fixation devices for anterior cruciate ligament reconstruction. *Am J Sports Med*. 2004;32(3):635-640.
- Kousa P, Jarvinen TL, Vihavainen M, Kannus P, Jarvinen M. The fixation strength of six hamstring tendon graft fixation devices in anterior cruciate ligament reconstruction. Part I: femoral site. *Am J Sports Med*. 2003;31(2):174-181.

You are invited to attend a CME dinner symposium

VTE Prophylaxis

DECIPHERING THE GUIDELINES

Faculty

Chair: Peter D. McCann, MD
Clifford W. Colwell, Jr, MD
Javad Parvizi, MD
Giles R. Scuderi, MD

The Westin San Francisco Market Street
50 Third Street
San Francisco, California
Meeting Room: Metropolitan Ballroom
Thursday, March 6, 2008
6:45 PM to 9:15 PM

This activity is jointly sponsored by the Annenberg Center for Health Sciences and Quadrant Medical Education

Supported by an independent educational grant from sanofi-aventis U.S.

Look for registration information in the January issue of *The American Journal of Orthopedics*.

