

# Rupture of the Flexor Digitorum Profundus in a Preadolescent Boy

Justin B. Hohl, MD, Joshua E. Hyman, MD, and Robert J. Strauch, MD

**A**vulsion of the insertion of the flexor digitorum profundus (FDP) has been described in adults since 1891,<sup>1</sup> but avulsions of the profundus tendon have seldom been described in patients younger than 14 years. In this report, we describe a ring finger profundus tendon rupture in a prepubertal 11-year-old boy and call attention to the possibility of FDP rupture in the skeletally immature population.

## BACKGROUND

In 1933, McMaster<sup>2</sup> found that tendon is the strongest element of the musculotendinous connection and that rupture occurs either at the musculotendinous junction or at the insertion of tendon into bone. Rupture of the tendon itself occurs only when the structure of the tendon has been altered by trauma or disease. McMaster determined experimentally that normal tendon is more likely to rupture at the insertion into bone than at the musculotendinous junction.

The mechanism of injury in FDP avulsion is typically forceful passive hyperextension of the distal interphalangeal (DIP) joint when the profundus is maximally contracted. This classically occurs in football and rugby players who grasp the jersey of an opponent in an attempt to tackle; as the opponent resists, the extending force avulses the contracted profundus tendon. This force can either separate the tendinous insertion from bone or tear off a fragment of the distal phalanx in addition to the tendinous insertion.

For multiple reasons, there is a propensity for profundus avulsions of the ring finger compared with other fingers. Gunter<sup>3</sup> proposed that the ring finger is more susceptible because of the presence of a common flexor muscle belly of the profundus to the little, ring, and middle fingers. Manske and Lesker<sup>4</sup> demonstrated that the insertion of the FDP into the ring finger is anatomically weaker than in the

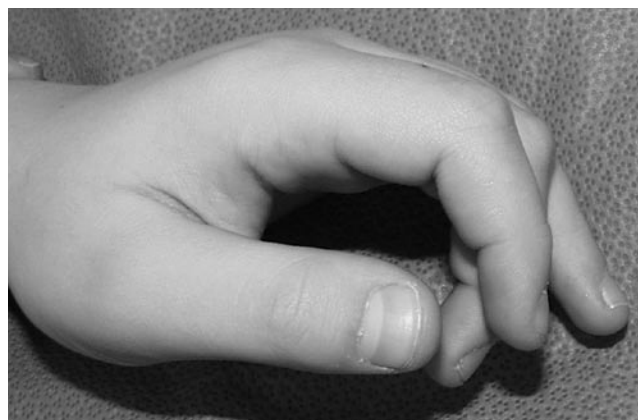middle finger. As others have postulated, that there is no independent extension of the ring finger when the other fingers are tightly flexed makes it more susceptible to hyperextension injury when the finger is flexed.<sup>5,6</sup> Another investigation demonstrated that, in 90% of subjects, the ring fingertip is 5 mm more prominent than any other digit during grip, and it absorbs more force than the other fingers on pull-away testing.<sup>7</sup>

Many of the reports of FDP avulsion have described this injury in teenage athletes, though there is a wide range of patient ages reported. A review of 10 reports of FDP avulsion revealed that the youngest patient reported in these studies was 12 and the oldest 79.<sup>3,5-13</sup> There was a total of 226 cases reported in these 10 studies, and mean age for the studies that reported mean age was 30.9 years (Table). In the present report, we describe a patient who we believe to be the youngest with an avulsion of the FDP.

## CASE REPORT

This patient was an 11-year-old prepubertal boy who closed his left ring finger in a door at home and then pulled the finger out, forcefully hyperextending the DIP joint. The boy reported being unable to flex the DIP joint after this trauma, as well as pain and swelling of the entire ring finger.

On physical examination, the patient's left ring finger was ecchymotic and swollen. He had full range of motion on active flexion of the proximal interphalangeal joint of the ring finger, but active flexion of the DIP joint was absent and produced pain in the palm (Figure 1). There was tenderness along the entire course of the flexor tendon sheath. Two-point discrimination was normal on the entire left hand, except at the distal tip of the ring finger.



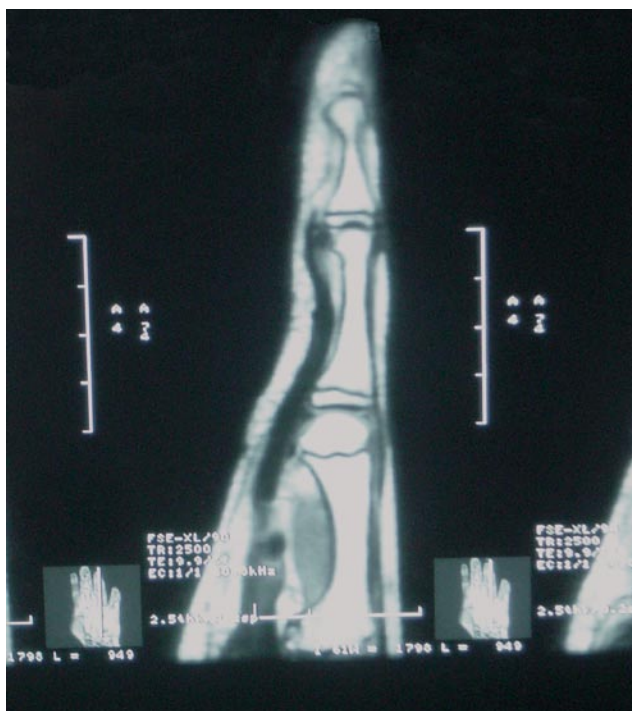
**Figure 1.** Absence of ring finger flexion at the distal interphalangeal (DIP) joint.

Dr. Hohl is Resident, Department of Orthopaedic Surgery, University of Pittsburgh Medical Center, Pittsburgh, Pennsylvania.

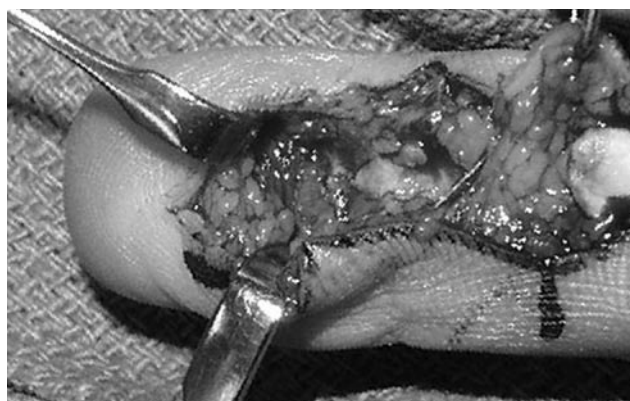
Dr. Hyman is Associate Professor of Clinical Orthopaedic Surgery, and Dr. Strauch is Professor of Clinical Orthopaedic Surgery, Columbia University College of Physicians and Surgeons, New York, New York.

Address correspondence to: Robert J. Strauch, MD, Columbia University College of Physicians and Surgeons, 622 West 168<sup>th</sup> St, New York, NY 10032 (tel, 212-305-4272; fax, 212-305-4040; e-mail, rjs8@columbia.edu).

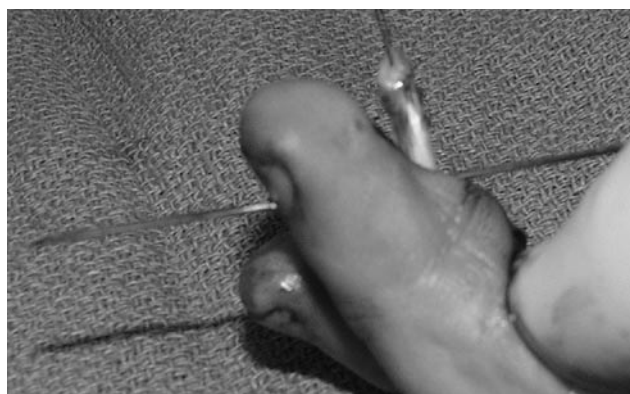*Am J Orthop.* 2008;37(4):210-212. Copyright Quadrant HealthCom Inc. 2008. All rights reserved.



**Figure 2.** Magnetic resonance image (MRI) of ring finger with detached flexor digitorum profundus (FDP).



**Figure 3.** Ruptured flexor digitorum profundus (FDP).



**Figure 4.** Flexor digitorum profundus (FDP) tendon prepared for attachment.

Because of extreme tenderness and the patient’s reticence to actively flex the finger, a digital local anesthetic block was performed in the office, and without pain he was still unable to flex the DIP joint.

Anteroposterior and lateral x-rays of the left hand and ring finger showed no evidence of fracture. A magnetic resonance imaging (MRI) scan showed that the FDP was detached from the base of the distal phalanx and retracted to the distal palm (Figure 2).

Eight days after injury, surgery was performed with a zigzag incision over the distal phalanx. The FDP was found to be completely ruptured from the distal phalanx along with the periosteum in the area of its normal insertion (Figure 3). There was no evidence of bone avulsion, and the growth plate was intact.

Further proximal dissection revealed that both slips of the FDS were intact. Using a small curved clamp down the sheath, distal to proximal, we withdrew the FDP without making a proximal counterincision. A 0.045-inch Kirschner wire was used to drill a hole through the distal phalanx to a dorsal exit through the sterile nail matrix (Figure 4). The tendon was then repaired to the bone with 3.0 polypropylene suture and a button repair over the nail plate. Dorsal blocking splint was applied. The patient began occupational therapy 1 week after surgery.

**Table. Studies of FDP Avulsion Included in This Review**

Author	Year	Study Size	Youngest Patient's Age (y)	Oldest Patient's Age (y)	Mean Age
Boyes <sup>8</sup>	1960	78	16	61	41
Gunter <sup>3</sup>	1960	8	15	30	21
Carroll <sup>9</sup>	1970	35	N/A	N/A	29
Chang <sup>10</sup>	1972	20	14	50	25
Folmar <sup>11</sup>	1972	10	35	79	55
Wenger <sup>5</sup>	1973	4	17	18	18
Leddy <sup>6</sup>	1977	36	(13)	N/A	16
Reef <sup>12</sup>	1977	21	N/A	N/A	28
Lunn <sup>13</sup>	1984	9	14	28	19
Bynum <sup>7</sup>	1988	5	12	68	N/A
Total		226			30.94

## DISCUSSION

Prompt recognition and surgical repair of FDP avulsions are critical in obtaining optimal return of function of the DIP joint and in avoiding permanent shortening and retraction of the tendon.

In 1977, Leddy and Packer<sup>6</sup> described a classification system for FDP ruptures. Type I is a rupture in which the tendon is retracted into the palm with rupture of both vincula. (Our patient had tendon retraction to the distal palm, seen on MRI, making this a type I profundus avulsion.) Type II is the most common rupture, with the tendon at the level of the proximal interphalangeal joint with a disrupted vinculum brevia. The least common rupture is type III,

**“...because of swelling and pain, FDP ruptures can be missed.”**

in which a large bone fragment prevents retraction of the tendon beyond the middle phalanx by catching on the A4 pulley. Two additional rupture types have been identified. In 1981, Smith<sup>14</sup> added type IV, an intra-articular fracture of the distal phalanx with an associated tendon avulsion, and in 2001 Al-Qattan<sup>15</sup> proposed type V, which consists of an osseous fragment and concomitant fracture of the distal phalanx.

Before the advent of MRI, some cases of FDP avulsions were initially missed, resulting in suboptimal repair months after injury. MRI has been shown to be effective in diagnosing FDP ruptures and in delineating the extent of proximal retraction of the ruptured tendon.<sup>16-19</sup>

## CONCLUSIONS

We report the present case to call attention to the possibility of FDP avulsions in a typical childhood door-closing injury. Although such an injury typically results in fracture, this case was unique because it instead resulted in an FDP avulsion. FDP ruptures are seldom seen in skeletally immature patients, particularly in patients as young as 11. In addition,

because of swelling and pain, FDP ruptures can be missed. Care should be taken to definitively ensure proper functioning of the DIP joint.

## AUTHORS' DISCLOSURE STATEMENT

The authors report no actual or potential conflict of interest in relation to this article.

## REFERENCES

1. Von Zander. Trommlelahmung Inaug. Dissertation, Berlin, 1891.
2. McMaster PE. Tendon and muscle ruptures. Clinical and experimental studies on the causes and location of subcutaneous ruptures. *J Bone Joint Surg Am.* 1933;15(3):705-722.
3. Gunter GS. Traumatic avulsion of the insertion of the flexor digitorum profundus tendon. *Aust N Z J Surg.* 1960;30(1):2-8.
4. Manske PR, Lesker PA. Avulsion of the ring finger flexor digitorum profundus tendon: an experimental study. *Hand.* 1978;10(1):52-55.
5. Wenger DR. Avulsion of the profundus tendon insertion in football players. *Arch Surg.* 1973;106(2):145-149.
6. Leddy JP, Packer JW. Avulsion of the profundus tendon insertion in athletes. *J Hand Surg Am.* 1977;2(1):66-69.
7. Bynum DK, Gilbert JA. Avulsion of the flexor digitorum profundus: anatomic and biomechanical considerations. *J Hand Surg Am.* 1988;13(2):222-227.
8. Boyes JH, Wilson JN, Smith JW. Flexor tendon ruptures in the forearm and hand. *J Bone Joint Surg Am.* 1960;42(4):637-646.
9. Carroll RE, Match RM. Avulsion of the profundus tendon insertion. *J Trauma.* 1970;10(12):1109-1118.
10. Chang WHJ, Thoms OJ, White WL. Avulsion injury of the long flexor tendons. *Plast Reconstr Surg.* 1972;50(3):260-264.
11. Folmar RC, Nelson CL, Phalen GS. Ruptures of the flexor tendons in hands of non-rheumatoid patients. *J Bone Joint Surg Am.* 1972;54A(3):579-584.
12. Reef TC. Avulsion of the flexor digitorum profundus: an athletic injury. *Am J Sports Med.* 1977;5(6):281-285.
13. Lunn PG, Lamb DW. "Rubgy finger"—avulsion of the profundus of ring finger. *J Hand Surg Br.* 1984;9(1):69-71.
14. Smith JH. Avulsion of a profundus tendon with simultaneous intra-articular fracture of the distal phalanx—case report. *J Hand Surg Am.* 1981;6(6):600-601.
15. Al-Qattan MM. Type 5 avulsion of the insertion of the flexor digitorum profundus tendon. *J Hand Surg Br.* 2001;26(5):427-431.
16. Kumar BA, Tolat AR, Threepuraneni G, Jones B. The role of magnetic resonance imaging in late presentation of isolated injuries of the flexor digitorum profundus tendon in the finger. *J Hand Surg Br.* 2000;25(1):95-97.
17. Scott JR, Cobby M, Taggart I. Magnetic resonance imaging of acute tendon injury in the finger. *J Hand Surg Br.* 1995;20(3):286-288.
18. Concannon MJ, Duffy FJ, Palmer WE, May JW. Late rupture of a flexor tendon after electrical injury: tendon localization using magnetic resonance imaging. A case report. *Ann Plast Surg.* 1996;36(1):84-87.
19. Drape JL, Tardif-Chastenot de Gery A, Silbermann-Hoffman O, et al. Closed ruptures of the flexor digitorum tendons: MRI evaluation. *Skeletal Radiol.* 1998;27(11):617-624.

---

*This paper will be judged for the Resident Writer's Award.*

---