

Coracoclavicular Stabilization Using a Suture Anchor Technique

Darren J. Friedman, MD, O. Alton Barron, MD, Louis Catalano, MD, Joseph P. Donahue, MD, and George Zambetti, MD

Abstract

Multiple fixation options exist for coracoclavicular stabilization, but many are technically demanding and require hardware removal. In the study reported here, we reviewed a specific fixation technique that includes suture anchors moored in the base of the coracoid process. We retrospectively reviewed 24 consecutive cases of patients who underwent coracoclavicular stabilization with a suture anchor for a type III or type V acromioclavicular (AC) joint separation or a group II, type II or type V distal clavicle fracture. Eighteen of the 22 patients had full strength and painless range of motion (ROM) in the affected extremity by 3 months and at final follow-up (minimum, 24 months; mean, 39 months). Two patients were lost to follow-up. Four patients had early complications likely secondary to documented noncompliance. Two of these 4 patients underwent reoperation with a similar procedure and remained asymptomatic at a minimum follow-up of 15 months. One patient underwent osteophyte and knot excision 7 months after surgery and remained asymptomatic at 30 months.

Our results suggest that coracoclavicular stabilization using a suture anchor technique is a safe and reliable method of treating acromioclavicular joint separations and certain distal clavicle fractures in the compliant patient.

The diarthrodial acromioclavicular (AC) joint and its soft-tissue supports allow the clavicle to fulfill its role as an osseous stabilization bar, helping to maintain lateralization of the scapula on the chest wall. For the AC joint to be rendered unstable, both the horizontally stabilizing capsular ligaments and the stronger, vertically stabilizing

coracoclavicular (CC) ligaments must be torn. When this occurs, the upper trapezius maintains the horizontal position of the clavicle while the scapula and upper limb fall away, creating the clinically visible types III through V AC joint separations.¹⁻³ Alternatively, certain distal clavicle fracture patterns (group II, types II and V) may leave the conoid and/or trapezoid portions of the CC ligament complex intact but still create an unstable clinical deformity that will often require surgery.¹⁻³ These fractures result in loss of the suspensory mechanism of the scapula and represent the bony equivalent of an AC separation.² When surgery is indicated, multiple fixation options exist, but many of these are technically demanding, require hardware removal, are complicated by hardware migration and/or breakage, or cause osseous erosion.^{4,5} Hardware that crosses

“As no instruments or fixation materials are passed underneath the coracoid, risk for neurovascular injury is minimized.⁶”

the AC joint may also injure the cartilage and meniscus and lead to early joint degeneration.

In 1996, in an effort to diminish the likelihood of such complications and to simplify this common procedure, the authors began using a specific fixation technique that includes suture anchors moored in the base of the coracoid process. Advantages include a smaller incision and dissection limited to the region above the coracoid. As no instruments or fixation materials are passed underneath the coracoid, risk for neurovascular injury is minimized.⁶ In addition, no hardware transfixes the AC joint or requires removal at a later time.

In this article, we describe a surgical technique, our retrospective review of cases performed with this technique, and the subjective and objective outcomes.

MATERIALS AND METHODS

Between September 1996 and April 2004, 1 of 3 surgeons performed this technique in 24 cases. It was performed for 10 acute AC separations (ie, five type III, five type V) and 4 chronic cases (ie, two type III,

Dr. Friedman is Chief Resident, Dr. Barron is Attending, and Dr. Catalano is Attending, Department of Orthopaedic Surgery, St. Luke's Roosevelt Hospital Center, New York, New York.

Dr. Donahue is Attending, Sports Orthopedic and Rehabilitation, Redwood City, California.

Dr. Zambetti is Attending, Department of Orthopaedic Surgery, St. Luke's Roosevelt Hospital Center, New York, New York.

Address correspondence to: Darren J. Friedman, MD, St. Luke's Hospital, Department of Orthopaedic Surgery, Clark 7, 1111 Amsterdam Avenue, New York, NY 10025 (tel, 212-523-2650; fax, 212-523-4676; e-mail, djfortho@hotmail.com).

Am J Orthop. 2008;37(6):294-300. Copyright Quadrant HealthCom Inc. 2008. All rights reserved.

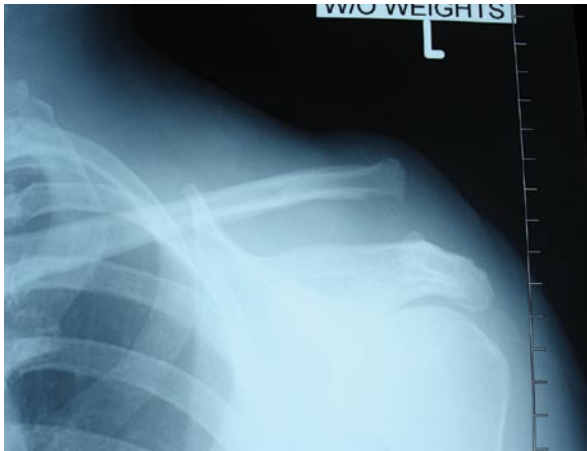


Figure 1. Acute left type V acromioclavicular separation.

two type V). It was also performed for 10 group II distal clavicle fractures (ie, nine type II, one type V). There were 20 men and 4 women. Mean age was 37 years (range, 19-73 years). Injuries had been sustained in falls (11 cases), contact sports (6), bicycle accidents (4), and motor vehicle accidents (3). All operative cases for AC separation or group II distal clavicle fracture were included in the study. The 10 acute AC separations were definitively treated within 2 weeks of initial injury. The 4 chronic AC separations were treated a minimum of 9 weeks after initial injury. Two patients (1 type II fracture, 1 acute type V separation) were lost to long-term follow-up after their initial postoperative visit. Twenty-two patients were included in the study.

Each patient underwent the surgical procedure (to be described) on the basis of injury type. Derivations of this technique have been described previously for the treatment of AC separations⁷ and distal clavicle fractures.⁸ In addition, the 4 patients with chronic AC separations underwent distal clavicle resection with transfer of the coracoacromial ligament, as originally described by Weaver and Dunn.⁹ Patients with evidence of AC joint degeneration (3 patients), distal clavicle osteolysis (1), or AC joint malalignment (1) underwent distal clavicle excision.

Institutional review board (IRB) approval was obtained for the study, and each patient signed an IRB-approved form for institutional consent for participation in research.

Surgical Technique: Acromioclavicular Separation

Under regional interscalene anesthesia and with the patient in the beach-chair position, the arm and shoulder region are prepped and draped, taking care to medialize the sterile field toward the base of the neck. An anteroposterior saber incision 5 to 7 cm in length is made over the distal clavicle at the level of the coracoid process after the skin has been injected with a local anesthetic-epinephrine mixture. Subcutaneous

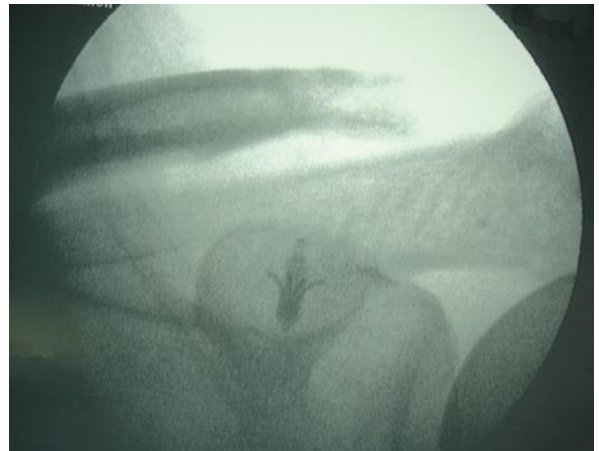

Figure 2. Intraoperative x-ray status-post suture anchor fixation and distal clavicle excision secondary to acromioclavicular joint degeneration.

dissection is extended mediolaterally approximately 3 cm in each direction to expose the deltotrapezial fascia. This is incised medial to lateral along the dorsal curvilinear surface of the distal clavicle using the needle-tipped electrocautery down to bone. With significant displacement of the clavicle, the deltotrapezial may not directly overlie the bone, and care must be taken to avoid splitting muscle. Subperiosteal electrocautery dissection is carried to the level of the AC joint, taking care to identify and protect the attachments of the conoid and trapezoid ligaments.

Blunt dissection is then used to palpate and then visualize the dorsal base of the coracoid at, and just anterior to, the opposing stumps of the CC ligaments. One Mitek Super Quickanchor (DePuy Mitek, Norwood, Mass) is modified by threading two No. 5 braided, nonabsorbable sutures (Ethibond Excel, Johnson & Johnson, Raynham, MA) through the eyelet. It is helpful to use 2 different colors of suture or to mark 2 corresponding ends with the marking pen to aid with suture management. Alternatively, a No. 2 Fiberwire (Arthrex, Naples, Fla) may be exchanged for 1 of the nonabsorbable sutures. In chronic separations or in patients who are overweight or have significant muscle mass, 2 suture anchors may be used.

Two curved hemostats or narrow Homan retractors are then placed to delineate the breadth of the coracoid base, helping to center the anchor drill hole in the base. The anchor is placed, the sutures are forcefully tugged to test the anchor, and the suture ends are clamped. A 2-mm drill bit is then used to make 2 parallel holes 1 cm apart obliquely across the distal clavicle just above the CC ligament attachments. The trajectory of the drill hole is from posterior-superior to anterior-inferior. This position allows for the rather bulky No. 5 suture knots to lie buried under the deltotrapezial fascia, at the posterior cortex of the clavicle, and for the vertical limbs of the suture to enter the clavicle anterior-inferior within the substance of the

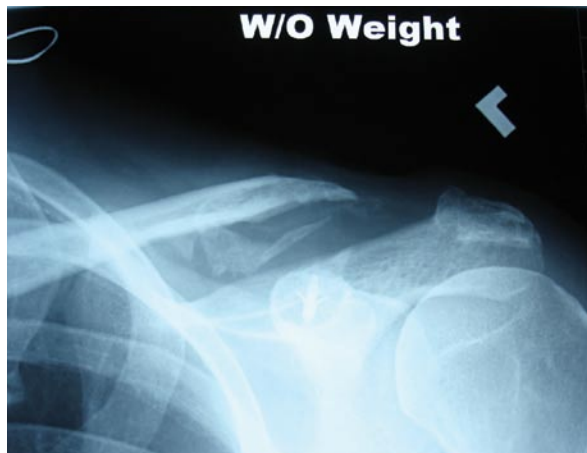

Figure 3. Twenty-five months after surgery, x-ray without weight shows mild increase in coracoclavicular distance and calcification of coracoclavicular ligaments.

ligament stumps. This suture position also ensures that the distal clavicle is not translated anteriorly, subluxating the AC joint, as commonly happens when sutures are looped around the clavicle and the coracoid. It is important to remove excess bone and to

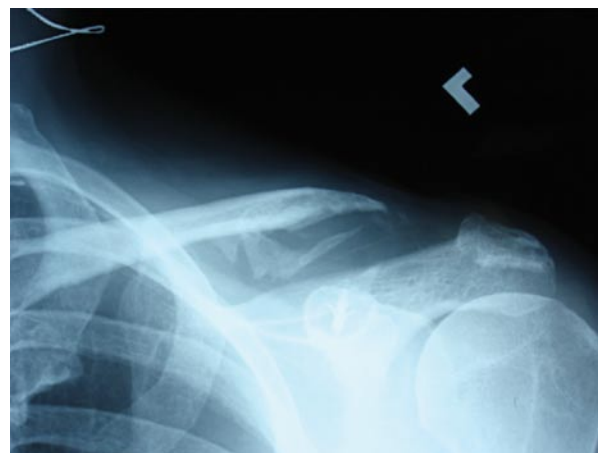

Figure 4. Twenty-five months after surgery, x-ray with 10-lb weight in left hand shows stable mild increase in coracoclavicular distance.

smooth sharp edges about the drill holes to minimize risk for suture laceration.

A Hewson suture passer is inserted back to front, and a strand of suture from each pair is drawn through each hole. With an assistant simultaneously lifting up

Table. Final Radiographic Results

| Age (y) | Sex | Injury | Treatment Technique | Outcome |
|---------|-----|--|---|---|
| 43 | M | Type II fracture | 1 suture anchor | Healed, reduced |
| 55 | M | Type II fracture | 1 suture anchor | Healed, reduced |
| 47 | M | Type II fracture | 1 suture anchor | Healed, reduced |
| 19 | M | Type II fracture | 1 suture anchor | Healed, reduced |
| 32 | M | Type II fracture | 1 suture anchor | Healed, reduced |
| 38 | M | Type II fracture | 1 suture anchor | Refracture (due to noncompliance), reduced |
| 22 | F | Type II fracture | 1 suture anchor | Healed, reduced |
| 42 | F | Type II fracture | 1 suture anchor | Healed, reduced |
| 39 | M | Type V fracture, distal clavicle degeneration | 1 suture anchor, distal clavicle excision | Healed, reduced |
| 27 | M | Type III AC joint separation | 1 suture anchor | Reduced |
| 21 | M | Type III AC joint separation | 1 suture anchor | Reduced |
| 26 | M | Type III AC joint separation | 2 suture anchors | Resubluxed (due to noncompliance); reoperation, reduced |
| 40 | M | Type III AC joint separation, distal clavicle degeneration | 1 suture anchor, distal clavicle excision | Moderate (20%-40%) increase in coracoclavicular distance |
| 21 | M | Type III AC joint separation, distal clavicle osteolysis | 1 suture anchor, distal clavicle excision | Mild (<20%) increase in coracoclavicular distance |
| 34 | M | Type V AC joint separation | 1 suture anchor | Reduced |
| 21 | M | Type V AC joint separation | 2 suture anchors | Reduced |
| 55 | M | Type V AC joint separation, distal clavicle degeneration | 1 suture anchor, distal clavicle excision | Moderate (20%-40%) increase in coracoclavicular distance |
| 73 | F | Type V AC joint separation, distal clavicle degeneration | 1 suture anchor, distal clavicle excision | Mild (<20%) increase in coracoclavicular distance |
| 31 | M | Type III chronic AC joint separation | 1 suture anchor, CA ligament transfer | Mild (<20%) increase in coracoclavicular distance |
| 40 | M | Type III chronic AC joint separation | 1 suture anchor, CA ligament transfer | Moderate (20%-40%) increase in coracoclavicular distance (due to noncompliance) |
| 38 | M | Type V chronic AC joint separation | 1 suture anchor, CA ligament transfer | Mild (<20%) increase in coracoclavicular distance |
| 47 | F | Type V chronic AC joint separation | 2 suture anchors, CA ligament transfer | Resubluxed (due to non compliance); reoperation, resubluxed |

Abbreviations: AC, acromioclavicular; CA, coracoacromial; CC, coracoclavicular.

on the elbow and pushing down on the clavicle with a pointed awl, the AC joint is slightly overreduced, and each suture strand is tied separately. The weight of the arm is then allowed to stress the construct to ensure maintenance of the joint reduction, and this position is documented with a mini C-arm x-ray. The weight of the arm is then supported against the patient's chest during wound closure.

Closure of the deltotracheal fascia is performed with inverted No. 2 braided nonabsorbable sutures. The subcutaneous tissue is closed with 0 and/or 2-0 braided absorbable suture, and the skin is approximated with a running subcuticular 3-0 nylon suture and Steri-strips.

maintenance, function recovery, and patient satisfaction. All postoperative clinical testing was performed by a physician not involved in the treatment of the patients.

RESULTS

Eighteen of the 22 patients had full strength (vs contralateral limb) and painless ROM in the affected extremity by 3 months and at final follow-up (minimum, 24 months; mean, 39 months). Active shoulder motion was full and symmetric to the uninjured side. The clavicle and AC joint were nontender at final follow-up. There was no pain or crepitus about the clavicle or AC joint with shoulder motion, including cross-body

“The limited supracoracoid dissection and the simplicity of the fixation technique should minimize risk for sub-coracoid neurovascular structures, minimize blood loss, and shorten operative time.”

Surgical Technique: Distal Clavicle Fracture

The basic approach just described is used with several additional points. In group II, type II fractures with intact CC ligaments or ligament, the suture is passed through drill holes in the medial fracture fragment. Visual inspection may indicate that drill hole placement should be altered in order to create the most anatomical anteroposterior reduction.

Fractures with multiple large fragments may require 3.5-mm lag screws to simplify the fracture pattern. This is especially true of group II, type V fractures, which are characterized by a large inferior bone fragment attached to intact CC ligaments. In such cases, 2 lag screws can reduce the fracture anatomically to allow for bone-to-bone healing. Alternatively, heavy nonabsorbable suture may be used in cerclage fashion in lieu of lag screws. In all cases, however, suture anchors are still used for further stabilization to protect the lag screw or cerclage fixation.

Postoperative Protocol

After surgery, the patient wears a sling for 6 weeks but after 3 weeks performs full active shoulder motion daily in the *supine* position to minimize stress on the repair. Rotator cuff strengthening is begun at 6 weeks, and unlimited activities, including contact sports and heavy lifting, are allowed 3 months after surgery.

All patients were followed throughout the postoperative period until final follow-up (minimum, 24 months; mean, 39 months). Medical records, Disabilities of the Arm, Shoulder, and Hand (DASH) questionnaires (Institute of Work and Health, Toronto, Canada), clinical examination, and preoperative, postoperative, and follow-up x-rays were used to assess healing, reduction

adduction at final follow-up. All patients were neurovascularly intact from initial postoperative visit to final follow-up.

Twenty of the 22 patients were able to return to their preinjury level of activity, including contact sports. One patient chose to engage in lighter activities because of fear of reinjury. Twenty of the 22 patients were satisfied with the results and said they would undergo the surgery again if indicated. At final follow-up, the cohort's mean DASH outcome measure score was 8.56 (range, 0-50; SD, 12.5).

Final x-rays showed healing in near-anatomical position in all 9 patients with distal clavicle fractures. Final x-rays also showed that 5 patients with AC separations remained anatomically reduced. Four patients had a mild (<20%) increase in coracoclavicular distance between immediate postoperative x-rays and final follow-up x-rays, and 3 patients had a moderate (20%-40%) increase in coracoclavicular distance. In 1 of these cases, the increase was likely due to postoperative noncompliance and suture anchor pullout (to be described). There was no evidence of any clinical ramifications of this finding; all 7 patients with some degree of resubluxation recovered completely without limitations and remained asymptomatic. Last, 1 patient had a symptomatic 40% increase in coracoclavicular distance after reoperation likely secondary to initial postoperative noncompliance. A radiographic case example is shown in Figures 1 to 4, and final radiographic results are presented in the Table.

Surgical estimated blood loss was 35 mL in patients with AC separation and 70 mL in patients with distal clavicle fracture. Mean operative time was 55 minutes in patients with AC separation and 75 minutes in patients with distal clavicle fracture.

Four patients had early complications likely secondary to noncompliance with the postoperative protocol. One muscular male patient who underwent coracoacromial ligament transfer plus suture anchor fixation for a chronic type III AC separation began to bench-press heavy weight 4 weeks after surgery. X-rays showed anchor pullout and increase in coracoclavicular distance. No further treatment was required, as the patient attained full functional recovery in no additional time.

Another patient sustained a nondisplaced fracture through his previous fracture site exactly 6 weeks after surgery, when he lifted another adult overhead. His original injury was a group II, type II distal clavicle fracture, and a minimally displaced refracture occurred through the medial aspect of the original fracture site. Initial nonoperative treatment likely failed because of noncompliance with sling immobilization after the first week, as the patient began engaging in marathon training, weight lifting, and swimming. He then underwent open reduction and internal fixation with a 3.5-mm reconstruction

A fifth patient, a thin young woman, had a complication not related to noncompliance. She developed an osteophyte around the suture knot about the posterior aspect of the clavicle after suture anchor fixation for a group II, type II distal clavicle fracture. She had full painless ROM by 6 weeks but underwent osteophyte and knot excision 7 months after surgery because of mild irritation and cosmetic concerns. She healed uneventfully.

DISCUSSION

We have described a suture anchor technique for open treatment of AC joint separations and distal clavicle fractures. Derivations of this technique have been described previously for the treatment of AC separations⁷ and distal clavicle fractures.⁸ The limited supracoracoid dissection and the simplicity of the fixation technique should minimize risk for subcoracoid neurovascular structures, minimize blood loss, and shorten operative time. Our results

“Use of a second suture anchor should be considered in the setting of chronic separation or when treating a patient with a heavy or muscular limb.”

plate and healed without further sequelae. He remained asymptomatic at 47 months.

The third patient was an overweight young man who underwent initial fixation with 2 Mitek G2 suture anchors threaded with No. 5 Ethibond, for an acute type III AC separation. This patient's being noncompliant with sling immobilization likely led to symptomatic rupture of the sutures and resubluxation of the clavicle. He underwent reoperation with 2 suture anchors (Mitek Super Quickanchor) threaded with No. 5 Ethibond and No. 2 Fiberwire 3 weeks after initial surgery and healed without further sequelae. He remained asymptomatic at 15 months.

The fourth patient was an obese middle-aged woman who underwent coracoacromial ligament transfer and suture anchor fixation with 2 anchors for a chronic type V AC separation. She too was noncompliant with sling immobilization, again likely leading to symptomatic rupture of the sutures and increase in coracoclavicular distance. She underwent reoperation with 2 suture anchors threaded with No. 5 Ethibond and No. 2 Fiberwire plus revision of coracoacromial ligament transfer with No. 2 Fiberwire 4 weeks after initial surgery. She had full ROM at 3 months and full strength at 4 months, with x-rays showing a well-reduced clavicle. At 6 months, x-rays showed an increase in coracoclavicular distance with subjective complaints of discomfort. She denied any recent trauma or reinjury. Magnetic resonance imaging was recommended, but the patient failed to return to the clinic and was lost to further follow-up.

in this retrospective study indicate few significant complications and high patient satisfaction in the compliant patient. The mean DASH score of 8.56 (SD, 12.5) fell well within the normative range for age-matched healthy controls (mean, 10.10; SD, 14.68), as determined by Hunsaker and colleagues.¹⁰ Our results illustrate the importance of postoperative compliance with sling use and guided physical therapy. Four of our 5 complications were likely directly related to poor or complete noncompliance with our postoperative protocol.

Of the 8 patients who showed increased coracoclavicular distance on final x-rays, 7 were asymptomatic and had full painless ROM. For 4 of these 7 patients, increase in coracoclavicular distance was mild (<20%), likely representing benign stretching of the repair, with no physiologic consequence. The increase was moderate (20%-40%) in the other 3 patients. In 1 case, the likely cause was noncompliance and anchor pullout (as described). In the other 2 cases (one type III, one type V AC separation), the patients had concomitant distal clavicle excisions secondary to AC joint degeneration. Neither of these patients underwent coracoacromial ligament transfer. Although both were asymptomatic, we believe that alignment might have remained more anatomical if coracoacromial ligament transfer had been performed. Regardless, 7 of the 8 patients with increased coracoclavicular distance were asymptomatic, indicating that some clavicular stability was likely achieved.

One of the patients with early complications underwent initial repair with 2 Mitek G2 anchors. This type of anchor has a tapered oblong eyelet that theoretically might have contributed to suture rupture (suture moves back and forth over the eyelet edge). This patient underwent successful reoperation with 2 Mitek Super Quickanchors, which have a more circular eyelet and theoretically less potential for suture rupture in this clinical scenario. Of note, initial repair involved No. 5 Ethibond sutures, whereas reoperation involved half No. 5 Ethibond and half No. 2 Fiberwire.

Overall, the prognosis after treatment of chronic AC separations is worse than that after treatment of acute AC separations and distal clavicle fractures.^{1,2} Distal clavicle fractures have a higher likelihood of healing, as bony union is more reliable than ligamentous healing. Similarly, likelihood of coracoclavicular healing is higher in the setting of acute AC separations (when reduction is adequate) than in the chronic setting. In the present study, only 4 patients had chronic AC separations, and 2 were noncompliant with the postoperative protocol. Because of the low number of patients and the high rate of noncompliance in this group, we felt that reporting our overall results in a population that had lost the suspensory mechanism of the scapula on the clavicle would be more valuable than stratifying the patients into 3 separate injury groups.

Given our investigation results, we feel that the surgical technique described is appropriate when treating group II, type II or V distal clavicle fractures and type III or V AC joint separations. Suture anchors with a circular eyelet are recommended. We also recommend that patients with chronic AC separations undergo distal clavicle resection with transfer of the coracoacromial ligament, as originally described by Weaver and Dunn,⁹ for added stability. If resection of the distal clavicle is performed in the acute setting, transfer of the coracoacromial ligament should be considered, as 2 of the 4 patients in this scenario had a moderate (20%-40%) increase in coracoclavicular distance. Use of a second suture anchor should be considered in the setting of chronic separation or when treating a patient with a heavy or muscular limb.

Reviewing the literature, we found only 1 clinical study like ours, and it had significant limitations. Su and colleagues⁷ reported on 11 consecutive patients with complete AC separations treated with 2 suture anchors moored in the base of the coracoid. There was no failure of fixation or recurrence of deformity reported. However, no subjective or objective outcome measure was used to evaluate the patients, and no long-term follow-up was reported.

Suture anchors have been used successfully in many orthopedic procedures. Numerous cadaveric studies have explored the affects of AC joint reconstruction with suture anchors in the setting of AC joint separations with favorable biomechanical results.¹¹⁻¹³ Other biomechanical studies have demonstrated that suture

anchors are equivalent to reconstructive techniques using the coracoacromial ligament, screw fixation, or suture or synthetic augmentations passed under the base of the coracoid.^{6,14-16} Dimakopoulos and colleagues¹⁷ recently reported good clinical results in treating acute complete AC separations with a double-loop suture repair around the base of the coracoid. Breslow and colleagues⁶ found that "similar stability can be achieved for coracoclavicular fixation with suture anchors or with sutures placed around the base of the coracoid."

Harris and colleagues¹⁵ showed that use of a coracoclavicular screw is the strongest reconstruction technique, but only if bicortical purchase is obtained. When only 1 cortex was breached, the strength was reduced by 50%—the screw was weaker than a suture anchor. Despite the superior strength obtained with bicortical fixation, Motamedi and colleagues¹⁶ reported that this technique is more technically demanding and less reproducible. In our experience, correct bicortical insertion is difficult, and the complications of screw pullout, breakage, infection, screw head irritation, and need for removal make this technique inferior to using sutures or suture anchors.

Recently, Bezer and colleagues⁸ had 9 excellent results and 1 good result in treating 10 distal clavicle fractures with an intramedullary Kirschner wire and a single suture anchor (minimum follow-up, 1 year). Other studies have found the possible complications of screws and Kirschner wires when used in and around the shoulder joint, including breakage, need for removal, and migration.^{4,5,18} Our technique simplifies the procedure and avoids the risk for such complications. Also, no instruments or fixation materials are passed underneath the coracoid, thus minimizing the risk for neurovascular injury.

CONCLUSIONS

We believe that coracoclavicular stabilization using a suture anchor technique is a safe and reliable method of treating acromioclavicular joint separations and certain distal clavicle fractures in the compliant patient.

AUTHORS' DISCLOSURE STATEMENT AND ACKNOWLEDGMENT

The authors report no actual or potential conflict of interest in relation to this article.

This study was conducted at St. Luke's-Roosevelt Hospital Center, New York, New York.

REFERENCES

1. Allman FL Jr. Fractures and ligamentous injuries of the clavicle and its articulation. *J Bone Joint Surg Am.* 1967;49(4):774-784.
2. Rockwood CA, Young DC. Disorders of the acromioclavicular joint. In: Rockwood CA, Matsen FA III, eds. *The Shoulder*. Vol 1. Philadelphia, PA: Saunders; 1990:413-476.
3. Tossey JD, Mead NC, Sigmund HM. Acromioclavicular separations: useful and practical classification for treatment. *Clin Orthop.* 1963;28:111-119.
4. Daus GP, Drez D, Newton BB, Kober R. Migration of a Kirschner wire from the sternum to the right ventricle. *Am J Sports Med.* 1993;21(2):321-322.

5. Lyons FA, Rockwood CA. Current concepts review—migration of pins used in operations on the shoulder. *J Bone Joint Surg Am.* 1990;72(8):1262-1267.
6. Breslow MJ, Jazrawi LM, Bernstein AD, Kummer FJ, Rokito AS. Treatment of acromioclavicular joint separation: suture or suture anchors? *J Shoulder Elbow Surg.* 2002;11(3):225-229.
7. Su EP, Vargas JH, Boynton MD. Using suture anchors for coracoclavicular fixation in treatment of complete acromioclavicular separation. *Am J Orthop.* 2004;33(5):256-257.
8. Bezer M, Aydin N, Guven O. The treatment of distal clavicle fractures with coracoclavicular ligament disruption: a report of 10 cases. *J Orthop Trauma.* 2005;19(8):524-528.
9. Weaver JK, Dunn HK. Treatment of acromioclavicular injuries, especially complete acromioclavicular separation. *J Bone Joint Surg Am.* 1972;54(6):1187-1194.
10. Hunsaker FG, Cioffi DA, Amadio PC, Wright JG, Caughlin B. The American Academy of Orthopaedic Surgeons Outcomes Instruments: normative values from the general population. *J Bone Joint Surg Am.* 2002;84(2):208-215.
11. Deshmukh AV, Wilson DR, Zilberfarb JL, Perlmutter GS. Stability of acromioclavicular joint reconstruction. *Am J Sports Med.* 2004;32(6):1492-1498.
12. Osti M, Seil R, Bachelier F, Kohn D. Minimally invasive endoscopic reconstruction technique of acute AC-joint dislocations: a cadaver study. *Knee Surg Sports Traumatol Arthrosc.* 2006;14(7):686-691.
13. Wilson DR, Moses JM, Zilberfarb JL, Hayes WC. Mechanics of coracoclavicular ligament transfer augmentation for acromioclavicular joint injuries. *J Biomech.* 2005;38(3):615-619.
14. Goble EM, Somers WK, Clark R, Olsen RE. The development of suture anchors for use in soft tissue fixation to bone. *Am J Sports Med.* 1994;22(2):236-239.
15. Harris RI, Wallace AL, Harper GD, Goldberg JA, Sonnabend DH, Walsh WR. Structural properties of the intact and the reconstructed coracoclavicular ligament complex. *Am J Sports Med.* 2000;28(1):103-108.
16. Motamedi AR, Blevins FT, Willis MC, McNally TP, Shahinpoor M. Biomechanics of the coracoclavicular ligament complex and augmentations used in its repair and reconstruction. *Am J Sports Med.* 2000;28(3):380-384.
17. Dimakopoulos P, Panagopoulos A, Syggelos SA, Panagiotopoulos E, Lambris E. Double-loop suture repair for acute acromioclavicular joint disruption. *Am J Sports Med.* 2006;34(7):1112-1119.
18. Lindsey RW, Gutowski, WT. The migration of a broken pin following fixation of the acromioclavicular joint. A case report and review of the literature. *Orthopedics.* 1986;9(3):413-416.

This paper will be judged for the Resident Writer's Award.

Mailing with the August issue of AJO:

Covering such topics as:

Nonsurgical Management of Knee OA in the Active Woman

Stress Fractures in Women

Sorting the Differential Diagnosis in Erosive OA

Plus:

- Relevant news from other specialties
- Practice management advice
- Interviews

