

# Bilateral Femoral Insufficiency Fractures Presenting as Knee Pain in a Patient With Hypophosphatemic Vitamin D-Resistant Rickets

Douglas W. Pahl, MD, and Christopher Kisok Kim, MD

**R**ickets is the manifestation of a metabolic bone disease caused by a mineral deficiency (either calcium or phosphate) that prevents the normal process of mineral deposition at the growth plate. If growth slows and bone age is retarded, then the condition is called *rickets*. The most commonly encountered form of rickets is *familial hypophosphatemia*, and the usual mode of inheritance is X-linked dominant, indicating that some mothers of children affected with this disease exhibit clinical manifestations, such as lower extremity bowing or short stature.<sup>1</sup> This form was first described in 1937 by Albright, who coined the term *hypophosphatemic vitamin D-resistant rickets*.<sup>2</sup> With early diagnosis, appropriate medical management, and good compliance, bowing of the lower extremities can be minimized. In severe deformities, corrective osteotomies can be performed after rickets has healed radiographically.<sup>1</sup>

We report the case of a patient who was noncompliant with medical management for vitamin D-resistant rickets, had long-standing knee pain, and was found to have insufficiency fractures of both femoral diaphyses. This case is presented because of its unique fracture pattern, its association with hypophosphatemic vitamin D-resistant rickets, and the manner in which the condition was diagnosed—the patient was initially treated for knee pain that actually was pain referred from the femora.

## CASE REPORT

A man in his early 20s was referred to one of the authors with a 2-year history of bilateral, atraumatic knee pain. The patient described mild, intermittent symptoms that were not severe enough for him to seek medical atten-

tion until they worsened steadily over a few months. He denied being involved in any vigorous outdoor activities or sports. The pain was primarily noticed on awakening in the morning and after periods of activity and subsided with standing or slow walking. The patient denied periods of swelling, locking, or instability.

Medical history was significant only for familial hypophosphatemia (X-linked hypophosphatemia) or vitamin D-resistant rickets. The patient had been diagnosed when he was 6 months old and medically managed with oral phosphate supplements and a vitamin D analog until he was 12 years old, when he voluntarily discontinued the regimen because of its gastrointestinal side effects.

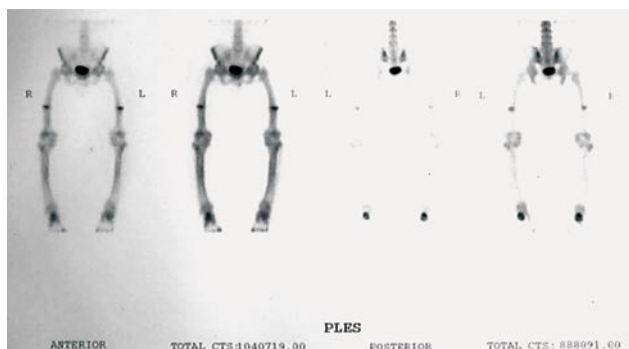
On physical examination, the patient was noted to be a short Caucasian man with bilateral varus deformity to the lower extremities. The knee examination was unremarkable, with ligamentously stable and nontender knees noted bilaterally. cursory laboratory evaluations were performed secondary to the medical history revealing an elevated serum alkaline phosphatase level of 424 U/L (normal, 35-115 U/L). The serum calcium level of 10.3 mg/dL was within normal limits (8.5-10.5 mg/dL), as was the serum parathyroid hormone level of 280 pg/dL (normal, 50-340 pg/dL). Plain radiographs of both knees showed only an abnormal trabecular pattern in both tibiae. Bone scintigraphy (Figure 1) then showed uptake in both femoral shafts, consistent with stress fractures. Dedicated femoral radiographs then showed bilateral femoral fractures at the junction of the middle and distal thirds of the femur involving only the lateral cortices with abundant surrounding callous

Dr. Pahl is Orthopaedic Spine Surgery Fellow, Twin Cities Spine Center, Minneapolis, Minnesota.

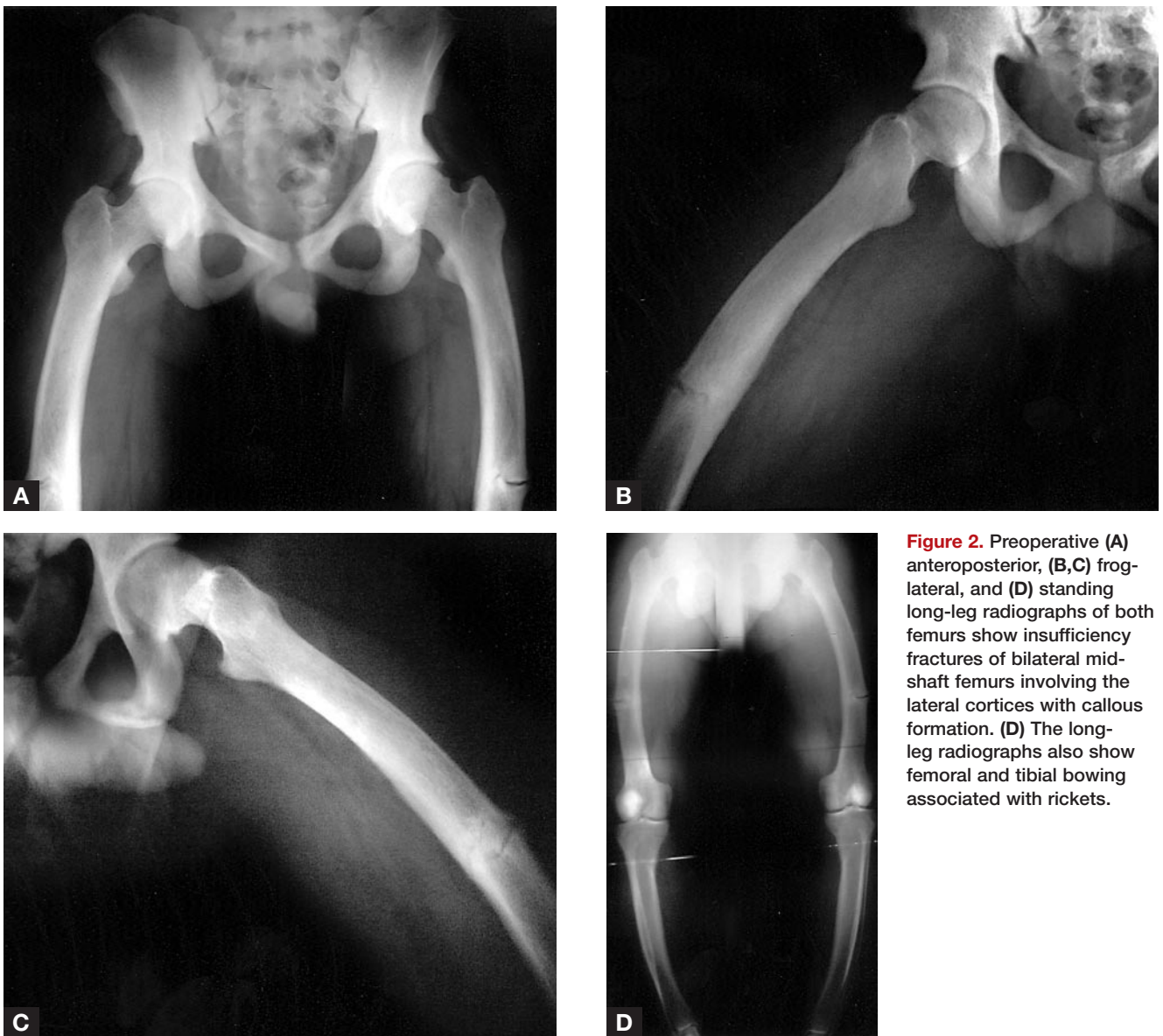
Dr. Kim is Staff Orthopaedic Surgeon, West End Orthopaedic Clinic, Richmond, Virginia.

Address correspondence to: Douglas W. Pahl, MD, Twin Cities Spine Center, Piper Building, 913 East 26th Street, Suite 600, Minneapolis, MN 55404 (tel, 706-566-3025; e-mail, douglaspahl2@mac.com).

*Am J Orthop.* 2008;37(6):315-317. Copyright Quadrant HealthCom Inc. 2008. All rights reserved.



**Figure 1.** Preoperative bone scintigraphy shows tracer uptake at corresponding femoral fracture sites on plain radiographs.



**Figure 2.** Preoperative (A) anteroposterior, (B,C) frog-lateral, and (D) standing long-leg radiographs of both femurs show insufficiency fractures of bilateral mid-shaft femurs involving the lateral cortices with callous formation. (D) The long-leg radiographs also show femoral and tibial bowing associated with rickets.

formation (Figures 2A–2D). Bilateral femoral insufficiency fractures were diagnosed, and the patient underwent corrective osteotomies at the fracture site with compression plating (Figures 3A–3D). The initial postoperative course was uneventful. By 1 year after surgery, the patient had resumed medical management of the vitamin D-resistant rickets, the osteotomy sites were well healed (Figures 4A–4C), and the bilateral knee pain had resolved.

### DISCUSSION

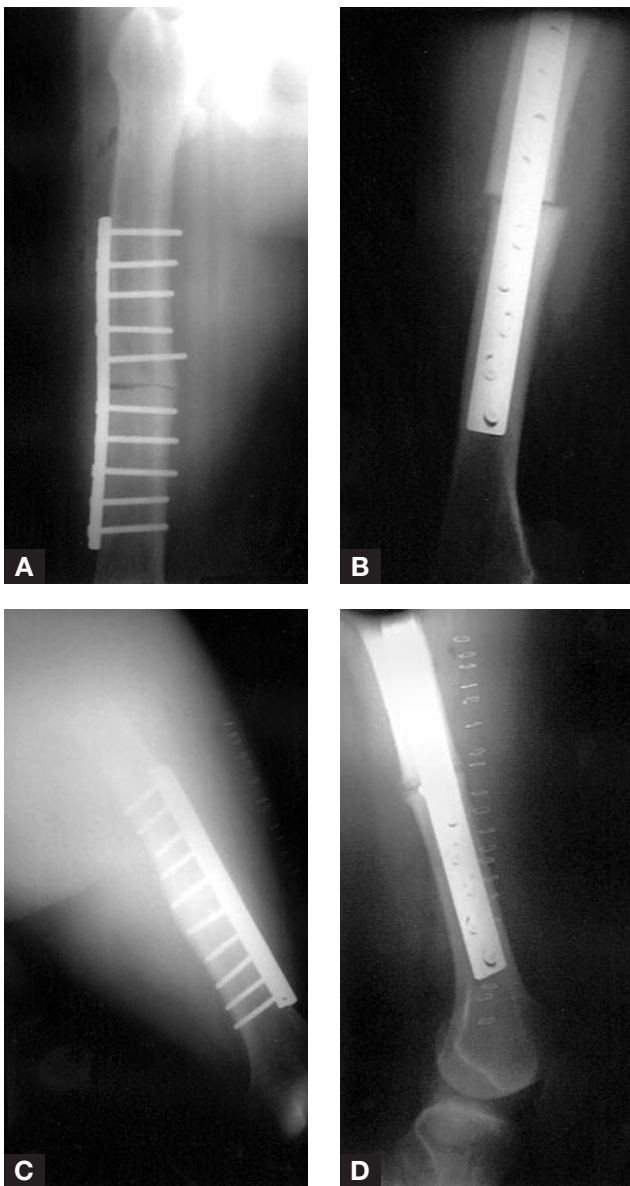
In patients with hypophosphatemic vitamin D-resistant rickets, the classic clinical triad consists of hypophosphatemia, lower limb deformities, and stunted growth. Although low serum phosphate is evident early after birth, parents usually do not seek medical attention until the condition becomes sufficiently apparent, which usually occurs only on initiation of weight-bearing. The phenotypic difference between rickets caused by a phosphate deficiency and rickets caused by a calcium deficiency is

evidence of a dentin defect, found in the former, rather than enamel hypoplasia, found in the latter. The dentin defect trait is considered the marker for hypophosphatemic vitamin D-resistant rickets.<sup>2</sup>

With prompt treatment and compliance with a regimen of aggressive phosphate replacement, growth rate improves markedly, and radiologic healing of rickets becomes evident. However, this regimen requires a vitamin D analog to offset the hypocalcemic effect of large doses of phosphate, which can cause secondary hyperparathyroidism.<sup>2</sup>

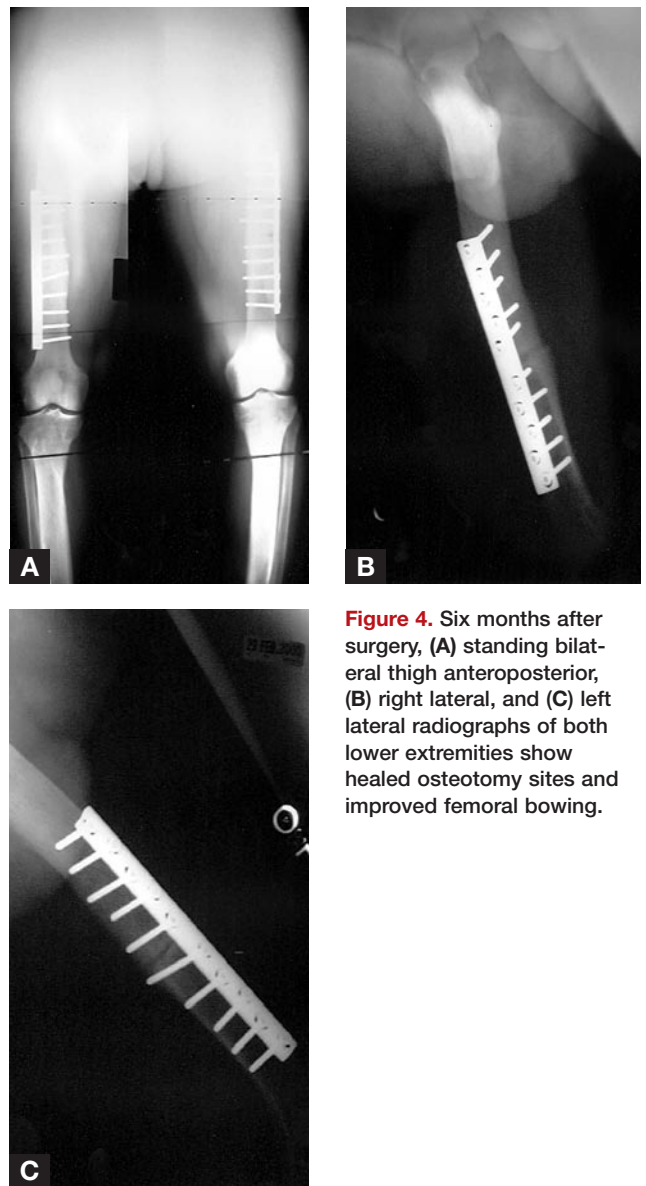
For patients with progressive lower limb deformities and severe angular deformities, corrective osteotomies are performed. These are usually performed after there is radiographic evidence of healed rickets, but in severe cases they can be performed before ossification of growth plates. In all circumstances, postoperative medical management is essential for maintenance of corrections.<sup>1,3,4</sup>

We present the first reported case of bilateral femoral insufficiency fractures of the diaphysis in a patient with



**Figure 3.** Immediate postoperative (A) right anteroposterior, (B) right lateral, (C) left anteroposterior, and (D) left lateral radiographs of both femurs after osteotomies and compression plating of femoral fractures.

hypophosphatemic vitamin D-resistant rickets. This patient's voluntary discontinuation of medical therapy led to osteomalacia, the underlying cause for his fractures. Patients with hypophosphatemic vitamin D-resistant rickets should be counseled about the risk for progressive angular deformities of the lower extremities and the possible need for surgical correction. This report reveals that insufficiency fractures of the lower extremities in patients with vitamin D-resistant rickets, though rare, can occur. We decided to perform compression plate fixation rather than intramedullary nailing for several reasons. First, we thought that the lateral femoral bow and the significant amount of intramedullary callus would make passing the nail difficult. Second, we wanted to perform a corrective wedge oste-



**Figure 4.** Six months after surgery, (A) standing bilateral thigh anteroposterior, (B) right lateral, and (C) left lateral radiographs of both lower extremities show healed osteotomy sites and improved femoral bowing.

otomy and thought that using a formal open approach would create the best opportunity for this. Third, we thought that bowing would not likely recur in this patient given his age, and the biomechanical advantage of intramedullary nailing would not be necessary.

### AUTHORS' DISCLOSURE STATEMENT

The authors report no actual or potential conflict of interest in relation to this article.

### REFERENCES

1. Chesney RW. Metabolic bone disease. In: Behrman RE, ed. *Nelson Textbook of Pediatrics*. 14th ed. Philadelphia, PA: Saunders; 1992:1750-1751.
2. Glorieux FH. *Primer on the Metabolic Bone Diseases and Disorders of Mineral Metabolism*. 5th ed. Philadelphia, PA: Lippincott Williams & Wilkins; 1999:328-330.
3. Eyres KS, Brown J, Douglas DL. Osteotomy and intramedullary nailing for the correction of progressive deformity in vitamin D-resistant hypophosphatemic rickets. *J R Coll Surg Edinb*. 1993;38(1):50-54.
4. Rubinovitch M, Said SE, Glorieux FH, et al. Principles and results of corrective lower limb osteotomies for patients with vitamin D-resistant hypophosphatemic rickets. *Clin Orthop*. 1988;(237):264-270.