

# Conversion Total Hip Replacement After Malunited Intertrochanteric Fracture: A Technical Note

Aasis Unnanuntana, MD, and Stuart B. Goodman, MD, PhD

## Abstract

Malunited intertrochanteric fracture involves anatomical changes such as medialization of the femoral canal and intramedullary remodeling and sclerosis. These changes introduce difficulties that are not ordinarily encountered with routine total hip replacement. Possible intraoperative complications include spiral femoral fracture during hip dislocation and failure to identify the femoral canal. Therefore, recognizing the anatomical changes before and during surgery is crucial.

In this article, we describe specific surgical steps and techniques by which these problems may be avoided, thus minimizing potential complications.

**T**otal hip replacement (THR) is one treatment option for failed hip fracture fixation. First, the surgeon identifies the cause of symptoms and the reason for failure, which may include infection, malunion, nonunion, femoral head osteonecrosis, and progressive degenerative osteoarthritis, or any combination thereof. For patients with malunited fractures after sliding hip screw fixation, additional anatomical changes should be considered, such as medialization of the femoral canal, retroverted metaphysis, cortical thinning, intramedullary remodeling and sclerosis around the lag screw tract, and malpositioned greater trochanter.<sup>1</sup> Knowing these anatomical changes may help the surgeon prepare for the instrumentation and implants needed and anticipate intraoperative problems in order to prevent potential complications.

We describe the surgical steps and technique to deal specifically with a malunited intertrochanteric fracture causing pain, shortening, and poor function.

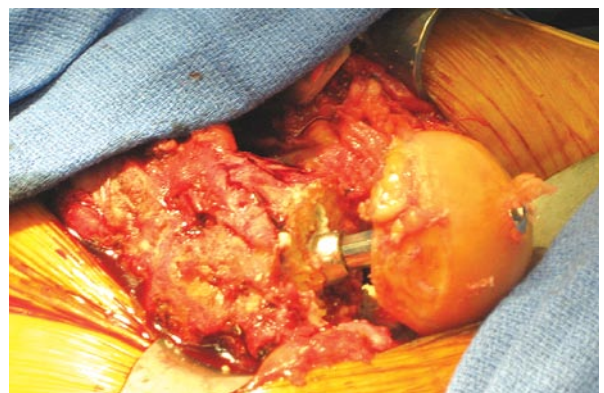
## SURGICAL TECHNIQUE

Surgical approaches for conversion THR from failed sliding hip screw fixation are similar to those for primary THR. We prefer to use the direct lateral approach with a “wafer-thin” modified anterior trochanteric osteotomy and dislocate the hip anteriorly. However, a trochanteric slide with a larger bony fragment is strongly considered when the greater trochanter is malunited or when we want to transfer the trochanteric fragment distally at the

“[We describe] a stepwise approach that can be used to prevent potential complications.”

end of the operation in order to adjust abductor tension. Plate and screws are left in place until the hip is dislocated to minimize the risk for intraoperative fracture.

After exposure of the hip joint, the lesser trochanter is identified. The femoral neck is then osteotomized (around the lag screw) after making a direct measurement of neck length above the lesser trochanter, according to the preoperative plan. Because of a potential medial bone defect of the proximal femur, this cut is sometimes right at the lesser trochanter. If the lesser

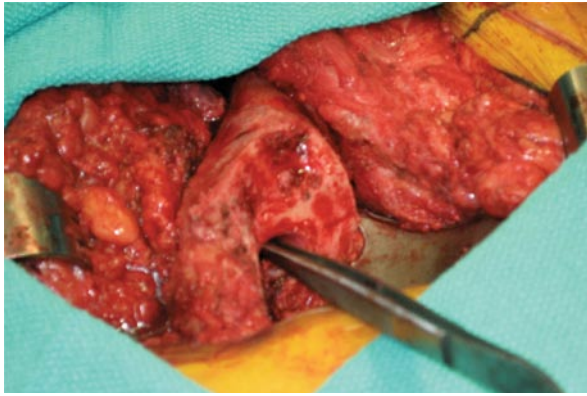

**Figure 1.** Conversion of failed fixation of an intertrochanteric fracture to total hip replacement. After a high-femoral neck osteotomy was made around the lag screw, the femoral head was taken out in retrograde fashion.

Dr. Unnanuntana is Orthopaedic Surgeon, and Dr. Goodman is Professor of Orthopaedic Surgery, Department of Orthopaedic Surgery, Stanford University Medical Center, Stanford, California.

Address correspondence to: Aasis Unnanuntana, MD, Department of Orthopaedic Surgery, Stanford University Medical Center, Stanford, CA 94035 (tel, 650-723-7072; fax, 650-723-6396; e-mail, uaasis@yahoo.com).

*Am J Orthop.* 2008;37(10):506-509. Copyright Quadrant HealthCom Inc. 2008. All rights reserved.



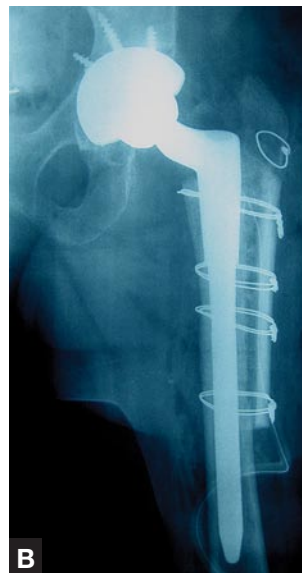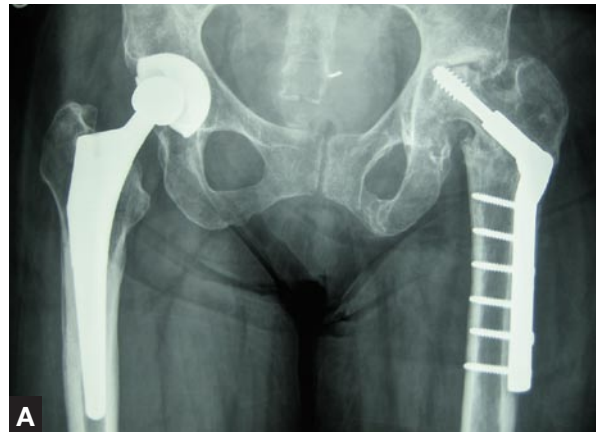**Figure 2.** Intramedullary remodeling and sclerosis around lag screw results in obliteration of the femoral canal, leaving a large hole as a false tract (pointed by the forceps).

trochanteric fragment is malunited or not united, other landmarks must be used. The femoral head together with the lag screw is taken out in retrograde fashion (Figure 1). The plate and screws over the lateral femoral cortex are exposed and removed through a longitudinal split posteriorly over the vastus lateralis muscle. We always prepare the femur first for hip replacement because it is adequately exposed at this point.

Usually, bone remodeled around the lag screw tract leads to intramedullary sclerosis and then obliteration of the femoral canal (Figure 2). A power burr may be needed for removal of sclerotic bone and recanalization of the femoral canal. Next, we use the smallest available reamers or rasps to prepare the femoral canal. This step is performed with great care because the risk for intraoperative femoral fracture is increased during conversion THR as a result of disuse osteoporosis, cortical defects and remodeling, deformity from malunion, and so forth. An appropriately sized femoral component should be selected before surgery. A calcar-replacing implant or an extended offset stem may be needed for restoring the proximal medial bone loss and obtaining a stable hip with equalization of limb lengths. Longer stemmed implants should be considered for bypassing the distal screw holes. Local bone grafting from the excised femoral head and structural allografts may be needed to augment the thinned lateral femoral cortex, commonly found at the plate site (Figure 3).

Fixation of the femoral component can be accomplished using either cemented or cementless implants. For cemented stems, care must be taken to prevent cement extrusion through the old screw holes during pressurization and prosthesis insertion. This can be done by various surgical techniques. We prefer simply bone grafting from the femoral head into the screw holes and having the assistant use his or her fingers to press firmly over the screw holes during cement pressurization, prosthesis insertion, and cement curing (Figure 4).

For the acetabular component, we usually use cementless fixation and prepare the acetabulum much



**Figure 3.** (A) Preoperative anteroposterior radiograph of woman in her mid-50s 8 years after sliding hip screw fixation of an intertrochanteric fracture. The patient presented with chronic groin and thigh pain and left hip shortening. She required a 3-inch shoe buildup and had fixed, 20° flexion and external rotation contracture of the hip. The radiograph shows a 6-hole sliding screw plate. There is medial displacement of the femoral shaft and varus malunion. The femoral head has collapsed, and the sliding hip screw has penetrated the femoral head and eroded

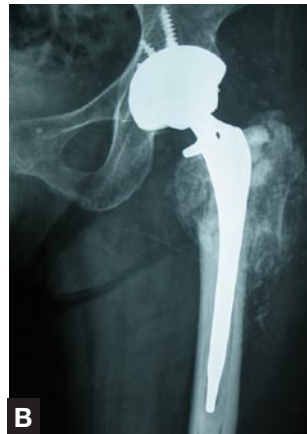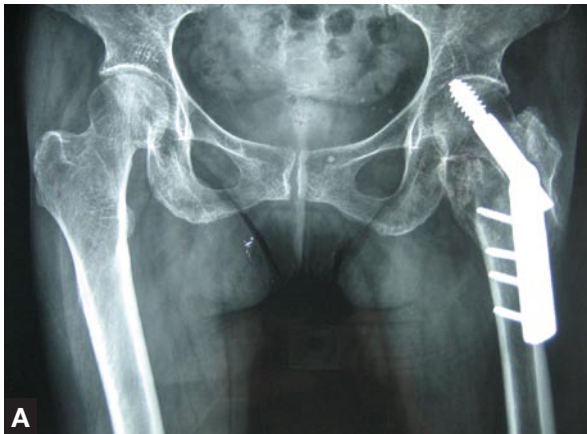the acetabulum. The lateral femoral cortex is very thin. (B) Postoperative anteroposterior radiograph after conversion total hip replacement using cementless femoral stem and socket demonstrates good prosthetic position. A structural allograft reinforces the thin lateral femoral cortex. The abductor position and length are restored.

as is done for any other primary THR. Two potential problems are disuse osteoporosis and hardware penetration causing an acetabular defect. Careful, non-aggressive reaming with frequent observation of the acetabular bed prevents iatrogenic protrusio. Defects from screw penetration are usually contained and easily managed with autologous bone grafting from the femoral head.

We tend to use larger femoral heads (32 or 36 mm) in the conversion THR setting because the patients usually have poor preoperative abductor tension and shortening, which increases the risk for postoperative dislocation. We prefer that the polyethylene liner be at least 6 mm thick.

### POSTOPERATIVE REGIMEN

For patients without any special considerations, gait training and ambulation are similar to those used for primary THR. For trochanteric slide and fixation per-



**Figure 4.** (A) Preoperative anteroposterior radiograph of woman in her early 70s 8 months after sliding hip screw fixation of an intertrochanteric fracture. The patient presented with severe pain and a limp that limited ambulation. The radiograph shows a malunited intertrochanteric fracture with medialization of the femoral canal, intramedullary remodeling around the lag screw tract, and lag screw cut out of the femoral head. (B)

Postoperative conversion total hip replacement using a cemented stem shows proper position of the prosthesis, good cement technique, correction of limb-length discrepancy, and restoration of abductor position and length. The trochanteric fragments had united previously. The excised femoral head was morselized and used as a bone graft laterally.

formed because of trochanteric nonunion, we recommend partial weight-bearing and use of an abduction brace for 6 weeks after surgery, and then progression as tolerated.

### DISCUSSION

Conversion to THR from malunited intertrochanteric fracture is indicated for posttraumatic osteoarthritis, penetration of the lag screw into the acetabulum, or (uncommonly) femoral head osteonecrosis. Clinical results are not comparable to those of primary THR.<sup>2-5</sup> In one study, Kaplan-Meier analysis with implant revision as an endpoint showed 10-year survivorship to be 87.5%.<sup>2</sup> Because of the anatomical changes in patients

head, have been used to minimize intraoperative complications. If the plate and screws are taken out first, the remaining thin cortices may not withstand the torsional force from dislocating the hip, which may result in a fracture of the proximal femur. Bone remodeling around the lag screw tract causes the femoral canal to be obliterated by sclerotic bone, leaving a large hole in the lateral femoral cortex (Figure 2). This can easily result in the surgeon's reaming and broaching too far laterally in the false tract. Using a power burr to open the femoral canal first is an important step before reaming and broaching to prevent fracture of the base of the greater trochanter.

The other often overlooked problem is abductor weakness secondary to trochanteric nonunion or mal-

**“Preoperative recognition of the anatomical changes in malunited intertrochanteric fractures is crucial in planning optimal surgical technique, instrumentation, and implants.”**

with failed internal fixation after intertrochanteric fracture, THR in this setting was technically challenging, and the rates of intraoperative and postoperative complications were higher than usual. Zhang and colleagues<sup>5</sup> reported a 47% incidence of early complication from conversion to THR in 19 patients. Thirty-two percent of the patients had a greater trochanteric fracture.

In addressing the difficulties of conversion to THR in malunited intertrochanteric fracture, we have described a stepwise approach that can be used to prevent potential complications. Before surgery, the surgeon should check for distortion of bony figure (malposition or nonunion of greater trochanter, medialization of femoral canal, intramedullary sclerosis) and for changes in surrounding soft-tissue tension. Some techniques, such as removal of side plate and screws after dislocation of femoral

union or shortening of the femur. This problem can be addressed with use of a large femoral head and/or transfer of the greater trochanter distally to tighten the abductor tension. In some patients with extensive anatomical distortion, including disruption of the hip abductors, a constrained liner may be considered.

Two issues regarding selection of the femoral component are still controversial: use of a cemented or cementless femoral implant and use of standard or longer stemmed components. Whether to use a cemented or a cementless femoral component depends on the bone quality and geometry of the femoral canal. When a cemented femoral stem is used, good cement pressurization is important. Because the cement might extrude through the previous screw holes, containment of cement during pressurization into the femoral canal

is difficult. Some relevant techniques are use of screws cut short to close the holes,<sup>6</sup> placement of surgical gloves injected with cement,<sup>7</sup> fashioning of bone plugs into the screw holes, and application of the assistant's thumb directly over the firmly packed gauze.

Theoretically, the surgeon should attempt to extend the length of the stem to more than twice that of the canal diameter beyond the most distal screw hole in order to prevent the "stress riser" effect. However, small defects, less than 20% to 30% of the bone diameter (eg, screw holes), were found in some studies to cause no significant reduction in torsional strength.<sup>8,9</sup> Zhang and colleagues<sup>5</sup> showed no stress fracture in any of 19 patients with a standard femoral component.

Preoperative recognition of the anatomical changes in malunited intertrochanteric fractures is crucial in planning optimal surgical technique, instrumentation, and implants. Such planning should help minimize operative time and perioperative complications while maximizing postoperative hip biomechanics.

#### **AUTHORS' DISCLOSURE STATEMENT**

Dr. Goodman wishes to note that he is a paid consultant to and has received research grants from

Zimmer, Inc. (Warsaw, IN). Dr. Unnanuntana reports no actual or potential conflict of interest in relation to this article.

#### **REFERENCES**

1. Kelley SS. Total hip arthroplasty after failed hip fracture fixation. In: Lieberman JR, Berry DJ, eds. *Advanced Reconstruction Hip*. Rosemont, IL: American Academy of Orthopaedic Surgeons; 2005:167-173.
2. Haidukewych GJ, Berry DJ. Hip arthroplasty for salvage of failed treatment of intertrochanteric hip fractures. *J Bone Joint Surg Am*. 2003;85(5):899-904.
3. Haentjens P, Casteleyn PP, Opdecam P. Hip arthroplasty for failed internal fixation of intertrochanteric and subtrochanteric fractures in the elderly patient. *Arch Orthop Trauma Surg*. 1994;113(4):222-227.
4. Mehlhoff T, Landon GC, Tullos US. Total hip arthroplasty following failed internal fixation of hip fractures. *Clin Orthop*. 1991;(269):32-37.
5. Zhang B, Chiu KY, Wang M. Hip arthroplasty for failed internal fixation of intertrochanteric fractures. *J Arthroplasty*. 2004;19(3):329-333.
6. Patterson BM, Salvati EA, Huo MH. Total hip arthroplasty for complications of intertrochanteric fracture. A technical note. *J Bone Joint Surg Am*. 1990;72(5):776-777.
7. Slater R, Morrison J, Kelly S. Custom-made molds that prevent cement extrusion through bone defects. *Clin Orthop*. 1995;(317):126-130.
8. Burstein AH, Currey J, Frankel VH, Heiple KG, Lunseth P, Vessely JC. Bone strength. The effect of screw holes. *J Bone Joint Surg Am*. 1972;54(6):1143-1156.
9. Edgerton BC, An KN, Morrey BF. Torsional strength reduction due to cortical defects in bone. *J Orthop Res*. 1990;8(6):851-855.