

# Surgical Anatomy of Latissimus Dorsi Muscle in Transfers About the Shoulder

Benjamin A. Goldberg, MD, Bassem Elhassan, MD, Steven Marciniak, MD, and Jonathan H. Dunn, MD

## Abstract

Transfer of the latissimus dorsi to the greater tuberosity has been used successfully in the treatment of massive rotator-cuff deficiency. For safe release and transfer of the tendon, the variations in the tendinous insertions of the latissimus dorsi and teres major onto the humerus need to be understood.

In anatomical dissection of 12 cadavers, mean width of the latissimus tendon was 3.3 cm at its insertion, and mean length was 7.3 cm. In all specimens, there were fascial connections between the latissimus and teres major and between the latissimus and the long head of the triceps.

There were 3 insertion patterns of the latissimus dorsi tendon onto the humerus with respect to the tendon of the teres major: completely separate (8 cadavers), loosely bound (3 cadavers), and completely joined (1 cadaver). If the latissimus dorsi were being transferred in the last type, the teres major would need to be transferred with the latissimus dorsi as a common musculotendinous unit.

Tears of the rotator cuff are common.<sup>1-4</sup> Patients with rotator-cuff tears can present with a wide range of clinical symptoms, from minor discomfort to debilitating pain and loss of function.<sup>1-3,5-11</sup>

Although most torn rotator cuffs can be repaired anatomically with conventional methods, some massive rotator-cuff tears and chronic rotator-cuff tears with extensive fatty degeneration are not successfully repaired either because technically they are irreparable given their large size or because there is a high recurrence rate after repair, dictated by the amount of fatty degeneration.<sup>12-15</sup>

Latissimus dorsi tendon transfer has been proposed as a treatment for irreparable tears of the rotator cuff.<sup>12-14</sup> Transfer requires the latissimus dorsi be released at its

Dr. Goldberg is Attending Physician, Department of Orthopaedic Surgery, University of Illinois at Chicago, Chicago, Illinois.

Dr. Elhassan is Consultant, Mayo Clinic, Rochester, Minnesota.

Dr. Marciniak is Orthopedic Surgeon, Castle Orthopaedics and Sports Medicine, Aurora, Illinois.

Dr. Dunn is Orthopedic Surgeon, Barrington Orthopedic Specialists, Buffalo Grove, Illinois.

Address correspondence to: Benjamin A. Goldberg, MD, Department of Orthopaedic Surgery, University of Illinois at Chicago, 835 S Wolcott Ave, M/C 844, Chicago, IL 60612 (tel, 312-996-7161; fax, 312-996-9025; e-mail, bgoldber@uic.edu).

*Am J Orthop.* 2009;38(3):E64-E67. Copyright 2009, Quadrant HealthCom Inc. All rights reserved.

insertion and sufficiently mobilized to minimize tension on the transferred tendon.<sup>13,14,16-19</sup> Variations in the surgical anatomy of the latissimus dorsi have not been well described in the literature but must be understood to perform transfers about the shoulder both safely and effectively. Although the anatomy of the distance relationship of the axillary and radial nerves to the latissimus dorsi with the arm in various positions has been described,<sup>20</sup> few investigators have reported differences in the relationship between the tendinous insertions of the latissimus dorsi and teres major as they insert onto the humerus.

In the present study, we sought to better define the surgical anatomy of the latissimus dorsi at its insertion for use in transfers about the shoulder.

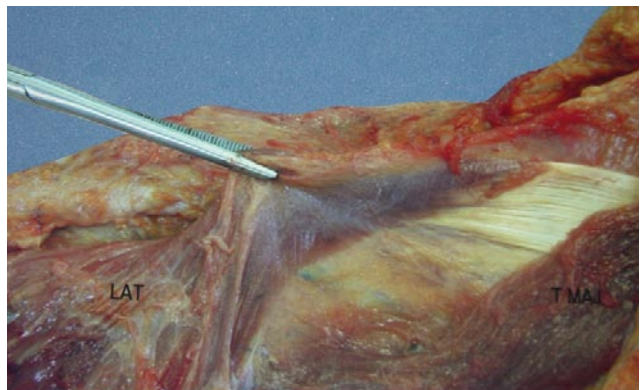
## MATERIALS AND METHODS

Anatomical dissection was meticulously performed on 10 fresh cadavers and 2 embalmed cadavers. All the dissections were performed by Dr. Marciniak. There was no evidence of rotator-cuff or other pathology of the shoulder girdle of these cadavers. Dissection was performed with cadavers in the lateral decubitus position.

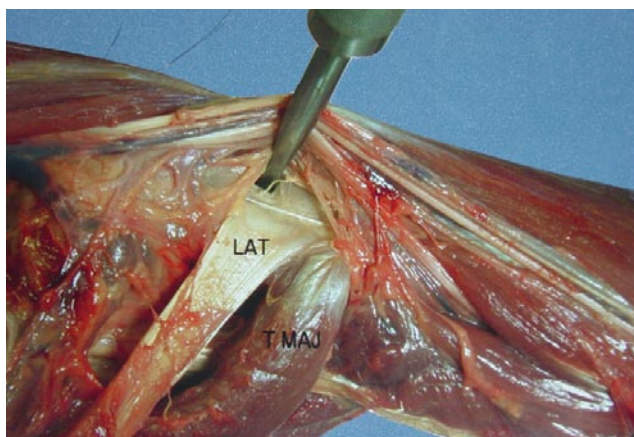
Fascial connections between the latissimus and other muscles of the shoulder girdle were noted. Length and width of the latissimus dorsi and the teres major tendons were measured. The insertional anatomy between the teres major and latissimus dorsi tendons was studied. The locations of the axillary and radial nerves were noted with respect to the teres major and latissimus dorsi tendons.

## RESULTS

For the latissimus tendon, mean width was 3.3 cm at its insertion, and mean length was 7.3 cm (Table). There were fascial connections between the muscle bellies of the latis-



**Figure 1.** Fascial connection between muscular portion of latissimus dorsi (LAT) and teres major (T MAJ) was present in all cases.

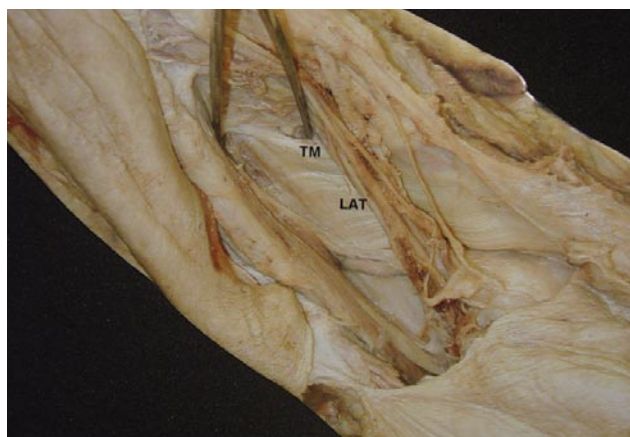

**Figure 2.** Separate and distinct tendons of latissimus dorsi (LAT) and teres major (T MAJ) as they insert on humerus—the most common insertional pattern in this study.

simus dorsi and teres major in all specimens (Figure 1). The tendons of the teres major and latissimus dorsi muscles near their insertions were found to have 3 distinct patterns. The first insertional pattern (Figure 2) had separate and distinct tendons of the latissimus dorsi and the teres major. These tendons, present in 8 (67%) of the specimens, were easily separated by gentle finger dissection. The second insertional pattern (Figure 3) consisted of a common tendinous insertion of the latissimus dorsi and teres major. These tendons, present in 3 cadavers (25%), were separated only with sharp division of fibrous connections. In the third insertional pattern (Figure 4), present in 1 cadaver (8%), tendons were completely conjoined and could not be separated.

All specimens had, between the latissimus dorsi and the long head of the triceps, a band of tissue representing the remnant of the dorsoepitrochlearis brachii of apes (Figure 5), and all specimens lacked an axillary arch of Langer. The insertion of the teres major was farther distal and posterior on the humerus in all specimens.

The location of the axillary and radial nerves near the insertion of the tendons was consistent in all 12 specimens. The axillary nerve was slightly posterior and proximal to the insertion of latissimus and was covered by a fibrous sheath. The radial nerve was anterior and distal to the insertion of the latissimus dorsi tendon and covered by fat.



**Figure 3.** Tendons of latissimus dorsi (LAT) and teres major (TM) have common tendinous insertion on humerus and can be separated with sharp dissection.

## DISCUSSION

There is no consensus on how to define a massive tear. According to Cofield,<sup>21</sup> the diameter of a massive tear is at least 5 cm. For the rate of recurrence after repair, Goutallier and colleagues<sup>15</sup> demonstrated that only in cuffs with minimal fatty degeneration and a low index of global fatty degeneration is there a good chance of satisfactory anatomical repair 3 years after surgery. They found a significant association between recurrent tearing of each rotator-cuff tendon and presurgical fatty degeneration of the muscle.

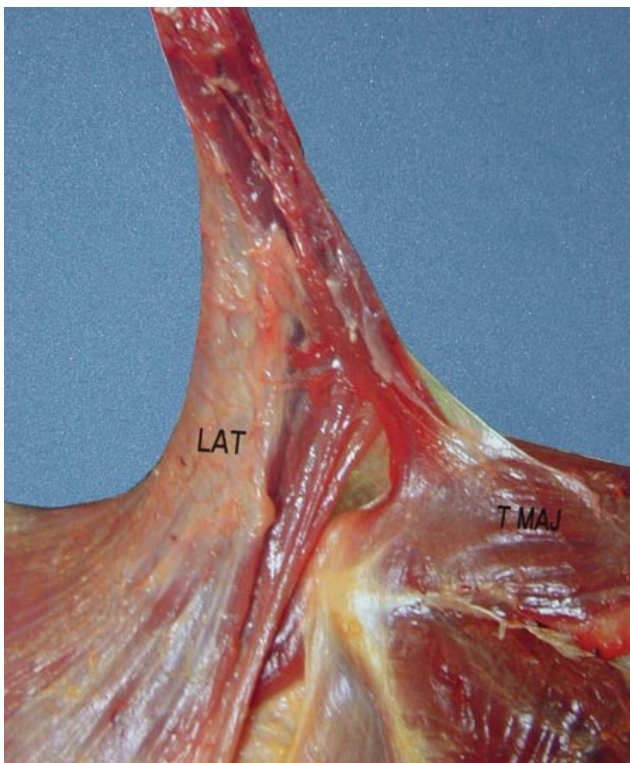
Massive irreparable rotator-cuff tears can lead to significant functional impairment, weakness, and pain caused by cranial migration of the humeral head, which eventually results in cuff tear arthropathy and progressive loss of the deltoid lever arm.<sup>14</sup>

An irreparable tear can be managed with either open or arthroscopic débridement, which helps provide pain relief but does not restore strength.<sup>4,22,23</sup> In patients with pain and weakness, distant tendon transfers have been proposed to manage irreparable rotator-cuff tears. For a tendon to be ideal for transfer around the shoulder, it should be of enough length, strength, and excursion, and its transfer should be associated with the least deficit. Results from studies have shown that the latissimus dorsi muscle makes an ideal pedicled flap because of its long neurovascular

**Table. Width, Length, and Insertional Pattern on Humerus of Latissimus Dorsi Tendon With Respect to Teres Major Tendon**

Specimen	Width (cm)	Length (cm)	Insertion
1	3.1	7.8	Separate
2	2.7	7.3	Separate
3	4.2	6.6	Joined
4	3.4	7.5	Separate
5	3.3	7.4	Separate
6	3.5	7.1	Bound
7	3.3	7.3	Separate
8	3.5	6.9	Bound
9	3.8	7.6	Separate
10	3.5	7.7	Separate
11 (embalmed)	3.1	7.4	Bound
12 (embalmed)	2.6	6.7	Separate

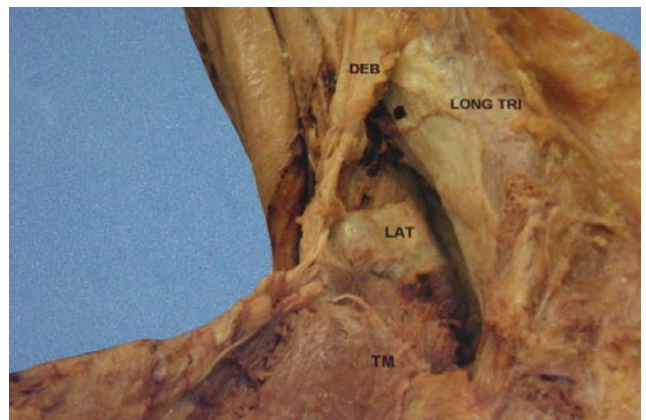




**Figure 4.** Tendons of latissimus dorsi (LAT) and teres major (T MAJ) are completely conjoined and not able to be separated with sharp dissection.

pedicle and large size, which minimize the possibility of injury to the neurovascular pedicle from traction and dissection.<sup>24</sup> Moreover, Herzberg and colleagues<sup>25</sup> found much larger excursion of the latissimus dorsi musculotendinous unit (33.9 cm) compared with the supraspinatus (6.7 cm), which facilitates its mobilization and use for muscle transfer around the shoulder. Both the latissimus dorsi and teres major have been described as having the largest depressor (adductor) moment arms on the shoulder.<sup>26</sup> In a biomechanical study using outcome variables such as moment arms, muscle length, and muscle force, Magermans and colleagues<sup>27</sup> concluded that a tendon transfer of the teres major to the supraspinatus insertion produces excellent functional outcome in the treatment of massive rotator-cuff tears. Thus, transfer of the conjoined and inseparable pattern of latissimus/teres major tendon could still be performed successfully, despite the lower excursion of these combined tendons compared with the latissimus tendon alone.<sup>28</sup>

For improved excursion during surgery, the fascial connections between the muscle bellies of the teres major and latissimus dorsi should be released. There is also a fascial band between the long head of the triceps and the latissimus dorsi near the musculotendinous junction that needs to be released. This band represents the dorsoepitrochlearis brachii of apes and may remain as a muscular remnant in some specimens.<sup>17</sup> Although not encountered in the 12 specimens dissected for the present study, there may be a muscular slip, called the axillary arch of Langer, that runs transversely from the anterior superior border of the latissi-



**Figure 5.** Fascial band of tissue between latissimus dorsi (LAT) and long head of triceps (LONG TRI) was present in all specimens and represents dorsoepitrochlearis brachii (DEB) of apes. TM, teres major.

mus to the tendon of the pectoralis major, coracobrachialis, or the bicipital fascia. This muscular slip runs anterior to the axillary vessels and should be divided to prevent the possibility of compression of these vital structures after the muscle is transferred. The axillary arch, well described in the breast oncology literature,<sup>29-31</sup> appears to be less prevalent; incidence is 0.25% to 0.8%, versus the 7% incidence previously described.<sup>17</sup>

Care must be taken to avoid damage to the axillary and radial nerves during tendon release, given the proximity of these structures to the latissimus tendon. Cleeman and colleagues<sup>20</sup> performed a cadaveric study to determine the distance relationship of the latissimus dorsi tendon to the axillary and radial nerves with the shoulder in different positions. They found that the mean distance from the latissimus dorsi insertion to the axillary and radial nerves with the shoulder flexed and the arm internally rotated was 2.3 cm and 2.8 cm, respectively; these distances changed to 1.8 cm and 2.0 cm, respectively, with the shoulder abducted and the arm internally rotated. These findings indicate that the safer surgical approach is with the shoulder flexed and the arm internally rotated.

Transfer of the latissimus dorsi to the greater tuberosity has been found to have promising functional results in the treatment of massive, irreparable rotator-cuff deficiency,<sup>12,14,16,18,19</sup> but its use after failure of prior rotator-cuff surgery makes outcomes less predictable.<sup>32</sup> Gerber and colleagues<sup>12-14</sup> reported outcomes with latissimus tendon transfer for irreparable rotator-cuff tear. After follow-up of about 5 years, 94% of patients had significant relief of pain at rest, and 75% had relief of pain with exertion.<sup>13</sup> Mean active flexion of the shoulder was 123°.

Morelli<sup>18</sup> and Miniaci and MacLeod<sup>19</sup> reported similar results in 17 patients with a 2- to 5-year follow-up. Fourteen patients had significant relief of their pain and improved function; the 3 patients who did poorly had work-related injuries. Aoki and colleagues<sup>16</sup> reported on 12 patients with a mean follow-up of 3 years. Eight patients had good or excellent results, with mean active flexion of 135°.

In conclusion, the latissimus dorsi tendon transfer for irreparable rotator-cuff tears can be performed safely and successfully. However, thorough understanding of the complex anatomical variations is essential for providing tension-free transfer while minimizing complications.

### AUTHORS' DISCLOSURE STATEMENT

The authors report no actual or potential conflict of interest in relation to this article.

### REFERENCES

- Bartolozzi A, Andreychik D, Ahmad S. Determinants of outcome in the treatment of rotator cuff disease. *Clin Orthop*. 1994;(308):90-97.
- Goldberg BA, Lippitt SB, Matsen FA 3rd. Improvement in comfort and function after cuff repair without acromioplasty. *Clin Orthop*. 2001;(390):142-150.
- Goldberg BA, Nowinski RJ, Matsen FA 3rd. Outcome of nonoperative management of full-thickness rotator cuff tears. *Clin Orthop*. 2001;(382):99-107.
- Rockwood CA Jr, Williams GR Jr, Burkhead WZ Jr. Debridement of degenerative, irreparable lesions of the rotator cuff. *J Bone Joint Surg Am*. 1995;77(6):857-866.
- Bateman JE. Diagnosis and treatment of rupture of the rotator cuff. *Surg Clin North Am*. 1963;43:1523-1530.
- Bokor DJ, Hawkins RJ, Huckell GH, Angelo RL, Schickendantz MS. Results of nonoperative management of full-thickness tears of the rotator cuff. *Clin Orthop*. 1993;(294):103-110.
- Ellman H, Hanker G, Bayer M. Repair of the rotator cuff. End-result study of factors influencing reconstruction. *J Bone Joint Surg Am*. 1986;68(8):1136-1144.
- Essman JA, Bell RH, Askew M. Full-thickness rotator-cuff tear. An analysis of results. *Clin Orthop*. 1991;(265):170-177.
- Hawkins RH, Dunlop R. Nonoperative treatment of rotator cuff tears. *Clin Orthop*. 1995;(321):178-188.
- Itoi E, Tabata S. Conservative treatment of rotator cuff tears. *Clin Orthop*. 1992;(275):165-173.
- Neviaser RJ. Ruptures of the rotator cuff. *Orthop Clin North Am*. 1987;18(3):387-394.
- Gerber C. Latissimus dorsi transfer for the treatment of irreparable tears of the rotator cuff. *Clin Orthop*. 1992;(275):152-160.
- Gerber C, Hersche O. Tendon transfers for the treatment of irreparable rotator cuff defects. *Orthop Clin North Am*. 1997;28(2):195-203.
- Gerber C, Vinh TS, Hertel R, Hess CW. Latissimus dorsi transfer for the treatment of massive tears of the rotator cuff. A preliminary report. *Clin Orthop*. 1988;(232):51-61.
- Goutallier D, Postel JM, Gleyze P, Leguilloux P, Van Driessche S. Influence of cuff muscle fatty degeneration on anatomic and functional outcome after simple suture of full-thickness tears. *J Shoulder Elbow Surg*. 2003;12(6):550-554.
- Aoki M, Okamura K, Fukushima S, Takahashi T, Ogino T. Transfer of latissimus dorsi for irreparable rotator-cuff tears. *J Bone Joint Surg Br*. 1996;78(5):761-766.
- Gray H, Clemente CD. *Anatomy of the Human Body*. 30th Am ed. Philadelphia, PA: Lea & Febiger; 1985.
- Morelli M, Nagamori J, Gilbert M, Miniaci A. Latissimus dorsi tendon transfer for massive irreparable cuff tears: an anatomic study. *J Shoulder Elbow Surg*. 2008;17(1):139-143.
- Miniaci A, MacLeod M. Transfer of the latissimus dorsi muscle after failed repair of a massive tear of the rotator cuff. A two to five-year review. *J Bone Joint Surg Am*. 1999;81(8):1120-1127.
- Cleeman E, Hazrati Y, Auerbach JD, Shubin Stein K, Hausman M, Flatow EL. Latissimus dorsi tendon transfer for massive rotator cuff tears: a cadaveric study. *J Shoulder Elbow Surg*. 2003;12(6):539-543.
- Cofield RH. Subscapular muscle transposition for repair of chronic rotator cuff tears. *Surg Gynecol Obstet*. 1982;154(5):667-672.
- Ellman H. Arthroscopic subacromial decompression: analysis of one- to three-year results. *Arthroscopy*. 1987;3(3):173-181.
- Gartsman GM. Arthroscopic acromioplasty for lesions of the rotator cuff. *J Bone Joint Surg Am*. 1990;72(2):169-180.
- Pierce TD, Tomaino MM. Use of the pedicled latissimus muscle flap for upper-extremity reconstruction. *J Am Acad Orthop Surg*. 2000;8(5):324-331.
- Herzberg G, Urien JP, Dimnet J. Potential excursion and relative tension of muscles in the shoulder girdle: relevance to tendon transfers. *J Shoulder Elbow Surg*. 1999;8(5):430-437.
- Kuechle DK, Newman SR, Itoi E, Morrey BF, An KN. Shoulder muscle moment arms during horizontal flexion and elevation. *J Shoulder Elbow Surg*. 1997;6(5):429-439.
- Magermans DJ, Chadwick EK, Veeger HE, van der Helm FC, Rozing PM. Biomechanical analysis of tendon transfers for massive rotator cuff tears. *Clin Biomech (Bristol, Avon)*. 2004;19(4):350-357.
- Zachary RB, Leeds MB. Transplantation of teres major and latissimus dorsi. *Lancet*. 1947;2:757-758.
- Daniels IR, della Rovere GQ. The axillary arch of Langer—the most common muscular variation in the axilla. *Breast Cancer Res Treat*. 2000;59(1):77-80.
- Petrasek AJ, Semple JL, McCready DR. The surgical and oncologic significance of the axillary arch during axillary lymphadenectomy. *Can J Surg*. 1997;40(1):44-47.
- Serpell JW, Baum M. Significance of 'Langer's axillary arch' in axillary dissection. *Aust N Z J Surg*. 1991;61(4):310-312.
- Warner JJ. Management of massive irreparable rotator cuff tears: the role of tendon transfer. *Instr Course Lect*. 2001;50:63-71.