

A Reliable and Simple Solution for Recalcitrant Carpal Tunnel Syndrome: The Hypothenar Fat Pad Flap

Cesare Fusetti, MD, Guido Garavaglia, MD, Christophe Mathoulin, MD, John Gianfranco Petri, MD, and Stefano Lucchina, MD

Abstract

The incidence of failure in open carpal canal tunnel decompression is underestimated. Recurrence is often the result of scarring of the median nerve. Conservative treatment or careful neurolysis is usually insufficient.

The hypothenar fat pad flap interposes adipose tissue from the hypothenar eminence and could offer a solution for patients with recalcitrant carpal tunnel syndrome. We reviewed the results of using this procedure in 20 patients with recalcitrant carpal tunnel syndrome and analyzed subjective and objective results, complications, and pitfalls. For 18 patients, pain disappeared completely. Two-point discrimination improved from an expanded range to normal in 16 of the 20 patients. Quick DASH (Disabilities of the Arm, Shoulder, and Hand) scores improved significantly.

The hypothenar fat pad flap, a technically simple procedure, prevents median nerve readherence, produces excellent results, and should be included among the tools any surgeon uses for carpal tunnel surgery.

Carpal tunnel syndrome (CTS), the most common entrapment neuropathy, afflicts up to 10% of the general population. Many carpal tunnel releases are performed annually, and the procedure is regarded as simple and fast, with the risk that its potential complications may be under-

estimated. Persistent symptoms are usually attributed to an inadequate distal ligament release or a severe, chronic, irreversible nerve compression. Recurrent symptoms often result from scarring of the median nerve, which is fixed to the radial leaf of the divided transverse carpal ligament. These adhesions interfere with the physiologic gliding of the median nerve during wrist motion. Simple neurolysis is insufficient to prevent new scar formation or relieve hyperesthesia

“The surgical incision for HTFPF should be more ulnarly placed to harvest the flap more easily...”

and allodynia. Various procedures have been described for recalcitrant CTS (RCTS), but many are technically demanding and may require the sacrifice of normal tissue and muscles.

The hypothenar fat pad flap (HTFPF) procedure was initially described by Cramer.¹ This pedicled fat pad flap is locally available, its mobilization is safe, its results reliable, and its postoperative complications rare. In this article, we describe the technique and pre-

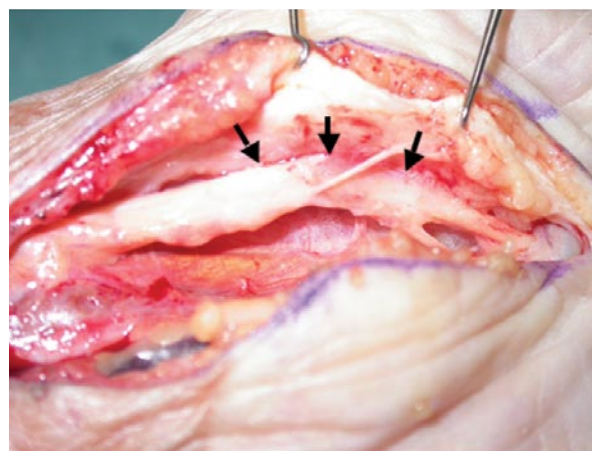


Figure 1. Median nerve (arrows) is adherent to radial leaf of divided transverse ligament.

Dr. Fusetti is Consultant, Hand Surgery Unit, Department of Orthopaedics and Traumatology, and Dr. Garavaglia is Chief, Department of Orthopaedics and Traumatology, Ospedale San Giovanni, Bellinzona, Switzerland.

Dr. Mathoulin is Professor and Consultant, Clinique Jouvenet, Hand Surgery Unit, Institut de la Main, Paris, France.

Dr. Petri is Chief, Department of Orthopaedics and Traumatology, and Dr. Lucchina is Consultant, Hand Surgery Unit, Ospedale San Giovanni, Bellinzona, Switzerland.

Address correspondence to: Cesare Fusetti, MD, FMH-EBHS, Hand Surgery Unit, FMH-EBHS, Department of Orthopaedics and Traumatology, Ospedale San Giovanni, CH-6500, Bellinzona, Switzerland (tel, 41-91-811-8082; fax, 41-91-811-8083; e-mail, cfusetti@yahoo.com).

Am J Orthop. 2009;38(4):181-186. Copyright, Quadrant HealthCom Inc. 2009. All rights reserved.

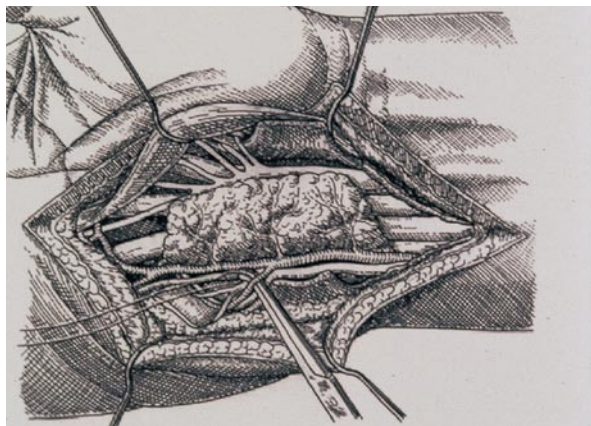


Figure 2. Deep branch of ulnar artery, running along deep motor branch of ulnar nerve, is dissected and ligated (Mathoulin's artifice). Copyright 2009, Mathoulin, Dorn.

sent our results in the form of a case series involving 20 consecutive patients with RCTS.

MATERIALS AND METHODS

Between June 2004 and June 2006, 20 patients with RCTS were managed with HTFPF and followed at our institution for at least 12 months (mean, 13 months; range, 12-24 months). There were 12 women and 8 men. Mean age was 56 years (range, 38-85 years). All procedures were performed by Dr. Fusetti. Four of the 20 patients had previously undergone open carpal tunnel decompression by the same surgeon; the other 16 patients were referred to our institution after previous open carpal tunnel surgery (mean time since last failed operation, 17 months; range, 6-42 months). Nine patients were in a worker's compensation group; 4 of these 9 patients lost their jobs because of prolonged absence from work. Patients with RCTS after endoscopic decompression or after internal fixation of a distal radius fracture were excluded.

All patients met the inclusion criteria for RCTS (Table). For all patients, conservative treatment by an experienced hand therapist over at least 6 months (range, 6-17 months) had failed, and 2 patients needed psychological support. Six patients experienced probatory unsuccessful infiltration of the carpal tunnel. Two patients had 1 failed case and another patient had 2 failed cases of neurolysis without flap interposition.

Subjective complaints were evaluated. The shortened Quick DASH (Disabilities of the Arm, Shoulder,

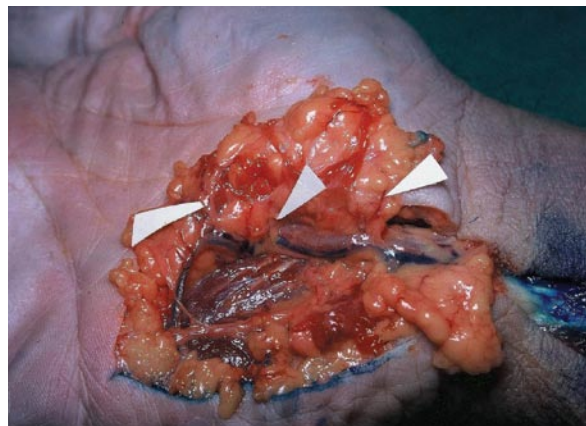

Figure 3. Cadaver dissection shows transverse arterial branches to fat pad arising from medial side of ulnar artery. Flap is pedicled on superficial branches of ulnar artery after section of deep branch of ulnar artery.

and Hand) questionnaire was used to evaluate disability and to monitor changes in symptoms and function over time. The optional High-Performance Sport/Music or Work modules were not used.

Mean preoperative Quick DASH score was 75.8 (median, 79.5; range, 68.2-88.6). Significant palmar hypersensitivity or allodynia was present in all 20 patients; nocturnal tingling and/or pain was present in 18 patients. All patients felt that their condition had worsened after the first operation.

On clinical examination, 12 of the 16 referred patients presented an incision scar placed too radially along the axis of the third metacarpal. In 8 patients, the incision was along the axis of the fourth metacarpal. All patients had marked irritation signs (Tinel, Phalen, and Durkan signs). The 2-point Weber discrimination test averaged 9 mm (range, 5-14 mm). In 3 patients, there was complete numbness. Thenar muscle atrophy was present in 7 patients. Mean grip strength with the Jamar dynamometer test was 27 kg (range, 8-42 kg).

All patients underwent preoperative nerve conduction studies. After the first operation, 17 patients had their conduction parameters worsen, 1 had unchanged parameters, and 2 had normal parameters. Seven patients had abolished conduction parameters. Denervation signs of the thenar muscles were present in 3 patients.

Informed preoperative written consent for the surgical procedure was obtained from each patient.

Table. Inclusion Criteria for Recalcitrant Carpal Tunnel Syndrome^a

1. Persistent or recurrent carpal tunnel syndrome after adequate open surgical decompression.
2. Failure of conservative treatment.
3. No other major wrist surgery.
4. Preoperative median nerve hypersensitivity at wrist without clinical evidence of damage to the palmar cutaneous branch of median nerve or intraoperative findings of median nerve adherence to the transverse carpal ligament.

^aAdapted from Strickland et al.²⁵

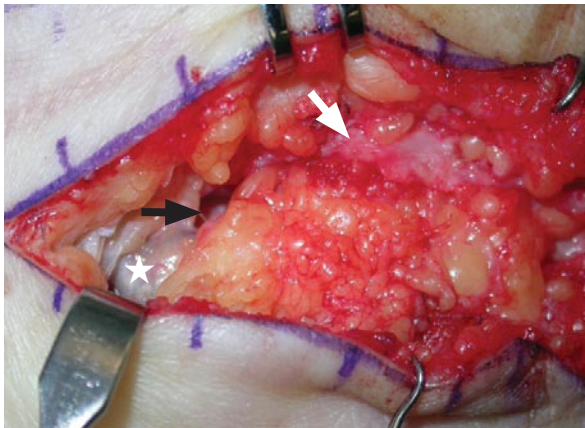


Figure 4. Flap can be advanced over median nerve (black arrow) and placed palmar to nerve and dorsal to radial leaf (white arrow) of transverse ligament. Note ulnar neurovascular bundle (white star).

Surgical Technique

With general anesthesia, loupe magnification, and pneumatic tourniquet, a linear incision is made 0.5 cm from the previous scar on its ulnar side, in line with the ulnar border of the third digit. The incision is then curved at the wrist crease and continued along the flexor carpi ulnaris tendon. The remnants of the transverse carpal ligament are opened on its ulnar side, and the median nerve is identified (Figure 1). A cleavage plane is developed by sharp dissection starting from an unscarred region. Epineurolysis of the median nerve is performed only when the scar does not allow identification of an evident dissection plane.

Initial subdermal dissection of the hypothenar fat is continued as far as the insertion of the palmaris brevis muscle with identification of the ulnar neurovascular bundle. The ulnar pedicle need not be dissected unless the flap cannot be mobilized over the median nerve. Distally, care is taken not to injure the digital nerves to the ring and small fingers while the undermining continues medially to the midpalm. Deep mobilization of the flap is possible after excision of a segment of the ulnar leaf of the transverse carpal ligament. The flap is then elevated until the ulnar nerve and artery are visualized. At this point, flap mobility is tested to determine if the flap can be advanced easily over the median nerve.

When the flap pedicle is under tension, we adopt the Mathoulin artifice²: The deep branch of the ulnar artery, running along the deep motor branch of the ulnar nerve, is identified and divided (Figures 2, 3). This artifice is not necessary when the flap is advanced easily over the median nerve and placed palmar to the nerve and dorsal to the radial leaf of the transverse ligament. The flap is hinged like a page in a book; what was to the ulnar side of the flap is fixed with 3 mattress nonresorbable sutures to the radial edges of the transverse carpal canal (Figure 4). After skin closure, the wrist is immobilized in neutral position for 2 weeks while digital motion is encouraged. Hand therapy

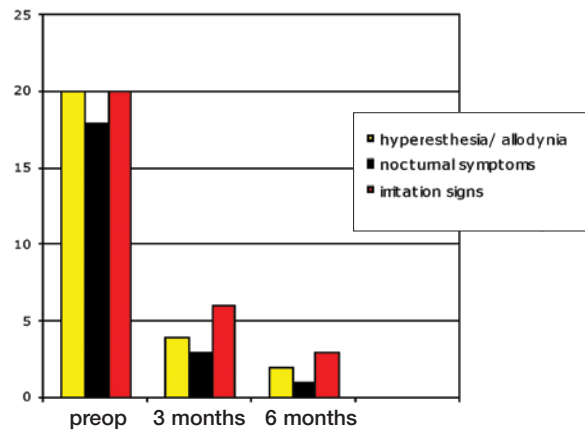


Figure 5. Subjective complaints (preoperative, 3 months, 6 months).

with a desensitization program begins after removal of the stitches. Nocturnal wrist splinting is continued for 2 additional weeks; heavy lifting and sport are not allowed for 8 weeks.

RESULTS

Our study results appear in Figures 5 and 6. In 16 patients, the median nerve adhered to the radial leaf of the divided transverse carpal ligament (Figure 1); in the other 4 patients, the scar did not allow the surgeon to identify an evident cleavage plane between the epineural surface and the remnants of the transverse carpal ligament. One patient had an associated neuroma of the palmar branch of the median nerve, with no clinical preoperative evidence. The neuroma was excised in association with HTFPF. Ligation of the deep branch of the ulnar artery was necessary in 4 patients.

Subjective complaints and objective data were recorded by all 20 patients for follow-up evaluations 3, 6, and 12 months after surgery. Quick DASH scores were obtained at 3 and 12 months. Two patients were also evaluated 24 months after HTFPF, during decompression of the contralateral symptomatic carpal tunnel.

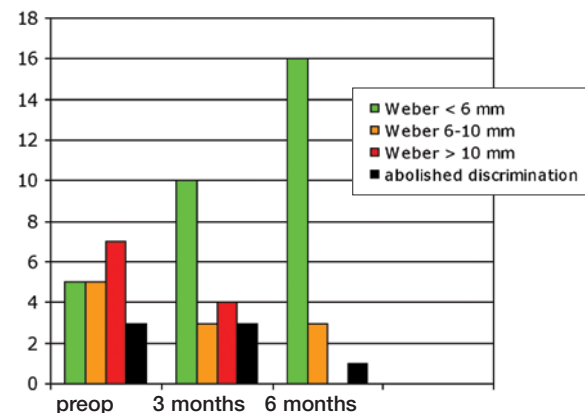


Figure 6. Two-point discrimination (Weber test).

Subjective Complaints

Hyperesthesia and allodynia were completely alleviated in 16 (80%) of the 20 patients after 3 months and in 18 patients (90%) after 6 months (Figure 5). At final examination (12 months), 2 patients had residual hypersensitivity. Seventeen patients (85%) had complete relief of paresthesia and nocturnal pain after 3 months. One patient had no improvement 12 months after HTFPF.

The satisfaction rate remained very high. Nineteen patients (95%) said they would recommend the procedure. One patient, whose previous symptoms and signs showed no improvement, was unsatisfied.

At 3 months, mean Quick DASH score was 33.6 (median, 34.1; range, 13.7-79.5). The worker's compensation group mean was 37.8, and the non-worker's compensation group mean was 28.5.

At 12 months, mean Quick DASH score was 18.2 (median, 13.6; range, 9.1-75). The worker's compensation group mean was 22.6, and the non-worker's compensation group mean was 12.8.

Objective Results

Pathognomonic irritation signs (Phalen, Durkan, and Tinel signs) were still present in 6 patients (30%) at 3 months and in 3 patients (15%) at final follow-up (Figure 5). The irritation signs were subjectively less marked than before the operation.

By final examination, 2-point discrimination had improved from a wide range to less than 6 mm in 16 patients and remained between 6 and 10 mm in 3 patients; 1 patient had an abolished 2-point discrimination (Figure 6). Thenar muscle atrophy was present in 4 patients at 6-month follow-up. For the 4 patients with expanded or abolished 2-point discrimination and persistent atrophy, electroneuromyography (ENMG) was performed 12 months after HTFPF. In 3 patients, ENMG showed ameliorated electrophysiologic parameters. The patient with persistent abolished 2-point discrimination had persistent pathologic ENMG parameters and denervation signs of the thenar muscles. By final evaluation, mean grip strength had increased from 27 kg to 40 kg.

Seven of the 9 patients in the worker's compensation group returned to work; 5 of these 7 resumed their original tasks. Mean time to return to work after HTFPF was 16 weeks.

Complications

One patient had 2 complications—persistent paresthesia on the ulnar border of the fifth finger and concomitant superficial infection of the scar. The superficial infection resolved with local therapy in 10 days, and the paresthesia resolved spontaneously within 2 months.

DISCUSSION

Idiopathic CTS is the most common entrapment neuropathy. According to Atroshi and colleagues,³ 1 in 5 people in the general population would be expected

to have CTS. Surgical release of the carpal tunnel, the most common reason for referral in elective hand surgery, almost doubled between 1990 and 2000.⁴ In the United States, costs related to CTS care exceed \$2 billion per year.⁵

Carpal tunnel release (CTR) is regarded as a simple, fast, and successful surgical procedure carried out by various surgical specialists (hand surgeons, orthopedic surgeons, general surgeons, neurosurgeons), but patients and surgeons alike run the risk of underestimating the potential complications of this outpatient procedure.

Complications (and their socioeconomic consequences) represent a real challenge for the surgeon who performs CTR.⁶⁻¹⁵ The incidence of failure in open carpal tunnel decompression ranges from 4% to 25%.¹⁶⁻¹⁸ Reoperation is needed in up to 3% of patients.¹⁹

Persistent symptoms are usually related to an inadequate distal ligament release,^{2,18-27} but revision surgery can be largely avoided by reducing technical errors during the primary operation.^{19,20} These errors are attributed to a combination of unfamiliarity with the relevant anatomy and the trend toward smaller incisions.¹⁸⁻²⁷

Recurrent symptoms often result from scarring of the median nerve, which is fixed to the radial leaf of the divided transverse carpal ligament. These adhesions interfere with the physiologic gliding of the median nerve during wrist motion.^{2,18,24-27}

Simple neurolysis is insufficient to prevent new scar formation and to relieve patients from hyperesthesia and allodynia.^{2,24-27} Two of the 20 patients in our series had a case of failed neurolysis, and 1 patient had 2 failed cases. More studies are needed to determine if collagenase-based products are effective in preventing new scar formation after CTR.²⁸⁻³⁰

The difficult problem of RCTS has been addressed with various procedures,³¹⁻⁴² but most are technically demanding and use tissues that may be inadequate in position or dimension to cover the median nerve. In addition, these techniques often require the sacrifice of normal tissue, and most require advanced microsurgical experience.^{31,35} Although all patients reported improvement in their symptoms, the literature series on which to base a reliable statistical analysis of objective results is insufficient.

HTFPF, first described by Cramer¹ in 1985 and successively refined,^{2,25} represents a local and simple solution with few complications.

Our results are comparable to those reported by others,^{2,19,25-27} particularly in reproducing the temporal evolution of symptoms and signs. However, clinical results in terms of median nerve functional recovery cannot be predicted. Using flaps to protect a damaged median nerve cannot guarantee a favorable result in terms of recovery of both sensory and motor deficits.

Hyperesthesia and allodynia were progressively alleviated within 6 months. Seventeen (85%) of our 20 patients had complete relief of paresthesia and noc-

tural pain after 3 months, and the patient satisfaction rate remained high; 19 patients (95%) said they would recommend the procedure. Clinically, we noted significant regression of signs of irritation with progressive improvement in 2-point discrimination. DASH scores improved significantly.

Because of the small number of patients—4 of the 9 patients in the worker's compensation group had already lost their jobs because of prolonged absence before our intervention—it is not possible to draw any significant conclusions about the effect of secondary worker's compensation. In their analysis of patients with and without worker's compensation, Strickland and colleagues²⁵ found no statistically significant difference between subjective and objective results. A significant difference was noted only for manual labor, indicating that worker's compensation patients with high demands on their hands have a higher tendency to not resume work as easily as worker's compensation patients with low demands on their hands.

Preoperative electrophysiologic examinations, usually not needed after CTR, are effective in defining underlying neurologic illness and identifying an irreversible injury caused by the initial nerve compression.

Before surgery, it is important to distinguish patients with RCTS from patients with neuroma of the palmar branch of the median nerve (PBMN). Although we systematically look for such neuromas before surgery, in 1 patient we found a clinically nonevident neuroma of the PBMN associated with extensive scarring of the main trunk. We recommend intraoperative systematic exploration for a concomitant lesion of the PBMN, particularly when the primary incision has been placed too far radially.

In our patient's case, we performed excision-stripping of the entire palmar cutaneous branch from the main trunk of the median nerve according to Lanzetta and Noli,⁴³ and the consequent area of numbness in the palm did not represent a significant problem for this patient, who had complete relief from pain and discomfort after the procedure.

Alternative procedures include implantation of the PBMN in the pronator quadratus⁴⁴ or nerve conduit.⁴⁵

The surgical incision for HTFPF should be more ulnarly placed to harvest the flap more easily and to prevent formation of small subcutaneous neuromas. We emphasize the importance of an ulnarly placed incision in line of the ulnar border of the third digit, resulting in an incision along the fourth ray, in agreement with Roure and Masquelet⁴⁶ for primary CTR and for revision surgery. An incision placed too far radially (as found in 12 of our patients) leads to division of the flexor retinaculum immediately palmar to the median nerve, so that the nerve can be displaced toward the surface, increasing the risk for epineurial fibrotic fixation.

In our study and in the recent literature,^{18,19,25-27} the complication rate for HTFPF is low, provided that revi-

sion surgery is performed by skilled surgeons who have mastered the different revision options² and, if needed as an alternative, the microsurgical flaps.^{31,35}

Patients who are dissatisfied with previous surgery and dubious about secondary microsurgical procedures need an easy-to-perform operation with locally available and anatomically constant structures. We believe HTFPF fulfills these criteria and permits nerve decompression, maintenance or enhancement of blood supply, and preservation of a gliding bed.

AUTHORS' DISCLOSURE STATEMENT AND ACKNOWLEDGMENTS

The authors report no actual or potential conflict of interest in relation to this article.

Poster presentation at FESSH Congress, Athens, 2007, and communication at Swiss Hand Surgery Congress, Luzern, 2006.

REFERENCES

1. Cramer LM. Local fat coverage for the median nerve. In: Lanford LL, ed. *Correspondence Newsletter for Hand Surgery*. 1985:35.
2. Mathoulin C, Bahm J, Roukoz S. Pedicled hypothenar fat flap for median nerve coverage in recalcitrant carpal tunnel syndrome. *Hand Surg*. 2000;5(1):33-40.
3. Atroshi I, Gummesson C, Johnsson R, Ornstein E, Ranstam J, Rosén I. Prevalence of carpal tunnel syndrome in a general population. *JAMA*. 1999;282(2):153-158.
4. Wildin C, Dias JJ, Heras-Palou C, Bradley MJ, Burke FD. Trends in elective hand surgery referrals from primary care. *Ann R Coll Surg Engl*. 2006;88(6):543-546.
5. Palmer DH, Hanrahan LP. Social and economic costs of carpal tunnel surgery. *Instr Course Lect*. 1995;44:167-172.
6. Kocher MS. Ghost surgery: the ethical and legal implications of who does the operation. *J Bone Joint Surg Am*. 2002;84(1):148-150.
7. Julliard FA. Surgery of the carpal tunnel reviewed by an expert [in French]. *Chir Main*. 2000;19(5):257-262.
8. Kasdan ML, Vender MI, Lewis K, Stallings SP, Melhorn JM. Carpal tunnel syndrome. Effects of litigation on utilization of health care and physician workload. *J Ky Med Assoc*. 1996;94(7):287-290.
9. Goubier JN, Teboul F, Dubert T. Patient information in carpal tunnel release [in French]. *Chir Main*. 2006;25(6):286-292.
10. Wasiak R, Pransky G. The impact of procedure type, jurisdiction and other factors in workers' compensation on work-disability outcomes following carpal tunnel surgery. *Work*. 2007;28(2):103-110.
11. Katz JN, Amick BC 3rd, Keller R, et al. Determinants of work absence following surgery for carpal tunnel syndrome. *Am J Ind Med*. 2005;47(2):120-130.
12. Chaise F, Bellemere P, Fril JP, Gaisne E, Poirier P, Menadi A. Return-to-work interval and surgery for carpal tunnel syndrome. Results of a prospective series of 233 patients. *J Hand Surg Br*. 2004;29(6):568-570.
13. Bitar G, Alexandrides J, Missirian R, Sotereanos D, Nystrom A. Carpal tunnel release in the United States and Sweden: reimbursement patterns, cost for treatment, and return to work. *Plast Reconstr Surg*. 2002;109(5):1574-1578.
14. Katz JN, Losina E, Amick BC 3rd, Fossel AH, Bessette L, Keller RB. Predictors of outcomes of carpal tunnel release. *Arthritis Rheum*. 2001;44(5):1184-1193.
15. Olney JR, Quenzer DE, Makowsky M. Contested claims in carpal tunnel surgery: outcome study of worker's compensation factors. *Iowa Orthop J*. 1999;19:111-121.
16. Trumble TE, Diao E, Abrams RA, Gilbert-Anderson MM. Single-portal endoscopic carpal tunnel release compared with open release: a prospective randomized trial. *J Bone Joint Surg Am*. 2002;84(7):1107-1115.
17. Kulick MI, Gordillo G, Javid T, Kilgore ES Jr, Newmayer WL 3rd. Long-term analysis of patients having surgical treatment for carpal tunnel syndrome. *J Hand Surg Am*. 1986;11(1):59-66.

18. Plancher KD, Idler RS, Lourie GM, Strickland JW. Recalcitrant carpal tunnel. The hypothenar fat pad flap. *Hand Clin.* 1996;12(2):337-349.
19. Chrysopoulou MT, Greenberg JA, Kleinman WB. The hypothenar fat pad transposition flap: a modified surgical technique. *Tech Hand Up Extrem Surg.* 2006;10(3):150-156.
20. Pülz P, Estermann D, Piza-Katzer H. Surgical treatment of persisting and recurrent carpal tunnel syndrome from 1999 to 2003 [in German]. *Handchir Mikrochir Plast Chir.* 2006;38(5):300-305.
21. Frick A, Baumeister RG. Re-intervention after carpal tunnel release [in German]. *Handchir Mikrochir Plast Chir.* 2006;38(5):312-316.
22. Bagatur AE. Analysis of the causes of failure in carpal tunnel syndrome surgery and the results of reoperation [in Turkish]. *Acta Orthop Traumatol Turc.* 2002;36(4):346-353.
23. Stutz N, Gohritz A, van Schoonhoven J, Lanz U. Revision surgery after carpal tunnel release—analysis of the pathology in 200 cases during a 2 year period. *J Hand Surg Br.* 2006;31(1):68-71.
24. Hunter JM. Recurrent carpal tunnel syndrome, epineural fibrous fixation, and traction neuropathy. *Hand Clin.* 1991;7(3):491-504.
25. Strickland JW, Idler RS, Lourie GM, Plancher KD. The hypothenar fat pad flap for management of recalcitrant carpal tunnel syndrome. *J Hand Surg Am.* 1996;21(5):840-848.
26. Giunta R, Frank U, Lanz U. The hypothenar fat-pad flap for reconstructive repair after scarring of the median nerve at the wrist joint. *Chir Main.* 1998;17(2):107-112.
27. Frank U, Giunta R, Krimmer H, Lanz U. Relocation of the median nerve after scarring along the carpal tunnel with hypothenar fatty tissue flap-plasty [in German]. *Handchir Mikrochir Plast Chir.* 1999;31(5):317-322.
28. Zingale A, Albanese V. Transverse carpal ligament reconstruction with polyesterurethane patch for prevention of recurrence in therapy of failed primary carpal tunnel surgery. *J Neurosurg Sci.* 2003;47(2):111-112.
29. Loick J, Joosten U, Lücke R. Implantation of oxidized, regenerated cellulose for prevention of recurrence in surgical therapy of carpal tunnel syndrome [in German]. *Handchir Mikrochir Plast Chir.* 1997;29(4):209-213.
30. Petersen J, Russell L, Andrus K, MacKinnon M, Silver J, Kliot M. Reduction of extraneural scarring by ADCON-T/N after surgical intervention. *Neurosurgery.* 1996;38(5):976-983.
31. Milward TM, Stott WG, Kleinert HE. The abductor digiti minimi muscle flap. *Hand.* 1977;9(1):82-85.
32. Wilgis EF. Local muscle flaps in the hand. Anatomy as related to reconstructive surgery. *Bull Hosp Joint Dis Orthop Inst.* 1984;44(2):552-557.
33. Dellon AL, Mackinnon SE. The pronator quadratus muscle flap. *J Hand Surg Am.* 1984;9(3):423-427.
34. Rose EH, Norris MS, Kowalski TA, Lucas A, Flegler EJ. Palmaris brevis turnover flap as an adjunct to internal neurolysis of the chronically scarred median nerve in recurrent carpal tunnel syndrome. *J Hand Surg Am.* 1991;16(2):191-201.
35. Wintch K, Helaly P. Free flap of gliding tissue. *J Reconstr Microsurg.* 1986;2(3):143-151.
36. Pizzillo MF, Sotereanos DG, Tomaino MM. Recurrent carpal tunnel syndrome: treatment options. *J South Orthop Assoc.* 1999;8(1):28-36.
37. Varitimidis SE, Vardakas DG, Goebel F, Sotereanos DG. Treatment of recurrent compressive neuropathy of peripheral nerves in the upper extremity with an autologous vein insulator. *J Hand Surg Am.* 2001;26(2):296-302.
38. Varitimidis SE, Fiano F, Vardakas DG, Sotereanos DG. Recurrent compressive neuropathy of the median nerve at the wrist: treatment with autogenous saphenous vein wrapping. *J Hand Surg Br.* 2000;25(3):271-275.
39. Sotereanos DG, Xu J. Vein wrapping for the treatment of recurrent carpal tunnel syndrome. *Tech Hand Up Extrem Surg.* 1997;1(1):35-40.
40. Sotereanos DG, Giannakopoulos PN, Mitsionis GI, Xu J, Herndon JH. Vein-graft wrapping for the treatment of recurrent compression of the median nerve. *Microsurgery.* 1995;16(11):752-756.
41. Tham SK, Ireland DC, Riccio M, Morrison WA. Reverse radial artery fascial flap: a treatment for the chronically scarred median nerve in recurrent carpal tunnel syndrome. *J Hand Surg Am.* 1996;21(5):849-854.
42. Luchetti R, Riccio M, Papini Zorli I, Fairplay T. Protective coverage of the median nerve using fascial, fasciocutaneous or island flaps. *Handchir Mikrochir Plast Chir.* 2006;38(5):317-330.
43. Lanzetta M, Nolli R. Nerve stripping: new treatment for neuromas of the palmar cutaneous branch of the median nerve. *J Hand Surg Br.* 2000;25(2):151-153.
44. Evans GR, Dellon AL. Implantation of the palmar cutaneous branch of the median nerve into the pronator quadratus for treatment of painful neuroma. *J Hand Surg Am.* 1994;19(2):203-206.
45. Meek MF, Coert JH. Clinical use of nerve conduits in peripheral-nerve repair: review of the literature. *J Reconstr Microsurg.* 2002;18(2):97-109.
46. Roure P, Masquelet AC. Anatomical study of the pre-retinacular fat pad of the wrist: application to a new surgical approach to the carpal tunnel [in French]. *Chir Main.* 2001;20(4):287-293.

LETTERS TO THE EDITOR

(Continued from page 168)

AUTHORS' REPLY

We would like to thank Dr. Abendschein for his interest in our paper “Failure of the Vari-Angle Hip Screw System: Two Cases.” We have had extensive experience with the VHS and found that it functioned well for most intertrochanteric fractures. Although it does have the advantage of reducing inventory and precisely adjusting the neck-shaft angle, it is more prominent than other devices, and the senior author has largely stopped using this implant.

We agree that the VHS does not appear to have an overall increased complication rate, but we do feel that it has been less well studied than the classic hip screw devices. The point of our paper was not to review the complex subject of peritrochanteric fractures, but to

point out a unique failure mode for the VHS, namely collapse of the neck-sleeve ratchet mechanism resulting in varus malunion. We postulated that this is more likely to occur in unstable fracture patterns. The precise incidence of this failure mode is not known, as there have been few studies focused specifically on the VHS. Finally, minor degrees of varus collapse may not be easily appreciated and may be associated with a good clinical outcome.

Authors' Disclosure Statement. Drs. Georgiadis and Nowicki report no actual or potential conflict of interest in relation to their article.

Gregory Minas Georgiadis, MD
Toledo, Ohio