

Chronic Elbow Dislocation Treated With Open Reduction and Lateral Ulnar Collateral Ligament Reconstruction

L. Joseph Rubino, MD, Michael A. Herbenick, MD, Ryan P. Finnan, MD, and Philip A. Anloague, PT, DHSc, OCS, MTC

In the United States, chronic unreduced elbow dislocations are rare injuries. We report the successful short-term outcome of a chronic elbow dislocation treated with open reduction and lateral ulnar collateral ligament reconstruction using a split semitendinosus allograft in a figure-of-8 technique without use of hinged external fixation. The authors have obtained the patient's written informed consent for print and electronic publication of the case report.

CASE REPORT

A right-hand-dominant woman in her mid-50s presented to our office complaining of right elbow pain approximately 5 weeks after an isolated right elbow dislocation resulting from a fall off a ladder. On the date of injury, she had undergone closed reduction of the elbow dislocation at an outside facility and been told she required follow-up care with an orthopedic surgeon. The elbow was placed in a sling and not splinted. After discharge from the emergency department, she took her elbow out of the sling only for showering and basic care. She presented to an orthopedic surgeon's office for follow-up, was diagnosed with chronic elbow dislocation, and was referred to our practice for management 5 weeks after injury.

Physical examination revealed significant swelling and tenderness about the right elbow, though these had improved according to the patient. Active range of motion (ROM) was 0° to 75° of flexion, with active assistance increasing flexion to 90°. The right upper extremity was neurovascularly intact, with grip strength equal to that on the contralateral side. The patient did not have a palmaris longus tendon available for graft harvest and decided on an

allograft tendon for reconstruction. Radiographs obtained in our office showed recurrent posterolateral elbow dislocation with a small avulsion fracture (Figure 1). Computed tomography of the right elbow showed that the posterolateral dislocation was associated with a nondisplaced radial head fracture.

After discussion of treatment options, the patient agreed to proceed with surgical intervention. Six weeks after injury, she underwent open reduction of the chronic right elbow dislocation with débridement of the elbow joint, subcutaneous ulnar nerve transposition, repair of the annular ligament, reconstruction of the lateral ulnar collateral ligament (LUCL), and repair of the common extensor origin.

"...given our ability to obtain and maintain a concentric reduction with soft-tissue repair and reconstruction alone, we felt that adding the [hinged external] fixator was not warranted."

Surgery was performed with the patient under general anesthesia and an interscalene block. A tourniquet was used on the upper arm. Medial and lateral skin incisions were used. A medial approach based on the medial epicondyle was made first to identify and protect the medial antebrachial cutaneous and ulnar nerves. A longitudinal split was made in the flexor aponeurosis in line with the anterior portion of the anterior band of the ulnar collateral ligament. No identifiable native ulnar collateral ligament could be identified.

An anterolateral approach to the distal humerus was then made, carried down through the interval between the brachioradialis and triceps, and developed distally to expose the radial head and neck. The common extensor complex had been avulsed from its insertion site on the lateral epicondyle. The radial head was buttonholed through the lateral soft tissues, and there was no lateral ligamentous complex identifiable. A remnant of the annular ligament was developed and tagged for later repair. Abundant hypertrophic scar tissue around the radial head

Dr. Rubino and Dr. Herbenick are Assistant Professors, and Dr. Finnan is Resident, Department of Orthopaedic Surgery, Wright State University-Boonshoft School of Medicine and Miami Valley Hospital, Dayton, Ohio.

Dr. Anloague is Program Director, Doctor of Physical Therapy Program, University of Dayton, Dayton, Ohio.

Address correspondence to: L. Joseph Rubino, MD, Assistant Professor, Department of Orthopaedic Surgery, 30 E Apple St, Suite 2200, Dayton, OH 45409 (tel, 937-208-4507; fax, 937-208-2920, e-mail, ljrubino@mvh.org).

Am J Orthop. 2009;38(6):E98-E100. Copyright, Quadrant HealthCom Inc. 2009. All rights reserved.

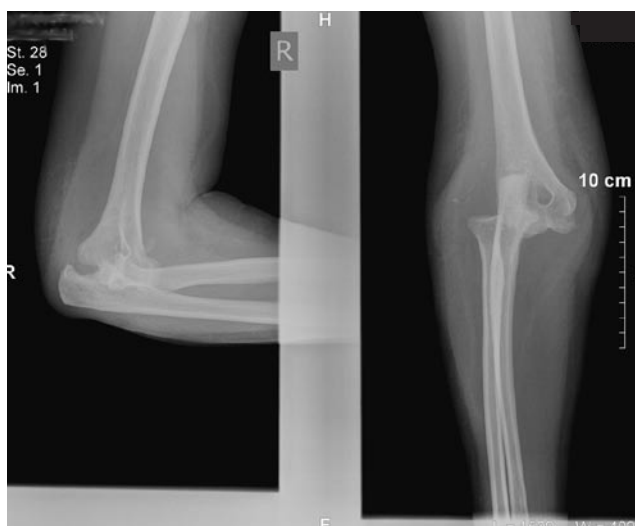


Figure 1. Presenting lateral and anteroposterior radiographs of elbow show chronic posterolateral elbow dislocation with small avulsion fracture.

was excised, revealing moderate articular surface damage. Grade 1 and 2 traumatic articular cartilage changes were noted over the radial head over 30% of the cartilage surface. We exposed the ulnohumeral joint to allow excision of hypertrophic fibrous scar tissue and numerous bony fragments from within the joint. At this point, we were able to reduce the ulnohumeral and radiocapitellar joints under direct visualization, and reduction was confirmed with fluoroscopy. The elbow remained grossly unstable on simple flexion and extension, with spontaneous dislocation occurring approximately 50° short of full extension.

Drill holes (1 anterior, 1 posterior) were made with a 3.5-mm bit. The holes were made approximately 1 cm apart at the LUCL insertion site on the ulna at the crista supinatoris. These drill holes were connected with a small curved curette to create an ulnar tunnel. A 4.5-mm drill hole was then made in the distal humerus at the determined isometric point. Two 3.5-mm drill holes were then made proximally in the distal humerus and connected to the larger, 4.5-mm humeral tunnel. A split semitendinosus allograft was then used to reconstruct the LUCL through drill holes in a figure-of-8 technique. The ligament was manually tensioned in approximately 30° of flexion and full pronation, and No. 2 fiberwire was used to fix the graft to itself both distally and proximally. The annular ligament remnant that had been previously tagged was then imbricated into the collateral ligament reconstruction. Live fluoroscopy confirmed concentric reduction and smooth ROM throughout flexion–extension and rotation. Although we were prepared to apply a hinged external fixator, we felt that this was not required given the concentric reduction and intraoperative stability. The common extensor origin was then repaired back to the lateral epicondyle with 2 suture anchors. The ulnar nerve was then subcutaneously transposed with a fascial sling, and both medial and lateral wounds were closed with a silicone-compound (Silastic;

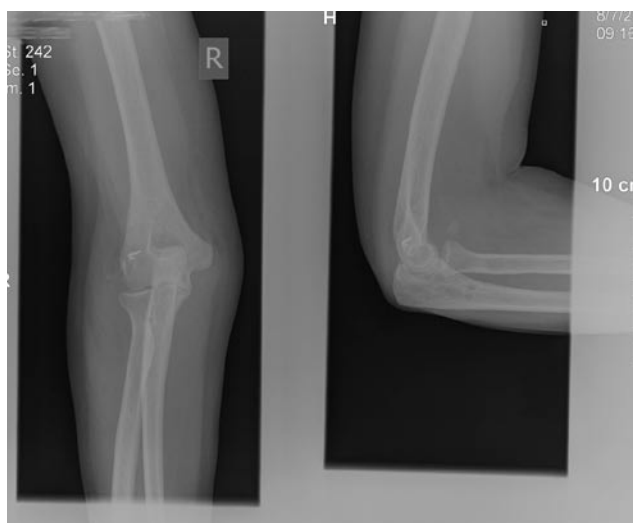


Figure 2. Four-month lateral and anteroposterior radiographs show concentric reduction of radiocapitellar and ulnohumeral joints with slight residual anterior ossification unchanged from original presentation radiographs.

Dow Corning, Midland, Mich) drain on the lateral side. A posterior splint was applied in 70° of flexion.

The patient was observed the night after surgery and discharged from the hospital the next day. Two weeks later, skin staples were removed, and supervised ROM therapy was begun with a hinged elbow brace with a 30° extension block. At 4 weeks, the patient complained of some mild sensory disturbances around the lateral incision. There were no ulnar nerve symptoms distally. Clinical examination revealed full forearm pronation, supination of 80°, and flexion from 30° short of full extension to 125° of flexion. Use of the hinged elbow brace was continued with the extension block removed. At 2 months the hinged elbow brace was discontinued.

At 4 months, the patient was very happy with her outcome. ROM, measured with a handheld goniometer, was averaged over 3 trials. Mean active right elbow ROMs were 150.7° (flexion), 0.67° (hyperextension), 89.7° (pronation), and 90.7° (supination). These results were comparable to those on the noninvolved side (144.7°, 4.3°, 90.3°, and 89.7°, respectively). Grip strength demonstrated a 12.45% overall deficit when tested with handheld dynamometry (Jamar Hand Dynamometer; Sammons Preston, Bolingbrook, Ill), whereas key pinch grip was 4.35% stronger in the involved side. Mathiowetz and colleagues¹ reported mean normative grip strength data for women (age, 55-59) to be 57.3 pounds (right) and 47.3 pounds (left) when using the second handle position of the hand dynamometer. Our patient demonstrated grip strength of 45.79 pounds (right) and 51.4 pounds (left), indicating a 20% deficit compared with norms for the right hand. Isometric dynamometry was used to test elbow flexion and extension at 45°. Peak torque elbow extension demonstrated a 9.8% deficit when compared with the contralateral side; in flexion, the deficit was only 4.6%.

At 4 months, radiographs showed concentric reduction of the radiocapitellar and ulnohumeral joints with slight residual anterior ossification unchanged from original presentation radiographs (Figure 2). The patient was released to full activity.

DISCUSSION

Unreduced elbow dislocations, both subacute and chronic, are rare in the United States. Recurrent subluxation and complex instability are more commonly encountered.² We report the case and short-term outcome of a chronic elbow dislocation successfully treated with open reduction and soft-tissue repair and reconstruction without use of hinged external fixation.

Most reports on treatment of chronic elbow dislocations come from developing countries in Asia and Africa. Intermediate- to long-term results of 24 patients treated with open reduction for chronically dislocated elbows are available from Thailand.³ Patients were treated a mean of 7.9 months from time of injury, and satisfactory postoperative ROMs were achieved with no correlation between time to surgery or preoperative ROM. Naidoo⁴ reported a case series of 21 patients who underwent open reduction late, 1 month to 2 years from time of injury. Transarticular Kirschner-wire fixation was used to help maintain reduction for 2 weeks after surgery. Although follow-up was erratic (range, 4 days to 2.5 years from Kirschner-wire removal), 23 of 25 patients obtained a satisfactory outcome, and patient age seemed not to correlate with outcome. Di Schino and colleagues⁵ reported that open reduction was successful in 72% of 52 cases; complete resection of the elbow was even more successful (80%), but the authors preferred reduction given the weakness and instability associated with resection.

The more contemporary literature favors use of hinged external fixators to maintain reduction while allowing the early motion that is critical to achieving a satisfactory outcome. Morrey² recommended a defined surgical sequence culminating in hinged fixator application to address the complex pathology associated with chronic dislocated elbows.

Jupiter and Ring⁶ described 5 unreduced simple elbow dislocations surgically treated a mean of 11 weeks after injury. Four of the 5 elbows were approached through a single posterior skin incision with separate medial and lateral joint exposures. Similar to our experience, they were unable to isolate any structure resembling a collateral ligament. They did not perform specific lateral ligament reconstruction but instead reattached the lateral soft-tissue

envelope with suture anchors or through drill holes in 3 of the patients. Hinged external fixators were used in all 5 patients for 4 to 6 weeks, with passive motion begun on postoperative day 1. At follow-up (range, 12-98 months), reduction had been maintained in all 5 patients radiographically, mean arc of flexion was 123°, all patients had full forearm rotation, and Mayo Elbow Performance Index scores were excellent (2 patients) or good (3 patients).

Successful and appropriate use of hinged elbow fixators in the setting of elbow fracture-dislocations is well documented in the literature, as are the associated complications and technical difficulties in their application.⁷⁻¹⁰ The benefit of the hinged external fixator is relatively obvious in its use for chronic elbow dislocations. When an open procedure is used to obtain a concentric reduction, the articulating fixator can maintain that reduction while allowing motion. We were prepared to apply the fixator in our patient's case, and she had been exhaustively counseled that she might require one. However, given our ability to obtain and maintain a concentric reduction with soft-tissue repair and reconstruction alone, we felt that adding the fixator was not warranted.

This case illustrates successful use of anatomical soft-tissue repair and reconstruction in the setting of chronic elbow dislocation without use of a hinged external fixator.

AUTHORS' DISCLOSURE STATEMENT

The authors report no actual or potential conflict of interest in relation to this article.

REFERENCES

1. Mathiowetz V, Kashman N, Volland G, Weber K, Dowe M, Rogers S. Grip and pinch strength: normative data for adults. *Arch Phys Med Rehabil*. 1985;66(2):69-74.
2. Morrey BF. Chronic unreduced elbow dislocation. In: Morrey BF, ed. *The Elbow and Its Disorders*. 3rd ed. Philadelphia, PA: Saunders; 2000:431-436.
3. Mahaisavariya B, Laupattarakasem W. Neglected dislocation of the elbow. *Clin Orthop*. 2005;(431):21-25.
4. Naidoo KS. Unreduced posterior dislocations of the elbow. *J Bone Joint Surg Br*. 1982;64(5):603-606.
5. Di Schino M, Breda Y, Grimaldi FM, Lorthioir JM, Merrien Y. Surgical treatment of neglected elbow dislocations. Report of 81 cases [in French]. *Rev Chir Orthop Reparatrice Appar Mot*. 1990;76(5):303-310.
6. Jupiter JB, Ring D. Treatment of unreduced elbow dislocation with hinged external fixation. *J Bone Joint Surg Am*. 2002;84(9):1630-1635.
7. Ring D, Jupiter JB. Compass hinge fixator for acute and chronic instability of the elbow. *Oper Orthop Traumatol*. 2005;17(2):143-157.
8. Ruch DS, Triepel CR. Hinged elbow fixation for recurrent instability following fracture dislocation. *Injury*. 2001;32(suppl 4):SD70-SD78.
9. Ring D, Hannouche D, Jupiter JB. Surgical treatment of persistent dislocation or subluxation of the ulnohumeral joint after fracture-dislocation of the elbow. *J Hand Surg Am*. 2004;29(3):470-480.
10. Paksima N, Panchal A. Elbow fracture-dislocations: the role of hinged external fixation. *Bull Hosp Jt Dis*. 2004;62(1-2):33-39.